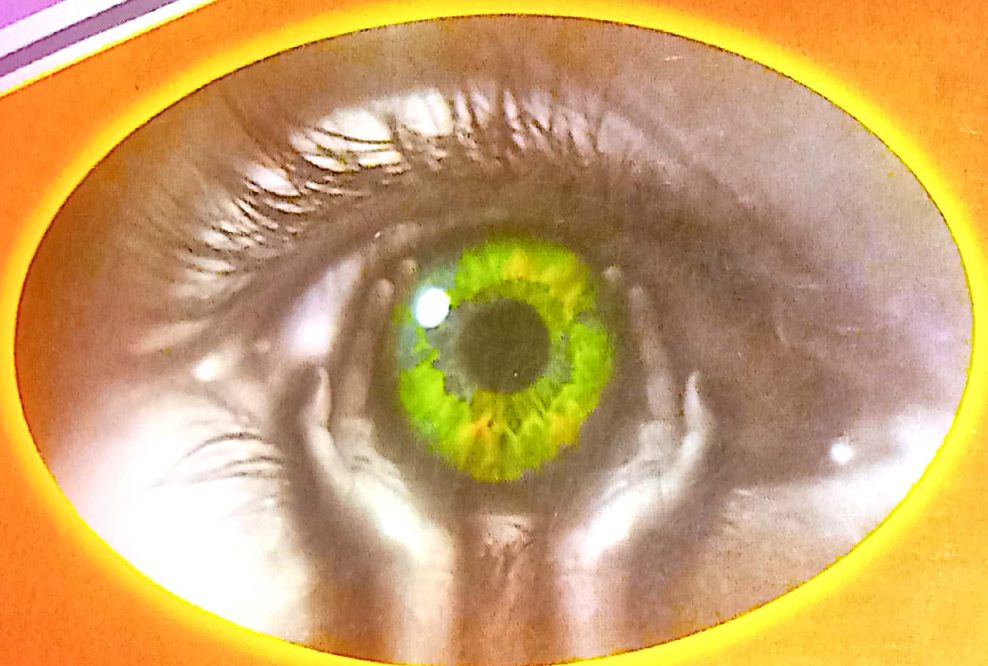

TEXT BOOK OF SHALAKYA TANTRA

As Per Revised C.C.I.M. Syllabus

Professor Suja K Sreedhar

PART-I (NETRA VIGNYANA)



CHAUKHAMBHA ORIENTALIA, VARANASI

Ayurveda Ek Vikalp Foundation

- ◆ **All ayurvedic books store**
- ◆ **India's biggest Ayurveda union.**
- ◆ **For Ayurvedic E- book follow,
subscribe us on**

Telegram-

<https://t.me/ayurvedaekvikalpfoundation>

Facebook-

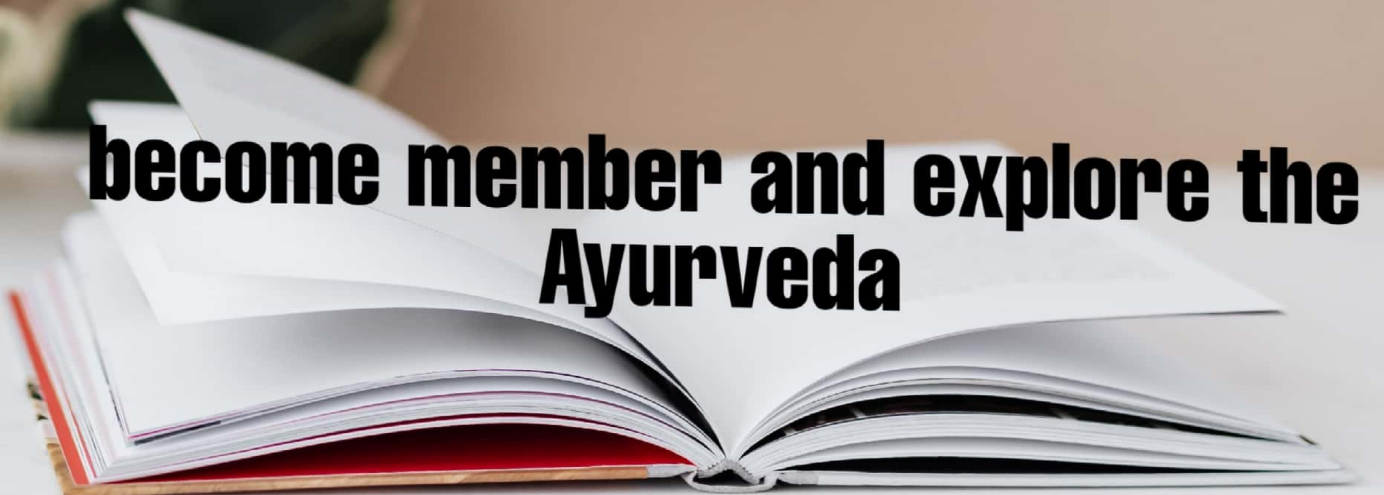
<https://m.facebook.com/ayurvedaekvikalp/?ref=bookmarks>

E-mail- ayurvedaekvikalp@gmail.com

Website- ayurvedaekvikalp.org

**For WhatsApp group msg-
9561788826**

**become member and explore the
Ayurveda**



ACKNOWLEDGEMENT

My Sincere Gratitude And Thanks To My Dear Students Without Whom
This Book Would Not Have Been A Reality.....

Dr. Akshatha K.	Dr. Sahana Shetty S.
Dr. Rashmi Suvarna	Dr. Chetana G. Sunkud
Dr. Suchitra Chawan	Dr. Shwetha Koutal
Dr. Gururaj N.	Dr. Champavathi P.
Dr. Ganesh Tejasvi S.	DR. Vidyalakshmi T.
Dr. Ratnawwa Nayik	Dr. Shweta G. R.

CONTENTS

NETRA ROGA VIGYAN

Chapter-1	
Introduction	
A. Shālakyatantra Nirukti, Parichayam, Itihasam	2
B. Netra Rachana Shariram (Mandala, Patala, Sandhi, Drushti Vichara) and Netra Kriya Sharira along with Modern anatomy of eye.	8
C. Eye examination and knowledge of basic instruments/equipments required for examination of eye.	23
D. Netraroganam- Samanya Hetu (Nija and agantuja), Purvarupa, Samprapti, Rupa and Chikitsa.	34
E. Classification of Netraroga and its importance.	40

Chapter-2	
Netra Samanya and Vishishta Chikitsa- Kriya Kalpa	
A. Netra swasthya hitakara Dinacharya, Ritucharya, Aahara evam Vihara.	49
B. Kriya kalpa-Seka, Aschotana, Pindi, Bidālaka, Tarpana, Putapāka, Anjana and importance of Panchakarma in Netra Chikitsa.	53
C. Basic fundamentals of Netra Shastra Chikitsa e.g. Purva- Pradhana- Paschat karma, Ama-Pachyamana-Pakva Vrana shotha, Vranitopāsana, Pranashtashalya & Vranabandhana. Methods and concepts of sterilization, asepsis and antisepsis as per ancient and modern point of view.	73
D. Basic applied knowledge of Ashtavidha shastrakarma, Agni, Kshara, Raktamokshana in Netra rogas.	79
E. Essential diagnostic and therapeutic modern pharmacological agents required in Netra Chikitsa.	87

(vi)

Chapter-3	
Sandhigata Roga (Diseases of Junctional areas of eye)	
A. Number of sandhigata rogas, detailed etiology, pathology, clinical features and management of Pooyalasa and Srāva Rogas.	93
B. Brief Study of krimi granthi, Parvani and Alaji Rogas.	102
C. Study of Acute and Chronic Dacryocystitis, Epiphora, Blepharitis including their aetiology, pathology, signs & symptoms, differential diagnosis, medical & surgical management.	106

Chapter-4	
Vartmagata Roga (Diseases of Lids)	
A. Number of Vartmagata rogas, and detailed knowledge of etiology, pathology, clinical features and management of Anjananāmika, Uṣangini, Lagana, Vātahata vartma, Pakshma kōpa, Sikata vartma, Pōthaki, Klinna vartma, Krichronameelana and Kukunaka diseases of Vartma.	119
B. Brief Knowledge of Vartmarbuda, Utklishta vartma, Nimesha, Pakshmathāta, Vartmarsha.	142
C. Knowledge of Hordeolum, Ptosis, Trachoma, Trichiasis, Entropion, Ectropion including their etiology, signs and symptoms, differential diagnosis, medical & surgical management.	148

Chapter-5	
Shuklagata Roga (Diseases of Sclera and Conjunctiva)	
A. Number of Shuklagata rogas, detailed knowledge of etiology, pathology, clinical features and management of Arma, Arjuna and Shuktika.	162
B. Brief Knowledge of Sira pidika, Sira jāla, Pishtaka, Balāsgrathita.	173
C. Study of Pterygium, Scleritis, Episcleritis, Sub-conjunctival hemorrhage including their etiology, signs and symptoms, differential diagnosis, medical & surgical management.	177

(vii)

Chapter-6	
Krishnagata Roga (Diseases of Cornea and Uvea)	
A. Number of krishnagata rogas, detailed knowledge of etiology, pathology, clinical features, differential diagnosis, complications and management of Savrana/kshata Shukla (Shukra), Avraṇa Shukra (Shukla).	185
B. Brief knowledge of Sirā shukla, Akshipākaiyaya and Ajakajāta.	191
C. Knowledge of Corneal ulcer, Corneal Opacity, Uveitis, Acute Iridocyclitis, Staphyloma, their etiology, pathology, symptoms, differential diagnosis, complications and management.	194

Chapter-7	
Sarvagata Roga (Diseases affecting all parts of eye)	
A. Number of Sarvagata rogas, detailed knowledge of etiology, pathology, clinical features, complications, differential diagnosis and management of Abhishyanda, Adhimantha, Hatādhimantha and Shushkākshipaka.	204
B. Brief Knowledge of Amloshita, Vāta paryaya, Anyato vāta, Sashopha & Ashophakshipaka, Pilla roga, Sirotpata and Sirāharsha.	223
C. Knowledge of Conjunctivitis, Glaucoma, Dry Eye Syndrome including their etiology, pathology, clinical features, differential diagnosis, complications and their management.	231

Chapter-8	
Drushtigata Roga (Vision disorders)	
A. Number of Drushtigata rogas detailed knowledge of-etiology, pathology, clinical features, differential diagnosis and management of Timira, Kācha and Linga nāsha.	253
B. Brief Knowledge of Abhigataja linga nāsha, Sanimittaja & Animittaja Linga nāsha, Doshandhya/Kaphavidagdha drushti, Naktandhya, Ushna vidagdha drushti, Pittavidagdha drushti, Dhumadarshi, Hriswajādyā, Gambhīrika, Nakulāndhya, Nayanābhighata.	271
C. Knowledge of Refractive errors, Cataract including their etiology, pathology, clinical features, differential diagnosis, complications and their management.	283
D. Study of Eale's disease, Hypertensive & Diabetic Retinopathies, Age related macular degeneration, Strabismus, Retinitis pigmentosa, Night blindness, Amblyopia, Central serous retinopathy, Optic neuritis and Optic atrophy.	296

(viii)

Chapter-9	
Miscellaneous Diseases	
A. Xerophthalmia and other Malnutritional eye disorders	313
B. Knowledge of Ocular trauma and their management	317
C. Introduction to Eye bank, Eye donation, Corneal Transplantation	323
D. Preventive Ophthalmology and Community Ophthalmology	326
Chapter-10	
Yantras and Shastras	331
Bibliography	351

Chapter-1

INTRODUCTION

A. Shālākyatantra Nirukti, Parichayam, Itihāsam.
B. Netra rachana shariram (Mandala, Patala, Sandhi, Drushti Vichāra) and Netra Kriya Shāreera along with Modern anatomy of eye.
C. Eye examination and knowledge of Basic instruments/equipments required for examination of eye.
D. Netraroganam- Samanya Hetu (Nija and Agantuja), Purvarupa, Samprapti, Rupa and Chikitsa.
E. Classification of Netraroga and its importance.

Chapter

1A

- Shālākya Tantra Nirukti and Parichaya
- Synonyms & Importance of Shālākya Tantra
- Itihāsa & Contributors of Shālākya Tantra

Ayurveda is a science of life, being practiced since thousands of years. It consists of eight branches. Shalākya Tantra is one among them. Shalākya tantra deals with the diseases occurring in the organs situated above the neck. Its importance is ascertained by the fact that the main marma- Shiras and the sense organs like eyes, ears, nose are present in this part of the body.

SHĀLĀKYA TANTRA NIRUKTI AND PARICHAYA

Shālākya and Tantra are the two words in Shālākya Tantra. Shālākya is derived from the word "Shalākā"-a probe, and "Tantra" denotes teachings and practices found in the scriptures.

Dalhana-the commentator of Sushruta samhita has given the following definition

शालाकायाः कर्म शालाक्यं, तदाधानं तन्त्रमपि शालाक्यम् ।

Wherever Shalākā or probe is used in the treatment of diseases is called Shālākya and the science dealing with it is called Shālākya Tantra.

Synonyms of Shālākya Tantra: Uttamānga chikitsā, Jatrurdhwa chikitsā, Urdhwānga chikitsā, Shālākya chikitsā.

शालाक्यं नाम ऊर्ध्वजत्रुगतानां श्रवणं नयनं वदनं प्राणादि संश्रितानां व्याधीनामुपशमनार्थम् । [S.Su. 1/7 (2)]

The branch of science which deals with the treatment of diseases occurring in the organs situated above the neck such as eye, ear, nose, oral cavity etc is known as Shālākya tantra.

According to Dalhana, the word आदि in the above shloka indicates all the other diseases occurring in the shiras and kapāla.

Vāgbhata, while classifying Ashtāṅgās of Ayurveda has used the word "Urdhwānga" instead of Shālākya.

Arunadatta, the commentator of Ashtanga Hridaya, while describing the Urdhwānga chikitsa has mentioned the diseases of eye, ear, nose etc. with their treatments.

Importance of Shālākya Tantra

प्राणाः प्राणभृतां यत्राश्रिताः सर्वेन्द्रियाणि च । यदुत्तमंगमंगानां शिरस्तदभिधीयते ॥ [C.Su. 17/12]

'Life' of the living beings and all the Indriyas are situated in the head, hence it is known as Uttamānga. The treatment given to this part of the body is described specially in Shālākya Tantra. While describing the importance of shiras, Vāgbhata co-relates it to the root of tree (Urdhwa moola) and body to the trunk of tree (Adha shāka).

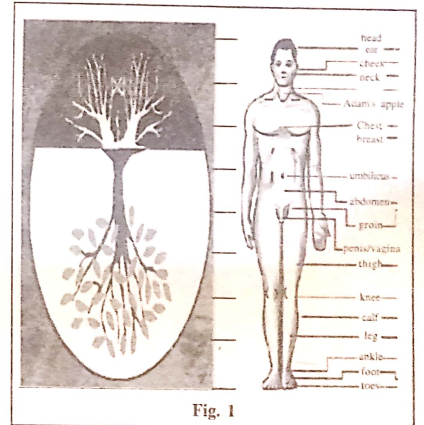
Sushruta has dealt with Mukha Roga in Nidāna Sthāna and its treatments in Chikitsā Sthāna. The description regarding the diseases of eye, ear, nose and head are found only in Uttara Sthāna.

Sushruta specially describes the diseases of Shālākya Tantra as told by Vidēha in the beginning of Uttara Tantra itself.

The mention of netra and related diseases are found in the Aupadravika Adhyāya which is the first chapter of Uttara Tantra of Sushruta samhita. In the following chapters, a detailed description regarding

the diseases and treatment of netra, karna, nasa and shiras, surgical procedures like lekhaṇa, chedana, bhedana and special therapies like kriyā kalpās are mentioned.

Thus the above references described in our texts show the importance given to Shalākya disorders and its management.



SHĀLĀKYA TANTRA ITIHĀSA

Scattered information regarding Shālākya Tantra is found in the Ancient literatures.

Vedic period references

- Nahush was treated for deafness by Ashwini kumaras. (Rigveda)
- Rujaswa and Kanva were treated for blindness by Ashwini Kumaras. (Rigveda)
- There are several prayers mentioned for normal functioning of sense organs. (Yajurveda)
- Structure and functions of Mastishka are described. (Atharva)
- Mantras or hymns having reference to diseases of Eye, Ear, Oral cavity etc are found. (Atharva veda)

Upanishad Period references

- Eyes are located in two of the seven cavities of the skull.
Parts of the eye like urdhwa and adhara vartma, shuklam, lohinam and krishnam are described (Brhadāranyaka upanishad).
- Internal features and reflections of eye like shuklābha, nīlābha and krishnābha are described. (Chāndogya upanishad).

Samhitā period references

a. Sushruta Samhita

- Explanation regarding netra, karna, nasa and shirorogas. (Uttara tantra: 1-26th chapter).
- Details regarding mukha and kanta roga nidana and chikitsa (Nidāna sthāna 16th & Chikitsā sthāna 22nd chapter).
- Description regarding karna chedana, bandhana, sandhāna, nāsa-oshta sandhāna etc. (Sutra sthana 16th chapter).

b. Charaka Samhita

- Explanation regarding Shiroroga (Sutra sthāna 17th chapter).
- Explanation of Gala rogās like upajihvika, galaṣhundi and rohini. (Sutra sthāna 18th chapter).
- Nasa, shiro, mukha, karna and netra chikitsa (Chikitsa sthāna 26th chapter).
- Description regarding lakshana and chikitsa of shankhaka, ardhāvabhedaka, anantavāta, shirōvirechana and shirobasti. (Siddhi sthāna 9th chapter.)

c. Ashtanga Sangraha

- Detailed description regarding Shālākya Tantra. (Uttara tantra 1-28 chapters).
- Description of Kriyākālpās (A. S. Su. 32nd and 33rd chapters).

d. Ashtānga Hṛudaya

- Detailed description on Shālākya Tantra. (Uttara tantra 8-24 chapters).
- Kriyākālpās (Sutrasthāna 23rd and 24th chapters).

e. Bhela Samhita

- Chakṣhurvaisheshika and Buddhirvaisheshika Alochaka pitta.

Medieval Period References

Mādhava Nidāna, Shārangadhara Samhita, Bhāvaprakāsha, Chakradatta, Yogaratnākara, Vangasena, Gadanigraha, Hārta Samhita, Bhaishajya Ratnāvali are some of the scholarly books on Shālākya Tantra during this period.

Contributors of Shālākya Tantra

Several sages of ancient age have contributed to Shālākya Tantra namely Nimi, Kānkāyana, Sātyaki, Chakshushyena, Gārgya, Gālava etc.

1. Nimi:

Nimi is considered as the "Father of Shālākya Tantra". There are controversies regarding his name and personality. According to some, Nimi, Videha and Janaka are different, but majority accept them as one. Nimi is considered as son of King Ikshvāku (Shrimad Bhagawad-9th skanda/13th chapter).

Mythological stories

- 1) Janaka, the wealthy king of Videha once started a vedic ritual-Aalambha yagnya which was attended by brahmins. On seeing this yagnya being conducted, the Sun God became angry and cursed him to become blind. Upset over this incident, the king Janaka did rigorous penance to please the Sun God. Pleased by the penance, the Sun God blessed Janaka and taught him "Chakshurvēda"-the science for the welfare of the sight of mankind. (Dālhana commentary)
- 2) The King of Videha- Nimi, once proposed to conduct a yagnya. He approached his guru Vasishta to perform the ritual. Due to his previous commitment with Indra, the guru asked Nimi to postpone the yagnya till he returns. But Nimi started the yagnya even before the return of Sage Vashishta. Angered by this,

Vasishta cursed Nimi to death. The Devatas who were pleased by Nimi's yagna, wanted to bring him back to life, for which Nimi himself refused. Hence, he was blessed to stay in the eyelids of the people thereafter. The word 'Nimesha' is derived from Nimi depicting the opening and closing of eyelids.

Different names of Nimi

Nimi: For staying in eyelids of human beings.

Videha: Since he remained without body after the curse, he was called Vi-deha.

Vaideha: King of Videha.

Mithi: His dead body had undergone 'manthana' hence named as Mithi.

Janaka: For taking rebirth he is called as Janaka.

Period of Nimi

The exact time and period of Nimi cannot be fixed due to differences of opinion. Some references available are :

1. Nimi attended a conference along with Indra, Ātreya Punarvasu, Dhanvantari, Kāshyapa, Alambhāyana etc (A.S.Su.).
2. Nimi, Vāyorvidha, Kānkāyana and others held discussion (Ka.Su.).
3. In another context Nimi, Ātreya, Bhadrakāpya, Kānkāyana attended a conference in Chaitrarathavana.

From the above references it can be inferred that Nimi, Atreya and Punarvasu lived in the same period

4. He lived approximately 200 years before Mahabharatha war (Boudha Jātaka Tales).
5. Nimi lost his body by the curse of Sage Vasishta. This shows Nimi and Vasishta lived in the same period.

References to show that Nimi, Videha and Janaka are different

1. Nimi is the king of Videha, Mithi is Nimi's son and Janaka is Mithi's son. (Ramayana and Puranas).
2. Karāla Janaka is the son of Nimi (Bouddhagrantha).

References to show that Nimi, Videha and Janaka are one and the same

- i. Nimi is considered as King of Videha. (C. Su. 26)
- ii. Janaka is also considered as King of Videha. (C. Sh. 6)

2. Kankāyana

- No Shālākya related text is available in his name.
- He took part in the symposium held during the time of Charaka.
- He was one among the best physicians of Bāhlika.
- Kankāyana vati is used in the digestive disorders and piles. It is a drug formulation credited to Kankāyana (History of Indian medicine).

3. Karāla

- Nimi is considered as Guru of Karāla (A. S. Su.)
- He has mentioned 96 diseases of eyes (Chakrapāni)

4. Satyaki

- His name is mentioned many times in Mahābhāratha and considered as brother of Lord Krishna and friend of Arjuna.
- He is a renowned physician of Shālākya Tantra and authored the book "Sātyaki Tantra".
- He has mentioned 80 diseases of eye (Chakrapāni).
- His name is famous as he introduced a "couching" method for treating cataract.

5. Gārgya

- He was one of the participants in the conference held in the Himālayās.
- He is said to have authored books on Vāstu Shāstra and Shālākya Tantra.
- Pānini- the vyākaraṇakāra describes about Gārgya in his work. So, it can be predicted that Gārgya lived before Pānini.

6. Gālava

- He attended the conference held in the Himālayās.
- Gālava is considered as disciple of Lord Dhanvantari (Dalhana).
- In Mahābhārata Shānti parva, Gālava is being told as an expert in Rigveda teaching method. He has also written books on education and grammar.

7. Chakshushyena

- He was an expert eye surgeon who wrote Chakshushyena Tantra.

8. Bhoja

- Bhoja was well-versed in Shalākya Tantra even though he was expert in Shalya Tantra.
- The name of the book written by him is "Bhoja Samhita/Bhoja Prabandha".

Chapter

1B

- Derivation & Synonyms of Netra
- Utpatti and Panchaboutikavta of Netra
- Netra Pramāna & Akṛuthi
- Mandala, Sandhi, Patala of Netra
- Netra Bandhana
- Netra Marma

NETRA RACHANA SHĀREERA

Netra is the chakshurendriya adhiṣṭana meant for the perception of vision.

Derivation Of 'Netra'

नेत्र- नीयते नयति वा अनेन इति चक्षुः ।

The word Netra is derived from the root "Ni" which means to guide or to lead. Netra means chakshu or visual sensory faculty which is guiding in nature.

Synonyms of Netra

The synonyms of Netra are Lochanam, Nayanam, Netram, Ikshanam, Akshi, Druk, Drushtihi, Darshanam, Tapanam, Vilochanam, Drusha, Vikshanam, Prekshanam, Devadeepa.

Utpatti of Netra

कफ रक्तवाहिनां स्रोतसां महाभूतानां च प्रसादात् इन्द्रियाणि ।।

तेष्वपि च नेत्रे श्लेष्मणः प्रसादात् शुक्लमण्डलम् तत् पितृजम् ।

असृजः कृष्ण मण्डलम् तत् मातृजम् । मध्ये दृष्टि मण्डलम् तत् उभयात्मकम् ।। (A. S. Sh. 5/48-49).

Indriyas are the essence formed by the action of bhutaagni on kaphavaha and raktavaha srotas.

Shukla mandala and Krishna mandala are formed by kapha and raktavaha srotas respectively.

Shukla mandala is pitruja and Krishna mandala is mātruja bhāva and drushti mandala is formed by both matruja and pitruja bhāvās.

Introduction

9

Panchaboutikavta of Netra

पलं भुवोऽग्निनो रक्तं वातात् कृष्णं सितं जलात् । आकाशादशुभ्रमर्गाश्च जायन्ते नेत्रबुद्धे । (S. U. 1/11-12)

S.N.	Netra bhāga	Mahabhūta	Part of the eye
1.	Pala (Mamsa)	Pruthvi	Muscular part
2.	Rakta	Teja	Vascular part
3.	Krishna	Vayu	Black portion (Cornea)
4.	Sita	Jala	White portion (Sclera)
5.	Asu marga	Akāsha	Tear channels

NETRA PRAMĀNA (Measurements of eye)

विद्यात् द्वयङ्गुल बाहुल्यं स्व अङ्गुष्ठोदर समितम् । द्व्यङ्गुलं सर्वतः सार्धं भिषक् नयनबुद्धम् । (S.U. 1/10)

1. Bahulya (anteroposterior diameter) = 2 angula.
2. Āyāma-Vistara (from above downwards) = 2 angula.
(from side to side) = 2 1/2 angula.
3. Sarvataha (Circumference) = 3 1/2 angula.

Note: There is a controversy regarding āyāma and vistāra of netra.

According to some, it is the circumference of the eyeball and some say it is the distance between kaneenika and apānga.

Pramāna of Krishna mandala

1. नेत्रायाम त्रिभागं तु कृष्णमण्डलमुच्यते । (S.Ut. 1/13)

It is 1/3rd of Netra āyāma.

2. It is dwi yava pramāna i.e size of 2 barley seeds (Dalhana).
3. तत्र शुक्लात् तृतीयांशं कृष्णम् । (A.S.Sh.8/36)

It is 1/3rd of Shukla mandala

Pramāna of Drushti mandala

1. कृष्णात् सप्तममिच्छन्ति दृष्टिं दृष्टिविशारदाः । (S.U.1/13)

It is 1/7th of Krishna mandala.

2. नयनत्रिभागपरिणाहा तारका नवमस्तारकांशो दृष्टिः । (S.Su. 35/12)

3 S.T.-I

It is 1/9th of krishnamandala.

3. मसूरदलमात्रं तु (S.U.7/3)

It is size of masura seed.

Patala pramāna:

पञ्चमांशसमं दृष्टेस्तेषां बाहुल्यमिष्यते । (S.U.1/19)

The thickness of patala is 1/5th of drushti pramana.

Space between two eyes

अक्षिमध्यम् चतुरंगुलम् । (C.Vi. 8/117)

The distance between two eyes is four ngulas.

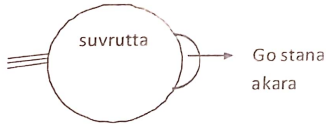
AKRUTHI (Shape) OF NETRA

The description of eye ball is beautifully explained in Ayurveda.

सुवृत्तं गोस्तनाकारं सर्वभूतगुणोद्भवम् । (S.U.1/11)

Suvrutam = Round/Spherical. Gostanākāra = Tout of cow/Grape fruit.

The shape of Netra is round or spherical resembling tout of cow or grape fruit



NETRA BHĀGA (Parts of the eye)

Achāryas have classified and described the anatomical parts of Netra as Mandala, Sandhi and Patala.

मण्डलानि च सन्ध्यांश्च पटलानि च लोचने। यथाक्रमं विजानीयात् पञ्च षट् च षडेव च॥ (S. U. 1/14)

- Mandala -5 in number (circular visible parts of the eye).
- Sandhi-6 in number (junctions between mandalas).
- Patala-6 in number (tunics/layers of eye).

NETRA MANDALAS

The mandalas are externally circular visible parts of the eye with unique characteristics. They are anatomically arranged in concentric circles from periphery to centre as - Pakshma, Vartma, Shukla, Krishna and Drushti.

पक्ष्म वर्त श्वेत कृष्ण दृष्टीनां मण्डलानि तु । अनुपूर्वं तु ते मध्याश्रित्वारोऽन्या यथोत्तरम् ॥ (S.U.1/15)

(i) Pakshma Mandala

Pakshma means eye lashes and are situated in lid margins of the eye. The root of each pakshma is situated in a cavity called pakshmakooopa from where it gets nourishment. They are arranged in two to three rows and are externally curved. The lashes are slightly more numerous in the upper than in the lower lid.

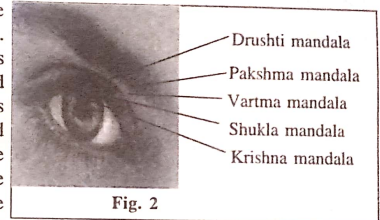


Fig. 2

Pakshma can be considered as kesha which is the mala of asthi and has predominance of vayu mahabhuta.

(ii) Vartma Mandala

Vartmas are the eyelids which covers the eye ball. They are two in number- upper and lower. The two lids meet together laterally in apanga sandhi and medially in kaneenika sandhi.

Panchabhoutikatva and doshas of Vartma

Vartma mandala is highly vascularised muscular structure. This shows the predominance of Agni and Pruthvi mahabhuta. So the sthanika doshas are Pitta and Kapha.

Functions of Vartma mandala

Vāta: The function of opening and closing of the eyelids is carried out by vyāna vāyu and the main seat of vyāna vāyu is Hridaya. So, in the diseases where vyāna vāyu is involved the functions of vartma will also be impaired Eg. Sarvānga vāta.

Prānavāyu, though situated in the mūrdha, controls the functions of the indriyās. It has an indirect action on the lids also. Diseases confined to the head region in which prānavāyu is involved manifest signs and symptoms in vartma also Eg: Ardita.

Pitta: Rakta dhātu is the nutritional factor in vartma. Thereby pitta being directly linked to rakta dhatu also helps in nourishing vartma.

The sara and drava properties of pitta helps in moistening the eye ball through lacrimal secretion and this gives luster and protection to the eyes.

Kapha: The structural stability of vartma is maintained by kapha. It protects the eyeball from trauma and foreign particles such as dust, smoke etc. When kapha is decreased in vartma, vāta gets vitiated causing disturbance in its function. Hence kapha is useful in maintaining the function of vāta.

(iii) Shukla Mandala (Sita mandala, Shweta mandala)

Shukla mandala is the visible white portion of the eye comprising of conjunctiva and sclera. The visible area is about 25 mm long and 15 mm wide. The boundaries of shukla mandala consists of 4 netra sandhis (i) vartma shukla (ii) shukla krishna (iii) kaneenika (iv) apānga sandhi.

Panchabhoutikatva and doshas of Shukla mandala

The Sthanika dosha of Shukla mandala is kapha because of the predominance of the jalamahābhūta and pitta is the anubandha dosha due to the presence of blood vessels signifying agni mahābhūta.

Nutrition to the Shukla mandala

Rasa and rakta dhatus provide nutrition to the shukla mandala (through the vascular coat) and vartma mandala.

Functions of Shukla mandala

The shape and stability of the eye ball is maintained by the sthira, snigdha and guru properties of kapha.

(iv) Krishna Mandala (Asita mandala)

Krishna mandala is the central 1/3rd part of the visible portion of the eye ball. This appears black in color but is purely transparent. Krishna mandala gets its color because of the underlying pigmented structure- Iris.

Panchabhoutikatva and doshas of Krishna mandala

Vāyu mahābhūta is predominant in Krishna mandala because of its contact with atmospheric air, property of transparency and function of attracting light rays into eyeball.

Nutrition to the Krishna mandala

Transparent nature of the cornea is due to avascularity. It gets its nutrition directly from the atmospheric air through tear film and aqueous humor. Aqueous humor is considered to be a derivative of rasa dhatu.

Functions of Krishna mandala

The transparency of krishna mandala maintained by the vāta dosha and vāyu mahābhūta helps in the conduction and convergence of the rays on the photosensitive portion of the eye (retina).

(v) Drushti Mandala

Drushti is the functional unit which actually does perception of vision.

Drushti can also be understood in four different ways:

- Drushti mandala- Pupil
- Drushti mani - Lens
- Drushti- Retina
- Drushti- Vision

Drushti mandala is 1/7th or 1/9th of the krishnamandala and is situated in its centre. This area is circular in shape and is about 2-4 mm diameter. This constricts in the presence of bright light and dilates in the absence of light.

Panchabhoutikatva and doshas of Drushti mandala

Drushti is panchabhoutika with predominance of Tejo mahābhūta and it has all the Tridoshas.

NETRA SANDHI

Netra sandhis are the junctional areas. They are 6 in number, out of which four are placed in between the mandalas and two at the periphery.

पक्षमवर्तगतः सन्धिवर्त्मशुक्लगतोऽपरः । शुक्लकृष्णगतस्त्वन्यः कृष्णदृष्टिगतोऽपरः ॥
ततः कनीनकगतः षष्ठश्चापाङ्गयः स्मृतः ॥ (S.U.1/16)

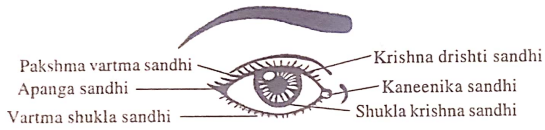


Fig. 3

The 6 sandhis are-

1. Pakshma vartmagata sandhi
2. Vartma shuklagata sandhi
3. Shukla krishnagata sandhi
4. Krishna drushtigata sandhi
5. Kaneenika sandhi
6. Apanga sandhi.

1. Pakshma vartmagata sandhi

It is the junction between the pakshma mandala and vartma mandala. It can be considered as lid margin.

2. Vartma shuklagata sandhi

It is the junction between the vartma mandala and shukla mandala. It can be considered as the site where the palpebral and bulbar conjunctiva meet i.e. Fornix.

3. Shukla krishnagata sandhi

It is the junction between the Shukla mandala and Krishna mandala. It can be considered as limbus.

4. Krishna drushtigata sandhi

It is the junction between the Krishna mandala and drushti mandala. It can be considered as free margins of iris (pupil).

5. Kaneenika sandhi (Nāsa sameepa sthita sandhi)

It is the junction between the upper and lower lid medially and is considered as medial or inner canthus. It is directly connected to nasal cavity through naso lacrimal canal.

6. Apanga sandhi (Bhrupucchanta sameepa sthita sandhi)

It is the junction between the upper and lower lid laterally and is considered as lateral or outer canthus. Position of the apānga sandhi is slightly higher than kaneenika sandhi.

NETRA PATALA

Patalas are the tunics/layers/coats of the eye. The exact co-relation of patala is not possible with the anatomical structure of the eye described in the modern science.

द्वे वर्त्मपटले विद्याच्चत्वार्यन्यानि चाक्षिणि । (S.U. 1/17)

There are six patalas in the eyes. Out of these two are in the eye lids called as bāhya patalās and four inside the eye. They are :

तेजोजलाश्रितं बाह्यं तेष्वन्यत् पिशिताश्रितम् । मेदस्तृतीयं पटलमाश्रितं त्वस्थि चापारम् ॥
पञ्चमोऽसमं दृष्टेस्तेषां बाहुल्यमिष्यते । (S.U. 1/18-19)

1. Prathama patala: Tejo jālāshrita: Cornea and Aqueous humor
2. Dvitiya patala: Pishitashrita: Iris, Ciliary body and Choroid
3. Tritiya patala: Medo āshrita: Lens. Some consider Vitreous as tritiya patala
4. Chaturtha patala: Asthi āshrita: Retina or Lens
 - i. Retina (as retina is held in the bony orbit)
 - ii. Lens (due to its solid appearance and seat for the disease Timira)

Different opinions regarding Patala

- a) According to Dalhana, patalas are counted from inside out.

- First patala - Asthi ashrita,
- Second patala - Medo ashrita,
- Third patala - Mamsa ashrita,
- Fourth patala - Tejojalashrita.

- b) According to other authors all the four patalas are the layers of lens as it is the seat for the manifestation of timira.

NETRA BANDHANA

Binding of the structures of eye is called Netra bandhana.

सिराणां कण्डराणां च मेदसः कालकस्य च । गुणाः कालात् परः श्लेष्मा बन्धनेऽक्ष्योः सिरायुतः ॥ (S.U. 1/19)

The structures which help in netra bandhana are- Sira (blood vessels), Kandara (tendons), Meda (fat), Kalakasthi (fascia attached to bony cavity) and Kapha.

NETRA MARMA

There are 3 marmās related with eye: (1) Apānga (2) Aavarta (3) Shringataka

1. Apaanga

भूपुच्छान्तयोरधोऽक्षोर्बाह्वतोऽपाङ्गौ, तत्रान्यं दृष्ट्युपपातो वा । (S. Sh. 6/27)

Apaanga is a vaikalyakara sira marma, $\frac{1}{2}$ angula in size, situated lateral to the eye just below the eyebrows. Injury to it leads to andhyatwa (loss of vision).

2. Aavarta

सुवोरुपरि निम्नयोरावर्तौ नाम, तत्राव्यान्यं दृष्ट्युपपातो वा । (S. Sh. 6/27)

Aavarta is a vaikalyakara sandhi marma, $\frac{1}{2}$ angula in size situated just above the eye brows. Injury to it also leads to andhyatwa (loss of vision).

3. Shringataka

प्राण श्रोत्राक्षिजिह्वा संतर्पणीनां सिराणां मध्ये सिरा सन्निपातः शृङ्गाटकानि, तानि चत्वारि मर्माणि तत्रापि सद्यो मरणम् । (S. Sh. 6/27)

Shringataka is the junctional area of siras nourishing ghrāṇa, shrotra, akshi and jihwa.

It is 4 angula in size and is a sadyoprāṇahara sirā marma. Any trauma to this is fatal.

Sira, Dhamani, Snayu, Peshi of Netra : (S. Sh.)

Sira	38
Dhamani	4-Roopavahini and 2 ashruvahini (one in each eye)
Snayu	2 (One in each eye)
Peshi	2 (One in each eye)

ANATOMY OF EYE

Eye Ball

The eyeball is a cystic structure usually referred as a 'globe'. Its shape is not spherical but oblate spheroidal in nature. The central point on the maximal convexities of the anterior and posterior curvatures is called anterior and posterior poles respectively. Each eyeball is suspended by extra ocular muscles and fascial sheaths in a quadrilateral pyramid shaped bony cavity called orbit.

Dimensions of adult eyeball

Anteroposterior	: 24mm
Horizontal	: 23.5mm
Vertical	: 23mm
Circumference	: 75mm
Volume	: 6.5ml
Weight	: 7g

Coats of the eyeball

The eyeball comprises of three coats

- Fibrous coat:** It is a dense strong wall, which protects the intraocular contents. It comprises of cornea anteriorly ($\frac{1}{6}$ " part) and sclera ($\frac{5}{6}$ " part) posteriorly. The junction between cornea and sclera is called 'limbus'.
- Vascular coat (uveal tissue):** It consists of three parts iris, ciliary body and choroid. It supplies nutrition to various structures of the eyeball.
- Nervous coat (retina):** It is concerned with visual functions.

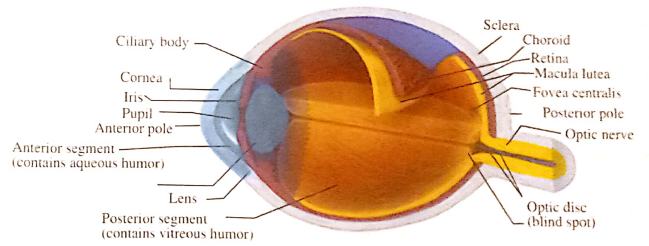


Fig. 4 : Section of Eyeball

Segment and chambers of the Eyeball

The eyeball can be divided into two segments: (1) anterior and (2) posterior.

1. **Anterior segment:** It is bounded anteriorly by cornea and posteriorly by crystalline lens. Further the iris divides the segment into anterior and posterior chamber filled with aqueous humour.

Anterior chamber is 2.5 mm deep in the centre in normal adults and contains 0.25ml aqueous humour. Posterior chamber is a triangular space containing 0.06 ml aqueous humour.

2. **Posterior segment:** It includes the structures posterior to the lens, viz. vitreous humour, retina, choroid and optic disc.

Orbit: The orbits are quadrangular pyramids made up of 4 walls: Medial, lateral, roof and floor. It is situated between the anterior cranial fossa above and the maxillary sinuses below formed by seven bones namely: frontal, ethmoidal, lacrimal, palatine, maxilla, zygomatic and sphenoid.

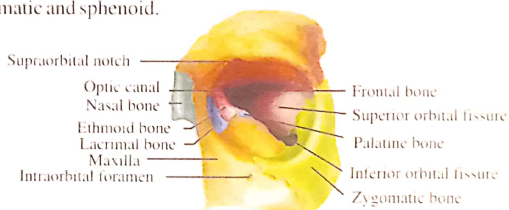


Fig. 5 : Eye Orbit

Appendages of Eye

The structures eyelids, eyebrows, conjunctiva and lacrimal apparatus are collectively called as 'appendages of the eye'. Eyelids are the shutters which protect the eye anteriorly. Eye brows are thick delicate hairs above the eyes which helps to prevent debris falling down to the eyes. The anterior part of sclera and posterior surface of lids are lined by conjunctiva. Cornea and conjunctiva are kept moist by the tear produced by lacrimal gland and drained by lacrimal passages.

Muscles of eye

There are six extraocular muscles that are present in the orbit which help to control the movement of the eye-

- | | | |
|--------------------|---------------------|---------------------|
| 1. Superior rectus | 2. Inferior rectus | 3. Medial rectus |
| 4. Lateral rectus | 5. Superior oblique | 6. Inferior oblique |

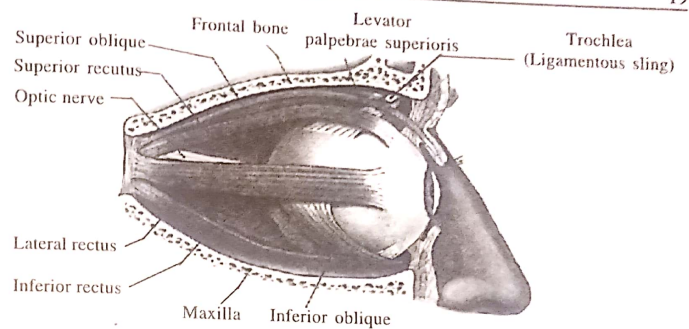


Fig. 6 : Muscles of the eye

KRIYA SHAREERA

Eye is the most important indriya among the five jñanendriyas. The function of the eye is to get the clear vision of the external world.

आत्मेन्द्रियमनोरथानां सन्निकर्षात् प्रवर्तते । व्यक्ता तदात्वे या बुद्धिः प्रत्यक्षं सा निरुच्यते ॥ (C. Su. 11/20)

The samyoga of indriya, atma, manas and indriyārtha leads to jñāna.

The perception of vision takes place in three stages:

1. Indriyārtha sannikarsha
2. Roopa alochanam
3. Jñānōtpatti.

1. **Indriyārtha sannikarsha :** (Contact of eye with the objects).

The perception of objects by indriya takes place in stages, by a number of complex mechanisms.

Stage 1: Conduction of light rays reflected by the objects to the eye.

Stage 2: Refraction of light rays inside the eye.

Stage 3: Convergence of light rays inside the eye on drushti patala.

Vāta is the functioning dosha in this stage in the presence of normal pitta and kapha.

2. **Roopālochana (Analysis of images)**

It is a very complex stage. Once the light rays converge on drushti patala, a series of reactions takes place. They are:

- a. **Photo chemical changes-** Concerned with the photosensitive pigment in the rods and cones of drushti patala.


- b. **Electrical changes-** When drushti patala is stimulated, the electrical variations (electrical potential) occurs in the nerve endings.
- c. **Nervous stimulation-** The nervous stimulation is developed by the electrical potential.
- Alochaka pitta (Chakshurvaisheshika) is the main functioning dosha in this stage.
3. **Jnānotpatti:** It occurs in following steps.
- a. **Conduction of the impulse** from drushti patala to buddhi.
- b. **Transformation of visual impulse to indriya jñana (visual sense).**

In this stage, conduction is carried out by Prana vayu and transformation of the visual impulse is carried out by alochaka pitta (Buddhirvaisheshika).

Functionally alochaka pitta has two fractions

1. Chakshurvaisheshika-acts at the level of eye.
2. Buddhirvaisheshika-acts at the level of buddhi.

The overall functions of the visual organ can be summarized as follows



Panchapanchaka of Netra

Indriya	Chakshur indriya
Indriya dravya	Tejas
Indriya adhishtana	Akshi
Indriya artha	Rūpa
Indriya buddhi	Chakshurbuddhi

PHYSIOLOGY OF VISION

Physiology of vision is a complex phenomenon. The main mechanisms involved in physiology of vision are:

- 1) **Initiation of vision (phototransduction)-** a function of photoreceptor.
- 2) **Processing and transmission of visual sensation-** a function of image processing cells of retina and visual pathway.
- 3) **Visual perception-** a function of visual cortex and related areas of cerebral cortex.

i) Phototransduction

The rods and cones serve as sensory nerve endings for visual sensation. Light falling upon the retina causes photochemical changes which in turn trigger a cascade of biochemical reactions that result in generation of electrical changes. This whole phenomenon of conversion of light energy into nerve impulse is known as phototransduction.

ii) Transmission of visual sensation and Visual pathway

Light falling upon the retina is absorbed by the photosensitive pigments present in the rods and cones, and initiates photochemical changes which trigger a sequence of events (electrical changes) that initiate the visual sensations. The long fibers originating from all ganglion cells of retina meet together and forms as optic nerve and come out of the eye ball through lamina cribrosa. Both the optic nerves (left and right) form optic chiasma. Here the fibres from nasal half of each retina crosses to join the optic tract of opposite and the fibres from temporal half of retina proceeds to the same side. The two optic tracts from chiasma moves outwards backwards, to end in the lateral geniculate bodies, from which new fibres for the optic radiation originates. The optic radiations on either sides pass through the posterior portion of the internal capsule and end in the calcarine cortex surrounding the calcarine fissure in the occipital lobe, which is also known as visual cortex.

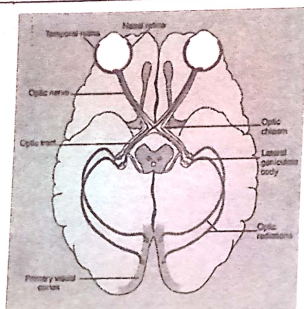


Fig. 7

iii) Visual perceptions

Visual perceptions are the functional elements of the vision- the sensations which result from stimulation of retina with light. These are of four kinds, namely: the light sense, the form sense, the contrast sense and the colour sense.

- a. **The light sense:** it refers to the appreciation of light.
- b. **The form sense:** it is the ability to discriminate between the shapes of objects.
- c. **Sense of contrast:** it is the ability of the eye to perceive slight changes in the luminance between regions which are not separated by definite border.
- d. **The colour sense:** it is the ability of the eye to discriminate between different colours excited by light of different wavelengths.

●

Chapter

1c

OCULAR EXAMINATION

Closer examination of the lids and different parts of the eyeball should be done with a loupe and torch. The loupe works like a magnifying lens.

I. Examination of the lids

1. Position of the lid margin in relation to the cornea.
2. Thickness of the lids.
3. Redness, oedema, localized swelling, any pigmentation or depigmentation.
4. Conditions of the lashes.
 - a. Any misdirection of the lashes as in trichiasis.
 - b. Any scantiness of lashes (madarosis).
 - c. Any white discolouration of lashes (vitiligo).
 - d. Any nits or parasites adhered to the lashes.
 - e. Any matting of the lashes with conjunctival discharge.
5. Lid margin proper.
 - a. Any inrolling (entropion) or outrolling (ectropion).
 - b. Any crust or ulcers.
 - c. Any thickness of margins (tylosis).
 - d. Any redness of margins.
 - e. Any defect of the lacrimal puncta i.e. eversion, stenosis or absence, any discharge.

Normal openings of the ducts of meibomian glands are visible as a series of white dots in front of the posterior sharp edge of the lid margin.

II. Examination of lacrimal sac

The following points are to be noted

- a. Any redness or swelling over the sac area

- b. Any fistula on the skin over the sac.
- c. Any regurgitation of watery, mucoid or purulent matter through the puncta on pressure over the sac area.

Test for Nasal patency

Patency of nasolacrimal passage is tested by introducing a lacrimal canula through the lower punctum and by pushing a coloured fluid like mercurochrome solution or normal saline. If the passage is blocked, the fluid regurgitates through the upper punctum and if the passage is patent then the patient will feel it in the throat via the nose.

III. Examination of conjunctiva

1. Bulbar conjunctiva
 - a. Whether normal or congested
 - b. Any chemosis or oedema
 - c. Any subconjunctival haemorrhage-petechial/patches
 - d. Any pigmentation, nodule or any tumour
2. Upper tarsal conjunctiva - the lid is everted by a gentle pull on the lashes and a simultaneous pressure over the skin with a glass rod.
 - a. Any alteration in the arrangement of normal vesicular pattern or any congestion.
 - b. Any follicle or papilla.
 - c. Any scarring.
 - d. Any membrane formation.
 - e. Any granuloma, tumour, mass or foreign body.
3. Lower tarsal conjunctiva

Pulling the lower lid downwards exposes the conjunctiva and fornix.

All the points as in the upper conjunctiva should be noted including any evidence of symblepharon.
4. The conjunctiva of the limbus
 - a. Presence of circumciliary congestion
 - b. Presence of any nodule
 - c. Presence of any newly formed tissue.

IV. Examination of plica semilunaris and caruncle for tumour.

V. Examination of sclera: Look for any change in colour, protrusion of uveal tissue or any congestion or nodules.

VI. Examination of the Cornea

- a. Diameter- Less in microcornea, more in buphthalmos.
- b. Curvature- Conical in keratoconus, globular or flat.
- c. Smoothness, opacity, vascularization, abrasion or oedema.
- d. Any changes in corneal sensation - elicited by touching the cornea with the tip of cotton wool.

VII. Examination of the angle of anterior chamber

It is only possible with a Gonioscope.

Gonioscopy

Owing to lack of transparency of corneoscleral junction it is not possible to visualize the angle of anterior chamber directly. Therefore, a device (gonioscope) is used to divert the beam of light and this technique of biomicroscopic examination of the angle of anterior chamber is called Gonioscopy.




Fig. 8

VIII. Examination of the pupil

- a. Size - Normally 3 - 4 mm
- b. Shape - Normally circular. Any irregularity is better noted if the pupil is dilated.
- c. Position - Whether central or eccentric and drawn to one side.
- d. Pupillary margin - Any adhesion with the lens capsule known as posterior synechia.
- e. Pupillary aperture- Clear or occluded.
- f. Pupil reaction
 - i. Reaction to light- Direct or consensual
 - Direct reaction- When the ipsilateral pupil contracts as soon as light enters the eye.

- Consensual reaction- Pupil of the contralateral eye contracts when the light enters in the ipsilateral eye.
- ii. Reaction to accommodation and convergence- pupil constricts on looking at a near object.

IX. Examination of the iris

Following points are to be noted:

- a. Iris pattern- Normal or altered
- b. Colour- Normal or any alterations in the colour.
- c. New vessels on the iris- Normally iris vessels are not visible
- d. Atrophic patch- Usually this area looks worn out and depigmented.
- e. Any gap or hole in the iris.
- f. Any tremulousness of iris known as iridodonesis- best elicited by movement of the eyeball particularly in an aphakic eye.
- h. Any adhesion of the iris to the posterior surface of the cornea known as anterior synechia.

X. Examination of lens

Thorough examination of lens needs a fully dilated pupil. Following points are to be noted:

- a. Colour of the lens- Grey, brown, white or transparent.
- b. Any opacity- Central, peripheral or total
- c. Any displacement- If partial it is called subluxation, if complete it is called luxation (dislocation).
- d. Presence or absence of the 3rd and 4th Purkinje images

XI. Examination of Intraocular pressure

Measurement of intra ocular pressure should be made in all suspected case of glaucoma and in routine after the age of forty years.

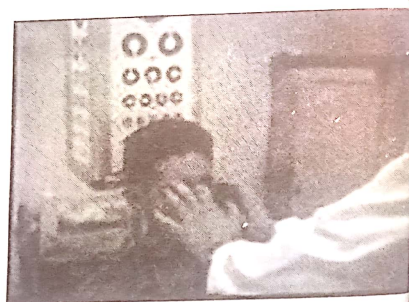


Fig. 9 Digital tonometry

(a) **Digital tonometry**- A rough estimate of I.O.P (intra ocular pressure) can be made by digital tonometry. The patient must look down so that the sclera is palpated through the upper lid beyond the tarsal plate. The tension is judged by the amount of fluctuation obtained. Other methods include indentation (Schiotz) and applanation tonometry.

(b) **Schiotz Tonometry**- By this instrument the resistance offered to the different weights used to indent the surface of the cornea is recorded by the movement of the pointer on the scale. After a local anesthesia the lids are separated with the fingers and the foot plate of the tonometer carrying a weight 5.5 gm is gently placed on the cornea. The deflection can be interpreted in terms of intraocular tension from the chart accompanying the tonometer. Normal intraocular tension varies from 11 - 21 mm of Hg.

(c) **Applanation tonometry**- The concept of applanation tonometry was introduced by Goldman in 1954. It is based on Imbert-Fick law which states that the pressure inside a sphere (P) is equal to the force (W) required to flatten its surface divided by the area of flattening (A) i.e. $P=W/A$.

The commonly used Applanation tonometers are:

Goldmann tonometer, Perkin's applanation tonometer, Pneumatic tonometer, Pulse air tonometer, Tono- pen.

XII. Fundus examination

Examination of fundus is essential to diagnose the diseases of vitreous, optic nerve head, retina and choroid. For thorough examination of the fundus, pupils should be dilated. The fundus examination can be accomplished by ophthalmoscopy (indirect/ direct) and slit lamp biomicroscopic examination.

a) Indirect ophthalmoscopy

Indirect ophthalmoscopy is performed with a condensing lens and a concave mirror. The fundus details are magnified 5 times and the image formed is real, inverted image of the fundus.

5 S.T.-I




Fig. 10
Schiotz tonometer



Fig. 11
Indirect ophthalmoscope


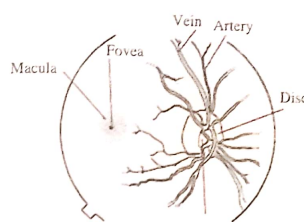


Fig. 12
Direct
ophthalmoscope

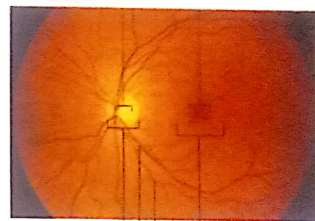
Fig. 13

During fundus examination following points are to be noted:

- **Media-** Normally the ocular media is transparent. Opacities in the media are best diagnosed by distant direct ophthalmoscopy, where the opacities look black against the red glow.
- **Optic disc-** It is a round or oval structure, pale pink in colour situated at the posterior part of the fundus. It is also known as optic nerve head, as the optic nerve start from this point. There is an excavation at the central part known as the physiological cup whose depth and extent varies in different subjects. The margins of the disc are normally sharp and distinct. So during examination of the fundus



Physiological cup Fovea



Macula
Retinal artery
Retinal vein
Neuroretinal rim

Fig. 14

the colour, shape of the disc, its margins, the physiological cup, presence of any abnormal vessels or any other abnormality on the disc have to be noted.

- **Macular area-** It is a small circular area with a red colour which is deeper than that of surrounding fundus and is situated at about 2 disc diameters on the temporal side of the optic disc. The glistening central point of macular area is known as fovea centralis. It is slightly depressed and this depression is known as the foveal pit. During ophthalmoscopic examination, due to reflection of light, this pit appears as a bright reflex which is known as foveal reflex. Any abnormality in the macular area has to be noted.
- **Retinal blood vessels-** These consists of arteries which are branches of the central retinal artery of the retina and the veins which are branches of the central vein of retina. These vessels radiate from the optic disc and they spread over the fundus. The arteries which are in fact arterioles at a short distance from the disc, are narrower than the veins. The end arteries are bright red in colour where as the veins are purplish red. During examination of the fundus, any narrowing, tortuosity or dilatation or sheathing of the vessel, any alteration in the light reflex from the vessel wall and any venous compression at the arterio - venous crossings are to be noted.
- **General appearance of the fundus:** Normally the fundus has a uniform red appearance. But colour depends on the degree of pigment in the retinal pigment epithelium. The fundus should be examined all around for any abnormalities like superficial and deep retinal hemorrhages, cotton wool spots, hard exudates, drusens, microaneurysms, retinal holes, retinal detachment etc.

SUBJECTIVE EXAMINATION

This includes:

i. Central or direct vision

- Distance vision with Snellen's test types.
- Near vision with Snellen's type or Jaeger's chart.
- Colour vision with Ishihara chart.

ii. Field of vision

- Peripheral field by confrontation method.
- Perimeter.

(i) Central or direct vision

Distant or near vision is tested by using different kinds of charts like Snellen's or Jaeger's and colour vision is usually tested using Ishihara chart.



Fig. 15 : Snellen's chart

How to record visual acuity or central vision for distance

A chart containing Snellen's test types is essential. These test types are square shaped letters in a Snellen's chart. (Fig.15) In the chart they are gradually diminished in size from above downwards, a numerical number written underneath each line of the test types.

Principle of Snellen's test types- Each individual letter subtends an angle of 5 minutes and each component part of the letter subtends an angle of 1 minute at the nodal point of the eye from the distance in meters shown by the numerical number written under each line of type. This principle is in conformity with the standard of normal visual acuity.

- Distance at which the Snellen's test types have to be kept- It should be at distance of 6 metres or 20 feet. The rays of light from that distance are practically parallel. Half this distance may also be utilized, but in that case the test types should be seen reflected through a plain mirror, kept at a distance of 3 metres or 10 feet from the patient.

- Illumination of the Snellen's test types- it should not be below 20 foot candles.

The test types should be more or less at the eye level of the patient. The test types should be clearly printed in black on white back ground with uniform illumination.

- Individual eye must be examined separately while keeping the other eye closed.
- For illiterate patients a chart containing various sizes of 'E' or 'C' can be used. The patient is required to find out the direction of the hands of E or the gap of C.

Method of recording distant vision

Visual acuity is expressed by a fraction, the numerator of which is the distance of the chart from the patient, i.e 6 metres and the denominator is the numerical number written below the line up to which the patient can read. For example if the patient can read upto the line under which is written 24, the vision is 6/24 which means that he reads the letters from a distance of 6 metres which a normal person would have read from a distance of 24 metres.

If the patient fails to read even the biggest letter from a distance of 6 metres, he is brought towards the chart at a distance of 5 meters, 4 metres, 3 meters and so on until he can read the biggest top letter and the vision is recorded as 5/60, 4/60 or 3/60 and so on.

Method of recording near vision

Near vision is tested by asking the patient to read the near vision chart, kept at a distance of 35 cm in good illumination with each eye separately. In near vision

charts a series of different sizes of printer type are arranged in increasing order and marked accordingly. If he cannot read the smallest types, the types which he can read should be noted by noting the number against the types.




Fig. 16

Examination of color vision

This is conducted to elicit quantitative analysis of colour blindness. Commonly employed colour vision tests are as follows:

a. Lantern test


The usual appliance used is the Edridge - Green's lantern

b. Holmgren's wools of various colours.

The examiner selects a particular colour and asks the patient to pick up the wool whose colour matches with the colour of the selected wool.

c. Pseudo isochromatic charts

The most used is the Ishihara chart - this consists of coloured plates in which bold numbers are shown in dots of various tints, set amid dots of the same size but of different tints. A normal person can easily read the numbers.

Fig. 17
Ishihara Chart

(ii) Field of vision

Confrontation method

Here the patient's field of vision is compared with that of the observer having a normal field of vision. The examiner (whose vision is normal) stands facing the patient at a distance of one metre. The patient covers his left eye and fixes his vision on the examiner's left eye. The examiner closes his right eye, and moves his hand from the periphery towards their common line of vision keeping the hand in the plane halfway between him and the patient. When he sees it himself, the patient ought to say that he also sees it. The movements of the hand are repeated in various parts of the field - above, below, to the right, to the left and so on.

b. Perimetry




Fig. 18

It is done using Perimeter- a metallic semicircle, whose radius is 1/3rd of a metre which can be rotated in all meridians. The patient's chin lies on a chin rest placed at the centre of the semicircle. The eye, not to be examined is closed by a pad and the eye for examination fixes an object placed at the centre of the metallic arc. A white test object of size 3mm is then moved along the inner surface of the arc from the extreme periphery towards the centre. The point where the object is seen first is recorded automatically on a chart in degrees. This recording is done in all meridians.

Extent of normal field of vision:

- On nasal side (medially) : 60°
- Superiorly : 50°
- Inferiorly : 70°
- On the temporal side (laterally) : 90°

- Netra Roga Samānya Nidāna
- Samānya Samprāp̥thi of Netra Roga
- Samānya Poorva Rūpa of Netra Roga
- Samānya Chikitsa of Netra Roga
- Pathya Apathya in Netra Roga

NETRA ROGA SAMĀNYA NIDĀNA

All diseases are caused due to the vitiation of Vāta, Pitta and Kapha.

Mithya ahāra, vihāra, rutu viparyaya, abhigāta and one's prakruti (constitution) are responsible for the formation of disease. Similarly, the netra roga nidanas explained by our Acharyas are based on the above factors.

The samānya nidāna for netra roga have been explained by Sushruta, Bhāva-prakāsha, Yogaratnakara & Videha.

उष्णामितस्य जलप्रवेशाद्दूरेक्षणात् स्वप्नविपर्ययाच्च । प्रसक्त संरोदन कोप शोक क्लेशाभिघातादतिमैथुनाच्च ॥
शुक्लारनाम्ल कुलत्थ माष निषेवणाद्देगविनिग्रहाच्च । स्वेदादथो धूमनिषेवणाच्च छर्देर्विघाताद्दमनातियोगात् ॥
वाय्वग्रहात् सूक्ष्मनिरीक्षणाच्च नेत्रे विकारान् जनयन्ति दोषाः ॥ (S.U.1/26,27)

उष्ण अभितस्य जलप्रवेशात्- Exposure to cold immediately after exposure to heat.

Immediate and altered exposure to heat and cold, affects the temperature maintained in eye leading to various eye diseases.

दूरेक्षणात्- Constant staring at distant objects.

Atiyoga and mithayoga are the primary causes leading to any disease. Here, constant staring at distant objects strains the eye muscles causing netra roga.

स्वप्नविपर्यय- Abnormal sleeping habits.

Day sleep vitiates kapha and awakening at night vitiates vata and pitta, leading to eye diseases.

प्रसक्त संरोदन- Continuous weeping.

Excessive lacrimal secretion due to continuous weeping washes the nutrients and bacteriolytic enzymes in the conjunctiva paving way for manifestation of diseases.

कोप शोक : Anger and grief.

Excessive Anger and grief leads to aggravation of pitta and vāta respectively.

क्लेशा : Stress/Strain.

Excessive strain to body and mind leads to vata vitiation, which inturn may lead to visual impairment.

अभिघातात्- Trauma.

Injury to eye (blunt/perforating) may cause severe damage leading to complete loss of vision if not treated immediately.

अतिमैथुनात् : Excessive intercourse.

Indulging in excessive sexual intercourse will lead to dhātu kshaya and vata prakōpa leading to eye diseases.

शुक्ल अरनाल आम्ल कुलत्थ माष निषेवणात्

Shukta and Aranāla are alcoholic preparations having amla rasa and are ruksha, teekshna in nature. These when taken in excess vitiates pitta leading to eye disorders.

Kulartha (horse gram) has vidāhi guna, ushna veerya and katu vipaka, which when taken in excess causes vitiation of rakta and pitta leading to eye diseases.

Masha (black gram) has madhura, guru and snigdha guna. It aggravates kapha when taken excessively leading to kaphaja netra rogas.

वेगविनिग्रहात् : Suppression of urges.

Suppression of urges like jumbha, hikka, ashru, kshudha etc causes vitiation of vāta leading to eye diseases.

स्वेदात् : Fomentation to Eye.

Excessive fomentation to eye aggravates pitta and rakta leading to netra rogas.

धूमनिषेवणा : Exposure to smoke.

Excessive exposure to smoke or smoking leads to eye diseases (e.g. toxic amblyopia due to tobacco smoking).

छर्देर्विघाताद् : Suppression of vomiting.

Chardi vega dharana leads to netra kandu due to vitiation of kapha.

वमनातियोगात् : Excessive vama.

It can cause protrusion of eye ball due to the pressure created by it. It can also cause retinal and subconjunctival haemorrhage.

वाष्पग्रहात् - Suppression of tears.

When tears are suppressed, it leads to akshirogas related to ashruvaha srotas.

सूक्ष्मनिरीक्षणाच्च: Observing minute things.

Observing minute objects continuously for long duration causes strain to ciliary muscles of eyes leading to visual impairment.

Causes for Eye diseases mentioned by other authors

According to Bhavaprakasha:

रजो धूम निवेवणात्: Exposure to dust and smoke.

This leads to foreign body sensation, watering, burning sensation and redness of eyes.

अति शीघ्र यानात् : Fast travelling.

Fast travelling causes exposure of eye to wind leading to dryness of eyes.

ऋतुनाम् विपर्ययः Abnormal climatic changes.

Abnormal changes in the climate leads to vitiation of doshas causing numerous ocular diseases.

शितो अभितापः Excessive exposure of head to heat.

This vitiates pitta and rakta leading to eye diseases.

According to Yogaratnakara:

अति द्रव्यपानः Excessive intake of liquid diet leads to kapha vridhhi.

अति मद्यपानः Excessive intake of alcoholic beverages leads to toxicity. (e.g. toxic amblyopia).

According to Videha: (S.U.19/3) (Dalhana com).

- Applying teekshna anjana on an already strained eye.
- Insect bite.
- Eye injuries due to water sports (swimming against fast flowing water, diving etc).
- Keeping awake at night.

- Excessive fasting, straining, tiredness, fearfulness.

- Weak eyes visualizing sun, fire, lunar eclipse, stars or moving objects continuously.

All the above causative factors produce redness, burning, pricking sensation, swelling, inflammation, foreign body sensation and other different types of symptoms in the eyes.

SAMANYA SAMPRAPTI OF NETRA ROGAS

सिक्तानुसारिभिर्दोषैर्विगुणैरुर्ध्वमागतैः । जायन्ते नेत्रभागेषु रोगाः परम दारूणाः ॥ (S.U. 1/20-21)

Sirā anusāribhihi- Through the blood vessels	Dóshaihi- Tridoshas
Vigunaihi- Vitiates	Urdhwam aagantaihi- Moves upwards
Jāyante- Produces	Netra bhagésu- In the parts of eye
Roga- Diseases	Parama daruna- Fatal.

Due to nidanas, the doshas which have undergone vitiation move in the upward direction through the blood vessels (sirās) and produce different diseases in the various parts of eye which may be severe or fatal.

According to Vagbhata

पर्वरोग निदानोक्तैरहितैः कुपिता मलाः ।

अचक्षुष्यैर्दिशेण प्रायः पित्तानुसारिणः । शिराभिरुर्ध्वं प्रसृता नेत्र अवयवमात्रिताः ॥

नर्त्यं संघं सितं कृष्णं दृष्टिं वा सर्वमक्षि वा ॥ रोगान् कुर्युः । (A.S.U.11/2)

Sarva roga- All the diseases	Nidānairukata- Causes mentioned
Ahitai- Not suitable	Kupita mala- Increased mala
Achakshushyai- Not good for eyes	Visheshena- Especially, Prāyaha=Mostly
Pittānusarina- Vitiates pitta	Sirābhi urdwam prasruta- Through the siras moves upwards
Netra avayavam- In the parts of eyes	Ashrita- Locates
Rogan Kuryuh- Produces diseases	

The increased mala caused due to nidana sevana especially which are achakshushya (not good for eyes) and pitta prakopaka, move in the upward direction through the sirās and gets localized in different parts of the eye producing vartma, sandhi, sita, krishna, drishti & sarvakshi rogas.

Nidana sevana
(Achakshushya & pitta prakopaka)

↓
Vitiating of doshas

↓
Moves in upward direction through siras

↓
Netra vikaras

(Vartma, Sandhi, Sita, Krishna, Drushti and Sarvakshi rogas)

SĀMĀNYA PŪRVARŪPA OF NETRAROGAS

Pūrva rūpa is the stage in which the prodromal symptoms appear even before the actual manifestation of the disease.

तत्र आविलं स संरम्भं अश्रुकण्डु उपदेहवत् । गुरु ऊया तोद रागाद्यैः जुष्टं च अव्यक्तलक्षणैः ॥ (S.U.1/21)

Avilam- Eye discharge

Ashru- Lacrimation.

Upadeha- Coating due to sticky discharge

Oosha- Burning sensation

Raga- Redness/hyperaemia

Avyakta lakshana- Non manifested symptoms.

Sa samrambha- Mild swelling

Kandu- Itching

Guru- Heaviness

Toda- Pricking pain

Jushta- Found

The following are the prodromal symptoms of eye diseases in general: Discharge, swelling, lacrimation, itching and coating (due to sticky discharge).

Depending on the doshas involved

- Kapha- Heaviness of eye
- Pitta- Burning sensation
- Vata- Pricking pain
- Rakta- Redness

सञ्चलं वर्त्तकोपेषु शूकपूर्णाभिमेव च । विहन्यमानं रूपे वा क्लिगस्वक्षि यथा पुरा ॥ (S.U.1/22)

Sa Shoola- Associated with pain. **Vartmakósha-** Eye lids

Shookapoorna- Foreign body sensation.

Vihanyamaanam roopa- Visual disturbance with respect to color & form.

Kriyāsu akshi- Functions of eye.

The other prodromal symptoms are:

Pain in the eyelids, foreign body sensation, visual disturbance with respect to color and form, impairment of functions of eye.

SĀMĀNYA NETRA ROGA CHIKITSA

सङ्क्षेपतः क्रियायोगो निदानपरिवर्जनम् । वातादीनां प्रतीघातः प्रोक्तो विस्तरतः पुनः ॥ (S.U.1/25)

Samkshépātah- In brief

Kriya yoga- Treatment

Nidaana- Etiological factors

Parivarjana- Avoidance

Vaataadinām- Vata and other doshas

Pratighata- Subside

Próktāh- As told

Vistāratah- In detail

Punah- Again/Later

In brief, the general line of treatment for all the eye diseases is to avoid the etiological factors and to subside the vitiated doshas by specific treatments which are explained later in detail.

PATHYA-APATHYA IN NETRA ROGAS (Yogaratanakara)

Pathya: Aschotana, langhana, anjana, swédana, viréhana, pratisārana, prapūrana, nasya, raktamókshana, shastrakarma, lépana, ghṛitapāna, séka, manō nivṛitti, worshipping elders.

Mudga, yava, rakta shaali, kaumbha sarpi, kulattha, yūsha, pēya, vilēpi, sūrana, patóla, vārtāka, kārkotaka, kāravellaka, nava moolaka, punarnava, kākamāchi, pattura shāka, saindhava, kumārika, drāksha, kustumburu, rodhra, triphala, madhu, upanāha, stanya, chandana, karpura, and those which are tikta and laghu in nature are considered pathya for eyes.

Apathya

Yogaratanakara cautions the patients of eye diseases to abstain from anger, excessive intercourse, grief, tears, suppression of urges like flatus, faeces, urine, sleep and vomiting, looking at minute objects, grinding of teeth, eating at night, exposure to sun, irrelevant talk, over emesis, excessive drinking of water, curd, leafy vegetables, oil cake, sprouted grains, fish, wine, meat other than of wild creatures, tāmbula, sour, salty, vidāhi, pungent, bitter, hot and heavy food substances.

Intake of blackgram, sour gruel, mustard oil, immersing excessively in water, alcoholic drinks, curds, excessive sexual act, awakening throughout the night, seeing sun through naked eye, will damage the eye and cause degenerative changes in the eye.

Chapter

1E

- Classification of Netra roga according to different authors
- Classification of Ocular disorders as per Modern

Diseases present differently due to the vitiation of specific dosha, involved structures and pathogenesis. So the treatment to be adopted also varies accordingly. Hence classification becomes essential.

CLASSIFICATION OF NETRA ROGA

Netra Roga	Sushruta	Vagbhata	Madhava Nidana
Vartmagata	21	24	21
Sandhigata	9	9	9
Shuklagata	11	13	11
Krishnagata	4	5	4
Drushtigata	12	27	12
Sarvagata	17	16	17
Bāhya nimittaja	2	-	2
Total	76	94	76

Other Classifications

There are many opinions regarding the number of netra rogas, which are summarized here.

- Charaka 4 (Vātaja, Pittaja, Kaphaja and Sannipātaja).
- Vidēha/Yogarātnakara - 76
- Karaala - 96
- Satyaki - 80
- Bhāvamishra - 78
- Shārangadhara - 94

Sushruta has Classified Netra Rogas as follows

1. Based on Doshas

Vātaja	Pittaja	Kaphaja	Raktaja	Sannipātaja	Bāhya
↓	↓	↓	↓	↓	↓
10	10	13	16	25	2

2. Based on Netra Avayava

Sandhi	Vartma	Shukla	Krishna	Sarva	Drushti	Bāhya
↓	↓	↓	↓	↓	↓	↓
9	21	11	4	17	12	2

3. Based on Sādhya-sādhya

Sādhya	Yāpya	Asādhya
↓	↓	↓
52	7	17

4. Based on Chikitsa

Chēdya	Lēkhya	Bēdya	Vēdya	Ashastra	Yāpya	Asādhya
↓	↓	↓	↓	↓	↓	↓
11	09	05	15	12	07	17

Vātaja-10		
Sādhya-05	Yāpya-01	Asādhya-04
1. Vātaja abhishyanda 2. Vātaja adhimanta 3. Shushkakshipāka 4. Anyatō vāta 5. Vāta paryāya	Vātaja kācha	1. Gambhirika 2. Haṭadhimanta 3. Nimēsha 4. Vātahata vartma
Pittaja-10		
Sādhya-06	Yāpya-02	Asādhya-02
1. Pittaja abhishyanda 2. Pittaja adhimanta 3. Amladyūshita 4. Shuktika 5. Dhoomadarshi 6. Pitta vidagdha drushti	Pittaja (Neela) kācha Parimlāyi kācha	1. Pittaja srāva 2. Hṛisva jādyā

	Kaphaja-13	
Sādhyā-11	Yāpya-01	Asādhyā-01
1. Kaphaja abhishyanda 2. Kaphaja adhimanta 3. Shleshma vidagdha drushti 4. Shleshmopanāha 5. Krimigranthi 6. Klinna vartma 7. Lagana 8. Póthaki 9. Shuklārma 10. Pishtaka 11. Balāsagrathita	Kaphaja kācha	Kaphaja srāva

Raktaja-16

Sādhyā-11	Yāpya-01	Asādhyā-04
1. Raktaja abhishyanda 2. Raktaja adhimantha 3. Sirotpāta 4. Sirāharsha 5. Parvani 6. Klišhtavartma 7. Anjana nāmika 8. Sirajāla 9. Arjuna 10. Shonitārma 11. Avṛṇa shukla	Raktaja kācha	1. Raktaja srāva 2. Shonitārsha 3. Ajakājāta 4. Savṛṇa shukra

Sannipātaja-25

Sādhyā-19	Yāpya-02	Asādhyā-04
1. Utsangini 2. Kumbhika 3. Vartmasharkara 4. Arsho vartma	Sannipātaja kācha Pakshmakōpa	1. Puyasrāva 2. Alaji 3. Nakulāndhya 4. Akshipakātyāya

5. Shushkarsha 6. Arbuda 7. Aklinna vartma 8. Vartmāvabandha 9. Bahala vartma 10. Shyāva vartma 11. Bisā vartma 12. Vartma kardama 13. Sashopha akshipāka 14. Ashōpha akshipāka 15. Puyālasa 16. Prastāri arma 17. Adhimāmsaja arma 18. Snāyu arma 19. Sirapidaka		
---	--	--

Bahyaja-02

Sādhyā	Yāpya	Asādhyā
		1. Sanimittaja linganāsha 2. Animittaja linganāsha

5. Based on Shastra chikitsa

S.N.	Chédya	Bhédyā	Lékhyā	Védya	Ashastra	Asādhyā	Yāpya
1.	Prastāri arma	Anjana nāmika	Utsangini	Sirotpāta	Shushka-kshipāka	Haṭādi-mantha	Vātika kācha
2.	Shuklārma	Lagana	Kumbika	Sirāharsha	Kapha Vid-agda drishti	Nimēsha	Pittaja kācha
3.	Raktārma	Bisā vartma	Póthaki	Sashōpha akshipāka	Pitta vidagdha drishti	Gambh-irika	Kaphaja kācha
4.	Adhim-āmsārma	Krimigr-anthi	Vartma sharkara	Ashōpha akshipaka	Amlady-ūshita	Vātahata-vartma	Raktaja kācha
5.	Snayvarma	Shleshmopanāha	Bahala vartma	4 types of Abhishyanda	Avrana shukla	Hṛswa-jādyā	Tridoshaja kācha
6.	Sirajāla		Vartm-āvabandha	4 types of Adhimantha	Shuktika	Pittaja srāva	Parimlayi kācha

S.N.	Chédya	Bhédya	Lékhyā	Védya	Ashastra	Asādhya	Yāpya
7.	Sirā pitika		Shyāva vartma	Anila- paryaya	Arjuna	Kaphaja srāva	Pakshma kōpa
8.	Arsho- vartma		Vartma kardama	Puyālasa	Pishtaka	Raktaja srava	
9.	Shusk- ārshas		Klishta vartma	Anyatō- vāta	Praklinna vartma	Ajakajatha	
10.	Arbuda				Aklinna vartma	Shonitārsha	
11.	Parvani				Balasa- grathitha	Savṛana shukra	
12.					Dhūma- darshi	Puyāsrāva	
13.						Nakulāndhya	
14.						Akshipākātyāya	
15.						Alaji	

MODERN CLASSIFICATION OF THE DISEASES OF EYE

a. Eyelid disorders

- Benign nodules, cysts and tumours
- Malignant tumours
- Disorders of lashes– eg. Trichiasis
- Allergic disorders– eg. Atopic dermatitis
- Bacterial infections– eg. External hordeolum
- Viral infections– eg. Molluscum contagiosum
- Blepharitis
- Ptosis
- Entropion
- Ectropion

b. Lacrimal system disorders

- Epiphora
- Acquired obstruction – eg. Punctal stenosis
- Congenital obstruction- eg. Naso-lacrimal duct obstruction
- Chronic canaliculitis
- Dacryocystitis
- Dry eye

c. Orbital disorders

- Thyroid eye disease-eg. Thyrotoxicosis
- Infection- bacterial orbital cellulitis
- Non-infective inflammatory disease-eg. Acute dacryoadenitis
- Vascular malformations- lymphangioma
- Cystic lesions-eg. dermoid cyst
- Tumours- capillary hemangioma

d. Conjunctival disorders

- Inflammatory– eg. Infective, allergic and granulomatous conjunctivitis
- Degenerative– eg. Pterygium, pingueculum

e. Scleral disease

- Scleritis
- Staphyloma of the sclera
- Episcleritis
- Blue sclera

f. Corneal disorders

- Keratitis leading to corneal ulcer/opacity
- Corneal dystrophies
- Corneal ectasias– eg. Keratoconus
- Degeneration– eg. Arcus senilis

g. Lenticular disorders

- Cataract
- Ectopia lentis

h. Retinal disorders

- Retinitis
- Chorioretinitis

- Diabetic retinopathy
- Hypertensive retinopathy
- Retinopathy of prematurity
- Retinal detachment
- Macular degeneration
- Coat's disease
- Macular oedema
- Retinitis pigmentosa
- Central serous retinopathy

i. Optic nerve and visual pathways

- Optic neuritis
- Papilledema
- Anterior ischemic optic neuropathy
- Optic atrophy
- Toxic and nutritional optic neuropathy

j. Refractive errors

- Myopia
- Astigmatism
- Hypermetropia
- Anisometropia

k. Visual disturbances and Blindness

- Amblyopia
- Color blindness
- Nyctalopia
- Hamarlopia
- Diplopia
- Blindness/Low vision

l. Infectious diseases

1. Trachoma
2. Onchocerciasis

m. Other diseases

1. Nystagmus
3. Ocular hypertension
5. Xerophthalmia
2. Mydriasis
4. Keratomycosis
6. Miosis

Review Questions

1. Describe Netrashareera (anatomy of eye) in detail with the help of diagram.
2. Describe kriyashareera of netra (physiology and neurology of vision) in detail.
3. Describe the appendages of eye.
4. Describe netrapatalas, mandalas and sandhis.
5. Describe the panchabhoutikatva of netra.
6. "Shalakya tantra nirukti and itihasa"- Describe.
7. Explain the importance of Shalakya tantra.
8. Mention the common equipments used for examination of eye.
9. Write the samānya nidana, samprāpti, pūrvarūpa and chikitsa of netra rogas.
10. Write the panchapanchaka of netra.
11. Describe classification of netra rogas and its importance as per Sushruta.
12. Write a short note on Nimi.
13. 'Netra pramāna' - Ayurveda and modern view.
14. Describe mamsa, peshi, siras and marma of the eyes.
15. Write briefly on 'Kankayana' and 'Satyaki'.

Scope for Research

1. Correlate the peshis of netra with the muscles of eye.
2. Historical research regarding the luminaries of Shalakya Tantra.

Chapter-2

NETRA SAMĀNYA AND VISHISHTA CHIKITSA KRIYA KALPA

- | |
|--|
| A. Netra and Chakshu swāsthya hitakara Dinacharya, Rutucharya, Aahāra evam Vihāra. |
| B. Kriya-kalpa-Seka, Aschotana, Pindi, Bidalaka, Tarpana, Putapaka, Anjana and importance of Panchakarma in Netra Chikitsa. |
| C. Basic fundamentals of Netra Shastra Chikitsa e.g. Purva- Pradhana- Paschat karma, Ama-Pachyamāna-Pakva Vrana shotha, Vranitopāsana, Pranastashalya & Vranabandhana. Methods and concepts of sterilization, asepsis and antiseptics as per ancient and modern point of view. |
| D. Basic applied knowledge of Ashtavidha shastrakarma, agni, kshāra, raktamokshana in Netra rogas. |
| E. Essential diagnostic and therapeutic modern pharmacological agents required in Netra Chikitsa. |

Chapter

2A

- Importance of Vision
- Role of Dinacharya and Rutucharya in Promoting Vision
- Chakshushya Dravyas
- General Measures Good for Eyes

NETRA SWĀSTHYA RAKSHANOPAYA

चक्षुष्यम् चक्षुषे हितं । (Dalhana, S.Su-45/132)

The word Chakshu means "eyes" and anything which is good for the eyes and vision is called Chakshushya.

Importance of vision

चक्षुरक्षायां सर्वकालं मनुष्यैः यत्नः कर्तव्यो जीविते यावत् इच्छा ।

व्यर्थो लोको अयं तुल्यरात्रिन्दिवानां पुंसामन्यानां विद्यमाने अपि वित्ते ॥ (A. S. U. 16/29)

Day and night are similar for a blind person and all the wealth in the world seems to be of no use. Hence to lead a desired life, one should always try to protect the eyes.

Regimen to be followed for better vision

सर्वदा च निषेवेत स्वस्थोऽपि नयनप्रियः । पुराणं यव गोधूमं शालिं षष्टिकं कोद्रवान् ॥

मुद्गादीन् कफपित्तघ्नान् भूरिसर्पिः परिप्लुतान् । शाकं चैवंविधि मांसं जांगलं दाडिमं सिताम् ॥

सैन्यं त्रिफलां द्राक्षां वारि पाने च नाभसम् । आतपत्रम् पादत्राणं विधिवत् दोषशोधनं ॥ (A.H.U.16/61-63)

One who desires to have healthy eyes should adopt following measures

- Consume kapha pitta hara aharas like Purāna yava, Godhūma (wheat), Shālī, Shastikashālī, Kódrava, Mudga etc along with ghee, Shāka (vegetables), Jāngalamamsa, Dādima, Sita, Saindhava, Triphala, Drāksha and Jala (nabhasa).
- Use umbrella and footwear regularly.
- Adopt regular Shodhana (purificatory measures in ětus).

Acharya Nimi has advised the following measures for Chakshu samrakshana

त्रिफला रुधिरस्रुतिः विशुद्धमनसो निर्वृत्तिरश्नं स नस्यम् । शकुनाशनता सपादपूजा घृतपानं च सदैव नेत्ररक्षा ॥
अहितादर्शनात् सदा निर्वृतिः घृश भस्वत् चल सूक्ष्म वीक्षणान्त्र ।
मुनिना नियमोपदिष्टमेतत् परं रक्षणं ईक्षणस्य पुंसाम् ॥ (A.S.U.16/30)

Triphala, raktamokshana, controlling the mind, anjana, nasya, intake of flesh of birds and Ghrita, taking care of the feet, avoid viewing of unpleasant, bright, moving and minute objects.

ROLE OF DINACHARYA AND RUTUCHARYA IN PROMOTING VISION

Dinacharya, Rutucharya, Ahāra and Vihāra are mentioned in Ayurveda to promote health and prevent diseases. These regimens can be followed to preserve, protect and promote the vision also.

(A) Dinacharya

- Regular Mukha prakshalana (S. Chi. 24/17)
- Regular Shiro abhyanga (S. Chi. 24/25-26)
- Use of cold water for head bath as hot water is harmful to eyes (S. Chi. 24/59)
- Daily application of Anjana (souviraniana) not only enhances the visual acuity but also helps to withstand sun light, heat and wind. (S.Chi. 24/17-19)
- Regular Pādaprakshalana, Pāda abhyanga and pādātradhārana (S.Chi. 24/69-70)
- Regular practice of Jalanēti. (Vaidyaratnam 4/13)
- Chatradhāranam- To protect eyes from excessive sunlight. (S.Chi. 24/75)
- Tarpana- Should be done with an interval of 2 days in swastha (A.H.Su.24/10)

Importance of Pada samrakshana

द्वे पादमथ्ये पृथुसत्रियेशे शिरे गते ते बहुधा च नेत्रे । ताम्रक्षणा उद्धर्तनलेपनादीन् पादप्रयुक्ताजयने नयन्ति ॥
मलीष्यमङ्गुट्टनपीडनाद्यैस्ता दूषयन्ते नयनानि दुष्टाः । भजेत्सदा दृष्टिं हितानि तस्मादुपानदभ्यञ्जनं यावन्तानि ॥
(A.H.U.16/66-67)

Dirt, heat, injury, strenuous movements of feet etc vitiates eye and its functions. So regular pada abhyanga, udvartana and lepana is advised. The siras present in the pada are connected to the eyes which helps in its nourishment.

There is reference in Yogarnava regarding the two nadis namely Pusha and Alambusha which traverse from pada to netra.

(B) Rutucharya

Pathya, apathya ahara and vihara and ritu shodhana as advised in particular ritu should be followed. This not only helps to protect and prevent ocular disorders but also promotes vision.

CHAKSHUSHYA DRAVYAS

- Milk and milk products like Go ghrita, Stanya, Navaneeta, Aja ghrita (Su.Su.).
- Kharpara, Raktachandana, Kasturi, Lavanga, Prapoundarika (Raja nighantu).
- Triphala, Ghrita, Madhu, Yava, Shatāvari, Mudga (Vangasena).
- Swarna, Abhraka, Tāmra, Vanga, Loha, Swarnamakshika, Tuttha, Kāseesa.
- Shakapanchakas like Jeevanti, Vaastuka, Matsyaakshi, Meghanada and Punarnava (Yogaratanakara).

APATHYA

व्रजयेत् वेगं संरोधं अजीर्णं अध्यशनानि च । क्रोध शोकं दिव्याम्यन् रात्रिजागरणं आतपान् ॥
विदाहि विष्टम्भकरं यत् च इह आहारं भेषजम् । (A.H.U. 16/64-65)

Vega dhārana, ajeerna, adhyashana (consuming food before the digestion of previous meal), krodha, shōka, divāswapna, rātri jāgarana, vidāhi and vištambhakara ahāra and aushadha should be avoided to maintain good vision.

GENERAL MEASURES WHICH ARE GOOD FOR EYES AND VISION

- Regular intake of triphala, purāna ghrita, madhu, yava (barli), shatāvari, patōla, mudga, amalaki (S.U.17/48).
- Triphala kwatha/churna along with honey/ghee in the evening.
- Washing of eyes with triphala kwatha in the early morning. (A.H.U.16/66)
- Regular Pada abhyanga, udvartana, lepana, padaprakshalana
- Padasamrakshana vidhi like padatradharana.
- Shatavari rasa or amalaki rasa siddha yavāgu.
- Triphala kwātha, yavodana with ghee.

EYE EXERCISES

Eye exercises are aimed at toning up the eye muscles and also for relaxation of eyes. Dr. W.H. Bates method of eye exercises are practiced even today and is found to be effective specially in refractive errors and neurological eye disorders.

1. **Sunning:** Exposing to early morning sunrays by closing the eyes after instilling two drops of honey into the eyes.
2. **Eye wash:** With Triphala kashaya.
3. **Palming:** Rub the palms and place it over the closed eyes. It gives immense relaxation to the eyes and mind.
4. **Swinging:** Swinging body from left to right and back by relaxing the eyes without focusing on any object. The objects in front of you will start moving in the opposite direction. Swinging helps to relax the eyes and corrects the accommodative error.
5. **Eye ball movement exercises:** This can be done by moving the eyeball from extreme right to extreme left, or top to bottom without moving the head. The eyeball should be rotated clockwise and anticlockwise. This helps in strengthening the extra ocular muscles of the eye.
6. **Candle reading:** Reading the fine print in a dark room with the illumination of a candle. This stimulates the retinal cells to improve vision.

TRĀTAKA

'Trataka' is the term used in yoga for exercising the eye. In this eyes should be focused on any object or light of flame till there is watering from the eyes. Trataka helps in improving the neurological condition of eye, improves concentration and also relieves the burning sensation of the eyes.

Chapter

2B

- Classification of Netra Kriya Kalpas
- Akshi Tarpana, Putapāka
- Aśhotana, Seka, Anjana
- Bidālaka, Pindi
- Panchakarma in Netra Chikitsa

NETRA KRIYA KALPA

Netra kriyakalpas are special bahi-parimarjana chikitsa procedures adopted for treating ocular disorders. Panchakarma is the foundation for kayachikitsa, similarly netra kriyakalpas are the foundation for netra chikitsa. They are modulated to suit the structural peculiarities and different disease conditions of the eye. These local therapies are unique and each does their function in a different way.

क्रियाणां तर्पणपुटपाकादीनां कल्पनं करणं क्रियाकल्पः। (S.U.18/2, Dalhana)

Here, the word kriya means the special therapeutic procedure and kalpa means formulations like swarasa, ghrita kashaya etc.

Benefits of topical administration (kriyakalpa) over oral administration of drugs in ocular disorders

Topical administration (kriya kalpa)	Oral administration
The medicine will have direct action on the tissues.	There will be no direct action on the tissues.
The medicine will not undergo systemic digestion.	The medicines undergo systemic digestion.
The contact time between the tissue and the medicine can be monitored.	The tissue contact time of the drugs cannot be monitored.
The medicines can reach the target tissue more easily because of the direct contact	Difficult to cross blood-aqueous, blood-vitreous and blood-retinal barriers to reach target tissues.
The bioavailability of the drug is more	The bioavailability of the drug is comparatively less.

CLASSIFICATION OF KRIYAKALPAS

Charaka has explained three types of kriyakalpas. Sushruta and Vagbhata explained five types of kriyakalpas, but later on Sharangadhara has added two more to it and explained seven types of kriyakalpas. This shows the development of the kriyakalpa procedures.

Charaka	Sushruta and Vagbhata	Sharangadhara
1. Bidālaka	1. Sēka	1. Sēka
2. Aschōtana	2. Aschōtana	2. Aschōtana
3. Anjana	3. Anjana	3. Anjana
	4. Tarpana	4. Tarpana
	5. Putapāka	5. Putapāka
		6. Pindi
		7. Bidālaka

The kriyakalpas should be advocated judiciously by the apt selection of drugs, mode of preparation and mode of application.

AKSHI TARPANA

It is a procedure in which medicated ghee is kept over eyes for a specific period of time. It is also named as 'Netra basti'.

Indications

ताम्यत्वतिविशुष्कं यद्भूक्षं यच्चातिदारुणम् । शीर्णपक्ष्माविलं जिह्वं रोगविलापं च यद्भूक्षम् ॥
तदक्षि तर्पणादेवलभेतोर्जमसंशयम् ॥ (S.U.18/17-18)

Akshi tarpana is advised in the following disease conditions:

- Tamyati-** Darkness in front of eyes
- Ativishushkam-** Reduced lacrimation
- Atiruksha-** Dryness of eyes
- Atidaruna-** Roughness of the lids
- Sheerna pakshma-** Falling of eyelashes
- Avila-** Blurriness of vision
- Jihma-** Squint

According to Vagbhata the indications for Akshi Tarpana are

Stabdha (stiffness of eyes), Nimna (depressed eyes), Krichronmilana, Sirōtpāta, Sirāharsha, Arjuna, Shukra, Timira, Abhishyanda, Adhimanta, Anyatōvāta, Vātaparyaya and Shushkākshipāka.

Contraindications

दुर्दिनालुष्णाशीतिपुचिन्तायासप्रमेयं च । अशान्तोपद्रवे चाक्षिगतर्पणं न प्रशस्यते ॥ (S.U.18/18-19)

Durdina- Cloudy day

Atiushnasheeta- Too hot or too cold climate

Chinta- Grief

Aayāsa- Tiredness

Blurama- Giddiness

Ashantōpadraya- If complications won't subside

Tarpana is contraindicated if the climate is too hot, cold or cloudy, if the person is in grief, tired or suffering from giddiness and if complications of the disease won't subside.

Person who is not suitable for Nasya and Snehapana are contraindicated for tarpana and putapaka also. (S.U.18/19)

Tarpana vidhi

Purvakarman

- Patient is prepared by subjecting him to samshodhana karmas such as vama, virechana, nasya etc and is made to lie in supine position comfortably on a table. The room selected for the procedure should be devoid of sunlight, dust and heat.
- A uniform, smooth dough is prepared out of masha flour.
- Mild massage and warm fomentation is given to the part.
- Medicated ghee, towels, cotton swabs, vessels etc should be kept ready.
- The agni of the patient is assessed before subjecting him to pradhana karma.

Pradhana karma

- A firm circular frame of two angula height is constructed around the eyes with the dough of masha flour.

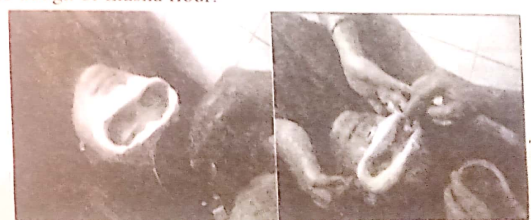

Fig. 2.1

- Then lukewarm ghrita or ghritamanda (supernatant part of ghee) is slowly poured on to the eyes till the eyelashes get immersed.
- Then the patient is asked to slowly blink the eyes (unmeelayet shanaihi).

Duration to retain the medicine

According to Sushruta

On the basis of dosha		On the basis of sthana	
Swastha	500 matra	Sandhi	300 matra
Kapha roga	600 matra	Vartma	100 matra
Pitta roga	800 matra	Shukla	500 matra
Vāta roga	1000 matra	Krishna	700 matra
		Sarvagata	1000 matra
		Drushti	800 matra

Paschāt Karma:

- After tarpana procedure the ghee is drained by making hole at the apānga sandhi in the paali and it is cleaned.
- Followed by mild fomentation with warm water or Yavapishiti
- Then dhoomapāna is given to expel the kapha caused by the ghee.
- Vagbhata mentions the use of luke warm water for mukha prakshalana after dhooma pana.
- Exposure to heat, open air and bright light should be avoided.

Duration of treatment

Dosha	Sushruta	Vagbhata	Videha
Vata	Daily	Daily	Daily
Pitta	Once in 3 days	Interval of 1 day	Interval of 1 day
Kapha	Once in 5 days	Interval of 2 days	Interval of 3 days
Rakta	–	–	Interval of 1 day
Sannipataja	–	–	Interval of 2 days
Swastha	–	Interval of 2 days	Interval of 2 days

Course of Tarpana as per Jejjata

Alpa dosha	- 1 day
Madhyama dosha	- 3 days
Adhika dosha	- 5 days

Additional points as per Vagbhata

1. Tarpana should be performed only when redness (raga), lacrimation (ashru), pain (shoola), swelling (samrambha) and discharge (dooshika) have subsided.
2. Along with māsha, flour of yava (barley) can also be used to construct the paali.
3. The height of paali should be two angulas.
4. Lukewarm ghee should be poured on closed eyes.
5. In case of nakṣāndhya, vātaja timira and krichronmīlana, vasā should be used instead of ghrita.

Samyak Tarpita lakshana

तर्पणे तुप्तिलिङ्गानिनेत्रस्येमानिलक्षयेत् । सुखस्वप्नावबोधत्वं वैशद्यं वर्णपाटवम् ॥
निर्वृतिर्व्याधिविध्वंसः क्रियालाघवेमेव च ॥ (S.U.18/12-13)

When tarpana is properly done following features are seen:

Sukhaswapna- Sound sleep

Avabhodatva- Pleasant awakening

Vaishadyam- Clarity of vision

Varnapātavam - Clear sense of colour or imparts natural colour to shukla and krishna mandala

Nivrittirvyadhidividvamsa- Relief from the disease

Kriya- Normal functioning of the eye (unmesha, nimesha)

Lāghavameva- Lightness of the eyes

Prakāsha kshamata- Tolerance to bright light. (Vagbhata)

Ati Tarpita lakshana:

गुर्वाविलमतिनिग्धमश्रुकण्डूपदेहवत् । ज्ञेयं दोषसमुत्क्राणं नेत्रमत्यर्थतर्पितम् ॥ (S.U.18/14)

When tarpana is done excessively the following lakshanas are seen:

- Guru-** Heaviness of eyes
- Avila-** Blurriness of vision
- Atisnigdha-** Sliminess in the eyes
- Ashru kandu upadehavat-** Excessive lacrimation, itching and discharge.
- Dosha utklishta-** Aggravation of doshas
- kapha janya vyadhis (Vagbhata)**

Heena Tarpita lakshana

ऋक्षमाविलमस्त्राद्यमसहं रूपदशनि । व्याधिवृद्धिश्चतज्जेयहीनतर्पितमक्षि च ॥ (S.U.18/15)

The heena tarpita lakshanas seen are as follows:

- Rūksha-** Dryness of eyes
- Avila-** Blurriness of vision
- Asradya-** Excessive lacrimation
- Asaham rūpadarshane-** Intolerance to light
- Vyādhivṛddhi-** Aggravation of the disease

Chikitsa for Ati and Heena tarpita

अनयोर्दोषबाहुल्यात् प्रयतेत चिकित्सिते । धूमनस्याङ्गनैः सेकेरुक्षैः स्निग्धैश्च योगवित् ॥ (S.U.18/16)

Dhūma, nasya, anjana and seka with ruksha dravyās are advised when there is excessive vitiation of kapha.

The same procedures are performed with snigdha dravyas in case of excessive vitiation of vata.

Commonly used ghritas for Tarpana

- Triphalādi ghrita
- Patolādi ghrita
- Shatāvaryādi ghrita
- Mahatriphalādi ghrita
- Jivantyādi ghrita

Tarpana is not done using taila, as taila is achakshushya.

PUTAPĀKA

Putapāka is one among the kriyakalpas which is usually done after tarpana. The procedure of putapaka is same as that of tarpana but method of preparation of medicine, ingredients and duration of treatment are different.

Indications and contraindications of Putapāka are same as that of Tarpana

Why putapaka after tarpana

The body becomes heavy and lazy/weak due to the consumption of unctuous food. Similarly eye also becomes heavy and weak after tarpana kriya (because of clogging of the srotas by ghrita). Hence to promote strength to the eyes putapāka is advised to be done after tarpana. (A.H. Su.24/12-13)

Preparation of putapaka rasa

Materials required

- 2 pala Mamsa (Approx 100gms)
- 1 pala Dravya (Approx 50gms)
- 8 pala Drava (Approx 400ml)

Method of preparation

- Initially the drugs are selected based on the type of putapaka to be prepared.
- Then a homogenous paste is made out of the drugs which is made into a bolus.
- The bolus is then wrapped with leaves of eranda, kashmari, kumuda, kamala or kadali based on the doshas.
- This bolus is again packed with mud and placed over fire till it becomes red hot. (woods used as fuel are khadira, kanaka, ashmantaka etc.)
- The cooked bolus is squeezed to extract the juice.
- The juice thus obtained is used for putapāka as 'putapāka rasa'.

Procedure

The procedure of putapaka is similar to that of tarpana.

Types of Putapāka

Sushruta (S.U.18/21)		Vagbhata (A.H.24/13)	
Type of Putapāka	Indications	Type of Putapāka	Indications
Snehana	Atirūksha netra	Snehana	Vāta
Lekhana	Atisnigdha netra	Lekhana	Kapha
Rōpana	In pitta, rakta, vāta and vranayuktha netra Also to improve vision	Prasādana	Pitta and Rakta

Duration of Putapāka (Su.U.18/23-26,28)

Putapāka	Duration	Matra kāla
Lekhana	1 day	100
Snehana	2 days	200
Rōpana	3 days	300

Dravyas used for Putapāka

Snehana Putapāka	Lekhana Putapāka	Ropana Putapāka	Prasadana Putapāka
Sneha, Ānūpa māmsa Vasā, Majja, Meda and Madhura aushadha.	Jāngala Māmsa, Yakrut, Shunti, Maricha, Pippali, Krishna loha churna, Tāmra, Shankha, Pravāla, Saindhava, Samudraphēna, kāśisa, Srōtōnjana, Dadhimastu Mukta and Haratala	Dugdha, Jāngala mamsa, Madhu, Ghrita, Tikta dravyas cooked in stanya.	Madhura dravya, Mruga pakshi yakrut, Majja, Vasā, Ghrita triturated with Stanya.

Samyak putapāka lakshana (Su.U. 18/31)

If putapaka is carried out properly the following lakshanas will be noticed in the individual.

- **Prasanna varna**- Clarity of vision
- **Vishada**- Clear appearance of eye
- **Vata atapasaha**- Tolerance to air and heat
- **Laghu**- Lightness of eyes
- **Sukhaswapna avabodhya**- Awakens after sound sleep

Putapāka Atiyoga lakshana (Su.U.18/31)

Putapaka if done in excess causes the following symptoms:

- Ruja (pain)
- Shopha (oedema)
- Pidaka (nodular swelling)
- Timira (blurriness of vision)

Putapāka ayōga lakshana (Su.U.18/31)

The ayoga lakshanas seen in an individual after putapaka are :

- Pāka (Inflammation)
- Ashru (Excessive lacrimation)
- Doshodgama (Recurrence of symptoms)

Chikitsa

In hīna and atiyoga of putapaka- Anjana, Aschōtana and Swedana are indicated based on the vitiation of the doshas.

Merits of Tarpana and Putapaka (Su.U.18/41)

Tarpana and putapaka if done properly will reduce dāha, shōpha, ruja, gharsha, srāva, kandu, upadēha (coating), dūshika (netramala) and raktha raji (congestion of blood vessels).

Complications of Tarpana and Putapaka

Procedure	Complications
Use of ati ushna and tikshna dravya	Dāha and pāka
Apluta (slow pouring of medicine) and use of sheetala dravya	Ashrustambha, Ruk, Gharsha (foreign body sensation).
Atimātra of dravya	Kashayatvam (muddy eyes), Sankōcha (constriction) Sphurana (throbbing sensation).
Heena mātra of dravya	Dosha utklesha (aggravation of doshas).

ASCHŌTANA

उन्मीलिते अक्षिण दक्ष मध्ये बिन्दुभिः द्वयङ्गुलात् हितम् । (Sha.Ut.13/12)

Aschōtana is a procedure in which medicine is instilled drop by drop into open eyes from a height of 2 angulas. This procedure can be compared to installation eye drops.

Indications of Aschótana

सर्वेषां अक्षि रोगाणां आदौ आश्रयोत्तमं हितम् । रुक् तोद कण्डू घर्ष अश्रु दाह राग निर्वहणम् ।। (A.H.Su.23/1)

First line of treatment for all types of netra roga is aschótana. It relieves symptoms such as ruk, tóda, kandu, gharsha (foreign body sensation), ashru (lacrimation), dāha (burning), rāga (redness), bheda, pāka and shophā (A.S.Su.32/2).

Aschótana vidhi (A.H.Su.23/2-3)

- The patient is made to lie down comfortably.
- The physician should open the eyelids of the patient and instill the medicine with his right hand.
- The medicine should be instilled in the kaneenika sandhi from a height of 2 angulas.
- After the completion of the procedure the eyes should be wiped with soft cotton or cloth.
- Mild fomentation with lukewarm water should be given to the eyes in vātaja and kaphaja conditions.
- According to Sharangaḍhara, eyes should be kept closed for 100 mātra kāla after instilling the drops.

Types and Dosage (Su.U.18/45)

1.	Snehana	10 drops
2.	Lékhaṇa	8 drops
3.	Rōpana	12 drops

Temperature of the medicine depending on the predominance of dosha (A.H.Su.23/2)

Vāta	Ushna
Kapha	Koshna
Pitta and Rakta	Sheeta

Netra Samanya and Vishishta Chikitsa-Kriya Kalpa**Indication and Time of administration of Aschótana**

Dosha	Kāla	Aschótana
Kaphaja	Purvahna	Lekhāna
Vātaja	Aparahna	Snehana
Raktaja and Pittaja	Madhyahna	Rōpana

Note: Aschótana is contraindicated at night. But is indicated in ruja kala (i.e. whenever there is manifestation of symptom).

Action of Aschótana (A.H.Su. 23/7)

The medicines instilled into the eyes enters into the srotāses of netra sandhi, shiras, ghrāna, mukha and expels out the malās.

Complications of Aschótana (A.H.Su.23/5-6)

Ati ushna and tīkshna	Ruk, rāga and drushti nāsha
Ati sheeta	Ništōda, stambha, vedana
Ati mātra	Gharsha, difficulty in opening of eyes
Hina mātra	Symptoms increases
Aparisṛuta (Without filtering)	Lacrimation, pain and irritation due to foreign particles.

Common drugs for Aschótana

Vātaja: Eranda mūla, jayanti, bṛihati, madhu, shigru and panchamūla boiled in water.

Pittaja: Pruthvika, dārvī, manjishta, lāksha and madhūka boiled in water along with sugar.

Kaphaja: Shunthi, triphala, musta, nimba and vāsa boiled in water.

Other yogas like Triphala kashāya, Drāksha kashaya, Sthanya, Dāru haridra kwatha, Dashamūla kashaya etc can be used based on the predominance of dosha.

SÉKA

सेकस्तु सूक्ष्म धाराभिः सर्वस्मिन् नयने हितः । मीलिताक्षस्य मर्त्यस्य प्रदेयः चतुर्ङ्गुलात् ।। (Sha.Ut.13/1-2)

Séka is the procedure of pouring thin stream of medicines very slowly on the closed eyes from a height of four angulas. It is also referred as Pariséka.

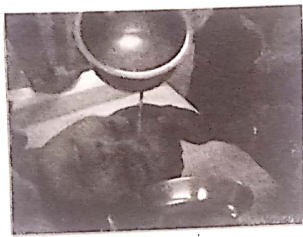

Fig. 2.2

Seka types	Indication	Mātra kāla	Preferred time
Snehana	Vataja	400	Evening
Lekhana	Kaphaja	200	Morning
Rōpana	Pittaja and raktaja	600	Afternoon

Note: Seka can also be done during manifestation of symptoms or till the disease subsides.

Samyak and mithya yoga lakshanas of séka are similar to Tarpana.

Commonly used Seka yogas:

Vātaja: Kashāya prepared from tvak, patra and moola of eranda with aja ksheera.

Pittaja: Kashaya prepared from shweta lodhra, yashtimadhu, chandana, prapoundarika and sāriva.

Kaphaja: Nimba, patōla, jātipatra, lōdhra dvaya, shunti.

Tridosha: Triphala kashāya.

ANJANA

The word 'Anjana' is derived from the root.

अनक्ति अनेन इति अञ्जन । That which spreads in the eye.

Anjana is a procedure of applying medicine into the inner aspect of lower eyelid. It is usually applied from kanīnika sandhi to apānga sandhi using a shalāka or fingertip. It is the most commonly practised procedure which not only helps in treating eye diseases but also in preventing them.

Pre requisites for Anjana procedure

- Patient should have undergone shodhana.
- The disease should be in the vyaktāvastha and localized only in the eyes.

Indications for Anjana

- Alpa shōpha
- Picchilata (unctuousness)
- Ashru srāva
- Ghana dushika (thick discharge).
- Kanḍu
- Maṇḍa gharsha (mild foreign body sensation)
- Rāga

Contraindications for Anjana

- Shrama - Exertion
- Udāvarta - Upward movement of vāta
- Rudita - Weeping
- Madya - Alcoholic
- Krōdha - Anger
- Bhaya - Fearful
- Jwara - Fever
- Vegāglāta - Suppression of natural urges
- Shirodosha - Diseases of head

Note: If Anjana is applied in the above said conditions it leads to complications such as rāga (redness of eyes), ruk (pain), timira (blurred vision), srāva (discharge), and samrambha (swelling).

Classification of Anjana

Based on action

Sushruta Samhita	Ashtānga Hridaya	Ashtānga Sangraha	Shārangadhara Samhita
1. Lekhana	1. Lekhana	1. Lekhana	1. Lekhana
2. Rōpana	2. Ropana	2. Rōpana	2. Rōpana
3. Prasādana	3. Prasādana	3. Prasādana	3. Snehana
		4. Snehana	

Based on kalpana of Anjana

Anjana kalpana	Indications
1. Gutikānjana	Mahabala of dosha (severe)
2. Rasakriyānjana	Madhyamabala of dosha (moderate)
3. Churnānjana	Hīna bala of dosha (less)

Dosage of Anjana (Su. U.18/58-59)

	Gutikanjana/Rasakriyānjana	Churnānjana
Lekhana	1 harenu mātra varti	2 shalāka
Prasādana	1½ harenu mātra varti	3 shalāka
Ropāna	2 harenu mātra varti	4 shalāka

- Harenu = size of a pea nut
- Shalāka= powder available on the tip of shalāka

Anjana Pātra and Shalāka

Anjana pātra (container) and the shalāka should possess similar qualities as that of anjana. It is usually prepared out of swarna, roudya, tāmra, mēsha shringi, vaidūrya and kāmśya.

Features of Shalāka

- Anjana shalāka is a rod like instrument of 8 angulas in length made of swarna, roudya etc.
- It is thin in the middle and rounded at both the edges similar to flower bud of jasmine (mukulākara).
- It should be smooth and easy for handling.
- It should not be rough, thin, hard or breakable.

Shalāka based on action

Rōpana	Louha shalāka or anguli
Lēkhana	Tāmra shalāka
Prasādana	Suvarna or rajata shalāka

Method of administration of Anjana

- The patient is made to sit comfortably and the lids are retracted.
- Anjana shalāka filled with anjana is held in the right hand of the physician and applied uniformly from kanīnika sandhi to apānga sandhi in the left eye of the patient and vice versa.
- The patient is then asked to close the eyes and rotate the eye ball, so that uniform distribution of the medicine takes place.

- The excess anjana should be wiped out with a soft and clean cloth.
- Care should be taken not to apply anjana excessively either in kanīnika or apānga sandhi as it may cause injury.
- Eyes should be washed only when discharges and doshas drain out completely from the eyes. Immediate washing of eyes causes recurrence of the disease or damage to vision.

Anjana Nishiddha kala (A.H.Su 23/16-17)

Contraindications of Anjana are as follows:

- Nishi - Night
- Swapna - During sleep
- Madhyahna - Noon
- Mlāna - Fatigued eyes
- Ushna gabhastibhiti - Extreme heat.




Fig. 2.3

If anjana is applied during above conditions the doshas liquify and aggravate to produce severe eye diseases.

Application of Anjana is to be done during morning or evening to manage the above said complications.

1. Lēkhanānjana

Lēkhanānjana is used to expel out the doshas from netra. It is prepared from tūkshna, kshāra and all rasa dravyās except madhura.

Indications

- Savrana shukra • Avrana shukra • Arma

Samyak yoga of lekhanānjana (Su.U.18/75-76)

If lekhanana anjana is applied properly the following features are seen:

- Vishada - Clarity
- Laghu - Lightness
- Anasrāvi - Free from discharge
- Kriyāpatu - Normal functioning of eyes
- Sunirmala - Clear eyes
- Shānta upadrava- Pacification of all the complications.

Atiyoga lakshana of lekhanānjana

Excess application of lekhanānjana leads to:

- Jihma - Squint
- Dārūna - Hardness of lids
- Durvarna - Discolouration
- Srastam - Drooping of eyelid
- Ateeva ruksha - Severe dryness
- Syandate - Severe discharge

According to Vagbhata atiyoga of lekhanānjana causes santāpa, nistōda, shoola i.e. pricking pain, stambha, gharsha, ashru, difficulty in opening eyes and headache.

Chikitsa for atiyoga of lekhanānjana

- Vātahara and santarpana chikitsa.
- Aschōtana and pratyānjana with sheetala dravyās.

Hinayoga lakshana of lekhanānjana

Insufficient use of lekhanānjana will lead to aggravation of the doshas and produce severe disease.

Chikitsa for Hinayoga of lekhanānjana

This condition can be treated by dhooma, nasya and teekshnānjana. These procedures expel out the aggravated dosha.

2. Prasādanānjana

This anjana is prepared using madhura and sneha dravyas. Hence it brings about snehana (unctuousness) and prasādana (soothing) of eyes. According to Ashtanga Hridaya it is subdivided into:

1. Snehana anjana and
2. Prasādana anjana

Snehana anjana is prepared from sarpi and vasā.

Prasādanānjana is prepared from madhura, sheeta and snigdha dravyās. Prasādanānjana is to be applied after the administration of tīkshna or lekhaṇa anjana. It soothes the eye and relieves the irritation caused by ruksha and tīkshna properties of lekhanānjana.

Samyak yoga lakshana of prasādanānjana

Proper application of prasādanānjana imparts unctuousness, normal colour and strength to the eyes. The eyes will be pleasant, devoid of doshās and regains its normal functions.

Atiyoga of prasādanānjana

Atiyoga of prasādanānjana is similar to that of atiyoga of tarpana. It is managed using rūksha and mrudu oushadi.

Ayoga of Prasādanānjana

Ayoga, doesn't produce any discomfort to the eyes. But it has no action in relieving the symptoms. Hence anjana should be applied in proper mātra.

3. Ropanānjana

Ropanānjana is prepared using kashāya, tikta and sneha dravyas. It restores normal colour to the eye, improves vision and strengthens the eye.

Samyak, ati and hinayoga lakshana of ropanānjana

Samyak, ati and heena yoga lakshanas of ropanānjana are similar to prasādanānjana and can be managed accordingly.

Pratyānjana

The anjana indicated to counter the complications caused due to the improper administration of anjana is called 'Pratyānjana'.

BIDĀLAKA

बिडालको बहिलेको नेत्रे पक्ष्म विवर्जितः । (Sh.Ut.13/30)

Application of medicinal paste over the eyelids excluding the eyelashes is called Bidālaka.

Thickness of Bidālaka is same as that of Mukhālepa.

Lepa	Thickness of the lepa
Doshagṇa	4 angulās
Vishagṇa	2 angulās
Varnya	1/2 angulā

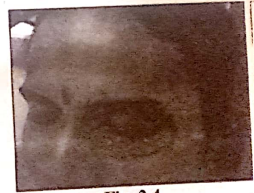


Fig. 2.4

Time of application

It can be applied during day or whenever the symptoms manifest.

Indications (Cha. Chu. 26/231)

- Dāha - Burning sensation
- Upadēha - Discharges
- Ashru - Lacrimation
- Shopha - Oedema
- Rāga - Congestion

Contraindications: It should not be applied at night.

Contraindications after applying the paste are speaking, laughing or crying excessively, being in grief or anger, exposing to sunlight and sleeping during day.

Commonly used Bidālaka yogas

1. Paste of yashtimadhu, gairika, saindhava, dāruharidra and rasānjana with water.
2. Paste of rasānjana.
3. Paste of haritaki and shunthi
4. Paste of kumāri and haridra.
5. Paste of lodhra and saindhava.

PINDI

This is mentioned only by Sharangadhara.

पिण्डी कवलिका प्रोक्ता बध्यते पट्टवस्त्रकैः १ (Sha. Ut. 13/21)

Pindi is modification of bidālaka. In this paste of medicines are covered in a cloth and placed over the closed eyes. It is also called as 'Kavalika'.

Indications

- Abhishyanda
- Early stages of netra roga

Commonly used yogas in pindi

- Paste prepared with patra, moola and tvak of eraṇḍa in vātaja conditions.
- Paste of yashti, amalaki or mahanimba phala in pittaja conditions.

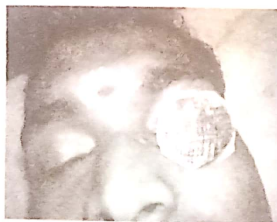

Fig. 2.5

- Paste of Shigru leaves in kaphaja conditions.
- Paste of triphala in kapha pitta conditions.
- Pindi can also be done with shigru patra, āmra pallava, brungarāja, bhūmyāmalaki, nimba, lajjālu, bilwā, kumāri etc in combination or alone, depending on the disease condition.

Avaguntana

This procedure is mentioned only in Ashtanga Hridaya & Sangraha.

संचूर्णं वस्त्रं बद्धं प्रकुपितमात्रे अवगुण्ठनं नेत्रे १ (A.H.U.16/5)

Avaguntana is a procedure in which powders of the drugs are tied in a cloth and used in netra roga.

PANCHAKARMA IN NETRA CHIKITSA

Since eye is a part of the body, most of the systemic disorders have their manifestation in the eyes. The Kriyakalpas are just local therapeutic measures to alleviate doshas present in the eye, where as Panchakarma does the shodhana of the complete body. Hence Panchakarma plays a very important role in the management of eye disorders.

1. Vamana (A.S.U.12/6-13)

Vamana has limited scope in the management of netra rogas. The few indications are:

- Pakshma shaata
- Lagana
- Pilla roga (A.S.U. 20/9)
- Kaphotkliṣṭha
- Kukkunaka

It is contra indicated in Drushtigata rogas. (Su.Chi. 33/14)

2. Viréhana:

- It is the most preferred shodhana karma in eye diseases and it imparts strength to all indriyas.
- It is indicated in akshipāka, kācha, timira and abhishyanda (Su. Chi. 33/32)
- It is also indicated in diseases like netra dāha, netrasrāva and timira (C. Si. 2/13)
- While describing samanya chikitsa for timira, the drugs for virechana are selected based on predominance of dosha. (S.U. 17/29).

- (a) Eranda taila with milk- Vataja
- (b) Triphala ghruta- Pittaja and raktaja
- (c) Trivrit ghruta- Kaphaja
- (d) Taila prepared with tridosahara drugs- Sannipātaja

- Virechana is indicated as **purva karma in kriyakalpas** (like tarpana and anjana) and shastra karmas (arma cheda and pakshma kopa chikitsa).
- Virēchana is indicated **after sirāmokshana in pilla roga**. (A.S.U. 20/9)

3. Basti: (C.Si.2/16)

It is indicated in all conditions where vitiated vayu gets lodged in head and causes eye disease. Basti is helpful in improving vision (chakshushya basti) and in the treatment of Krichromīlana. (A.S.U.12/2)

4. Nasyakarma

- Snehana nasya helps in improving vision.
- Nasya is indicated in timira, shukra (savṛana and avṛana), vartma roga and other akshī rogās. (C Si.2/22).
- Snaihika nasya is indicated in vātaja abhishyanda.
- Anutaila nasya is indicated in shushkākshi pāka. (S U.10/14) and in vātaja timira (S.U.15/33)
- Nasya is also indicated in shushkākshi pāka, pakshma shāta, kaphōtklishta vartma, adhimantha, hatādhimantha, amlatōvāta, amladyushita, dhūmadarshi, timira, kācha, lingānāsha (A.S.)

5. Raktamokshana

It is an important parasurgical procedure. Sirāvyadha and jaloukāvacharana are commonly indicated procedures in eye disorders.

Some of the references of Raktamokshana are as follows:

- Puyālasa, complications of arma and savṛana shukra (A.S.U. 14/4,13,18)
- Pittaja, raktaja and kaphaja timira (A.S.U.16/18)
- Vātaja, pittaja, kaphaja and raktaja abhishyanda (A.S.U.19/10,32)
- Pilla roga (A.S.U.20/9).
- In pōthakī, jaloukāvacharana is recommended (A.S.U.12/8)

Chapter

2C

- Chédya, Bédhya, Lékhyā, Védya Vyadhis of Netra • Trividha karma
- Vrana Shotha
- Vranabandhana
- Pranashta Shalya
- Rakshākarma (Sterilization)

BASIC FUNDAMENTALS OF NETRA SHASTRA CHIKITSA

Based on chikitsa, netra rogas are classified under four headings.

1. Shastrasādhya
2. Aushadhasādhya
3. Yāpya
4. Asādhya

Ashta vidha shastrakarmas are Chédana, Bhédana, Lékhana, Vyadhana, Ēshana, Āharana, Visrāvana and Seevana. Out of these only the first four are usually indicated in Netra roga.

Shastrasādhya vyadhis of Netra are further classified as:-

1. Chédya vyādhis
2. Bhédya vyādhis
3. Lékhyā vyādhis
4. Védhyā vyādhis

1. Chédana (Excision)

Indication:

5 types of Arma, Arsho varthma, Shushkārsha, Arbuda, Sirā pidaka, Sirājāla and Parvanika. (Su.U.8/6).

Instruments:

Mandalāgra, Karapatra, Vriddhi patra, Nakha shastra, Mudrika, Kartari, Utpala patra, Antarmukha.

2. Lékhana (Scraping)

Indications: Utsangini, Bahalavartma, Kardama vartma, Shyāva vartma, Vartma sharkara, Klisha vartma, Vartmāvabandha, Pothaki, Kumbhika. (Su.U.8/7).

Instruments: Mandalāgra, Kharapatra, Vriddhi patra, Nakha shastra.

Gojihwa, Shephālika patra.

3. Bhédana (Incision)

Indication: Lagana, Bisavartma, Krimigranthi, Anjananāmika, Upanāha. (Su.U.8/8)

Instruments:

Vṛuddhipatra, Nakhashastra, Mudrika, Utpalapatra, Ardhadhara, Antarmukha, Kushapatra.

4. Vyadhana (Puncturing)

Indications:

Sirotpāta, Srāharsha, Sashopha akshi paka, Ashopha akshipaka, Anyatōvāta, Pūyalasa, Vatapatyaya, 4 types of Adhimantha and 4 types of Abhishyanda.

Instruments: Suśi, Kutharika, Vrihimukha, Āra, Vetasapatra, Eṣani, Līnganāśa vedhini shalāka, kusapatra.

TRIVIDHIA KARMA

1. Poorva karma (pre-surgical)

- Select an ideal auspicious day, time and place for shastra karma.
- Instruments and equipments needed for the surgery like yantra, shastra, kshāra, agni, shalāka, shṛunga, jalōka, alābu, jambvoshta, pichu, sūtra, madhu, ghrita etc should be kept ready.
- Attendant should be compassionate, strong and steady.
- Vaidya should be enriched with knowledge, bold and confident.
- Diet is advised based on diseased condition.

2. Pradhāna karma (surgical)

- Patient is made to face east direction and Vaidya should face the patient.
- Surgery should be conducted by taking care not to injure the vital points such as marma, asthi, sandhi etc.
- Incision should be made along the direction of the hair in one stroke.
- In the eyebrows and eyelid, incision should be oblique.
- An ideal incision is that which creates a uniform wound without damaging the surrounding structures.

3. Paschat karma (post surgical)

- Prakshālana of the wound is done using specified kashāyas.
- Fumigation is done with guggulu, agaru, sarjarasa, vacha, sarshapa, nimbapatra and ghrita.
- Then the wound is bandaged.

VṚANA SHOPHA

शोफसमुत्पन्ना ग्रन्थिविद्वलजीप्रभृतयः प्रायेण व्याधयोऽभिहिता अनेकाकृतयः, तैर्विलक्षणः पृथुर्ग्रथितः समो विषयो वा त्वङ्मांसस्थायी दोषसङ्घातः शरीरेकदेशोत्थितः शोफ इत्युच्यते । (S.Su.17/3)

Vrana shopha is a thick swelling localized in twak and mamsa caused due to the vitiation of dosha. It may be even or uneven, having different features and shapes and looks similar to granthi, vidradhi or alaji.

Features of vranashopha: It can be understood in 3 stages :

a) Amāvastha (S.Su. 17/5)

In Amāvastha the shopha will have mild temperature, pain and inflammation. It is firm, cold and has color similar to the surrounding tissue.

b) Pachyamānāvastha (S.Su.17/5)

In this stage the features of pain are similar to as though pricked by needles, bitten by ants, excised by instruments, hit by stick, pressed by palm, squeezed by finger, burnt by agni/kshāra or as bitten by scorpion.

Patient does not find comfort in any position (sitting/standing/sleeping).

Swelling is associated with oedema, discoloration and burning sensation. Fever, thirst and anorexia may also be present.

c) Pakvāvastha (S.Su. 17/5)

- Pain and swelling reduces.
- The skin looks pale, wrinkled and cracked.
- Pitting type of oedema which fluctuates on applying pressure due to accumulation of pus.
- Recurrent pricking pain and itching.
- Appetite improves and complications subside.

PRANASHTA SHALYA

When the shalya is present in the body, following features are seen:

- Shyāva pidakas
- Shópha
- Védana
- Shónitha srāva
- Unnatam mrudu mamsa (elevated and soft tissue)

Vishesha lakshana based on location of Shalya in different Vrana Vastu

1. **Twakgata:** Appearance of discoloured, hard and diffused swelling.
2. **Māmsagata:** Enlarged suppurative tender swelling, associated with burning sensation.
3. **Sirāgata:** Dilated and engorged veins associated with pain.
4. **Snāyugata:** Painful swelling at the site of snāyu.
5. **Srótógata:** Impairment in the normal functions of the srōtas.
6. **Dhamanigata:** Frothy blood oozes out from the dhamani. Associated symptoms are bodyache, thirst and nausea.
7. **Asthigata:** Different types of pain with swelling.
8. **Asthi vivaragata:** Fullness of bone, pricking pain and horripilations.
9. **Sandhigata:** Symptoms similar to asthigata shalya.
10. **Maramagata:** Similar to marma viddha lakshana.

Management of Pranashta Shalya

- Natural expulsion of shalya takes place on lacrimation, sneezing, belching, coughing etc. (eg. foreign particles in eye are removed on lacrimation).
- Small sized shalya present in the eyes can be removed by parisechana (washing), ādhmāpana (blowing), pramānjana (wiping with cloth or fingers).

VRANABANDHANA

Bandages which can be applied in netra and jatrūrdhva are:

1. **Swastika bandha** advocated in bhru, karna
2. **Cheena bandha** is done in apanga sandhi.
3. **Vitana bandha** is done in murdha.
4. **Panchangi bandha** is done in jatrūrdhwa.

RAKSHAKARMA (Sterilization methods in Ayurveda)

Religious practices like homa, yajna etc. were regularly conducted during ancient period. These practices not only helped in invoking the blessings of gods, but also purified the places where they were conducted.

Achārya Sushruta has mentioned Rakshākarma as one among the Shashti upakramās for the management of vrana.

निशाचरेभ्यो रक्ष्यन्तु नित्यमेव क्षतातुरः। रक्षाविधानैर्नर्द्धिष्टैर्यमैः सनियमैस्तथा ॥ (Su Chi. 1/133)

In Ashtanga sangraha, we find description of dhoopana as a procedure for Rakshāvidhi. Kāshyapa also mentions about dhoopana with drugs mentioned in vrana chikitsa to be done in sootikāgāra. This is probably to keep the mother and newborn baby healthy. He has also advised different types of dhoopana in garbhāvastha. Dhoopana of bed, clothes, chair etc articles are also mentioned. Sushruta describes about aseptic measures to be adopted before any surgical procedure like heating of instruments to red hot, probably to prevent the infection.

Charaka describes about dhoopana to be conducted in shastrakarma ghāra by the fumes emitted on sprinkling the powders of mayurapuecha, jatamamsi etc.

Drugs like haridra, nimba, sarshapa, ghrita, guggulu, agaru, sarja rasa, lavana, hingu, vacha, sandhava, tuttha are some of the drugs used for dhoopana.

STERILIZATION

The introduction of 'antisepsis' changed the science of surgery from infection and death to one of relieved suffering and prolonged life. Maintenance of asepsis is important to ensure safe surgery and to minimize post operative infections.

Sterilization: It is the process that eliminates or kills all forms of life including transmissible agents such as fungi, bacteria, virus, spore forms etc. Sterilization can be achieved by applying heat, chemicals, irradiation, high pressure and filtration.

Disinfection: It is destruction of infectious agents outside the body by direct exposure to physical or chemical agent to prevent the spread of infectious diseases. Disinfectants are generally used in surfaces or to clean instruments.

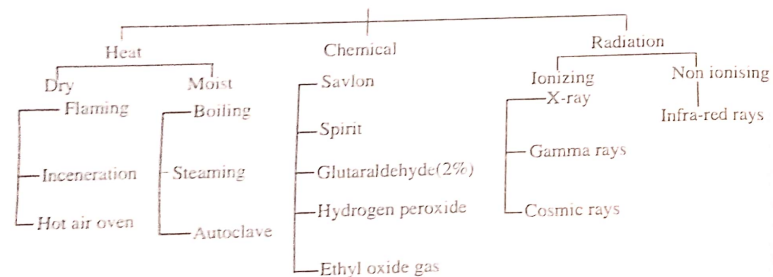
Antiseptic: This implies a substance that prevents growth or action of micro organisms either by inhibiting their activity or in destroying them. It's role is generally seen on living tissue.

Asepsis: The concept of asepsis includes prevention of wound contamination by using sterile material and minimizing airborne transmission.

Aseptic practices include:

- Proper preparation of the patient.
- Hand washing
- Surgical hand scrub
- Using materials such as gloves and surgical attire.
- Maintaining safe environment during surgery.

Sterilization methods



Fumigation of operation theatre

Disinfection of the operating room by exposure to fumes of a disinfectant is referred to as fumigation. Formaldehyde is an effective agent commonly used to sterilize the operating room.

Chapter

2D

- Ashta Vidha Shastra Karma

- Agni Karma

- Rakta Mokshana

- Kshāra Karma

ASHTAVIDHA SHASTRA KARMA

The eight types of shastra karma are Chedana, Bhédana, Lékhana, Vyadhana, Eshana, Visrāvana, Aharana and Seevana. Among these the first four are included in netra chikitsa by our Achāryas.

1. Chédya Roga

Chédya rogas are: five types of Arma, Arsho varthma, Shushkārsha, Arbuda, Sirājāla and Sirāpidaka.

Chédana karma is the surgical procedure indicated in the above diseases. In this any affected extra growth is excised.

Pūrva karma for Chédana karma

- Samshódhana karma and samsarjana karma should be followed before Chédana.
- Snigdha anna is given to the patient.

Pradhāna karma

a) Arma (S.U. 15/4-9)

- The arma is softened by rubbing it with saindhava lavana.
- Then swedana is done to bring about wrinkle and free movement of the arma.
- The wrinkle is held with the badisha and muchundi yantra-while the patient looks laterally (to the apanga side).
- Using mandalagra shastra, lekhana (scraping) of the arma is done to separate it from krishna and shukla mandala till kaneenika sandhi. Then the arma is excised using the shastra by leaving behind medial 1/4th part of arma. Over excision (very close to kaninika sandhi) leads to nadi vṛana (sinus) and if excision is not done sufficiently the arma regrows.

11 S.T.-I

© 2006 Blackwell Publishing Ltd *Journal of Internal Medicine* 260: 105–114

1111

●

- **Abstract**

1000-0000

1

- 10

- If it doesn't burst open, bhédana with shastra is done followed by pratisarana using rasānjana and madhu.

e) Upanāha:

- Bhédana is done using shastra.
- This is followed by lekhana with mandalāgra shastra followed by pracchana and pratisarana using pippali, madhu and saindhava.

Paschat karma

- Vranavat chikitsa should be done.

3. Lekhya Roga

Lekhya rogas are Kumbhika, Sharkara, Uṣangini, Shyāva vartma, Kardama vartma, Vartmāvabandha, Klišhta vartma, Bahalavartma and Póthaki.

Lekhana karma is the surgical procedure indicated for the above said diseases. Here the affected part is scrapped using shastra.

Pūrva karma

- Patient should be subjected to snehana, swedana, vamaṇa and virechana for shareera shodhana.
- He is made to lie in supine position in a room devoid of wind and sunlight.
- Eyelid is fomented and is firmly held with left thumb and forefinger to restrict the lid movements.

Pradhana Karma (S.U.13/3-8)

- In kumbhika, sharkara, uṣangini, shyāva vartma and kardama vartma scraping is performed with the help of shastra or patra.
 - In vartmāvabandha, klišhta vartma, bahalavartma and pothaki, pracchana is done followed by lekhana with shastra.
- If the pidakas are small, hard and coppery they are allowed to undergo paka before bhédana and lekhana procedures.

Paschat Karma

- Once the bleeding stops, swedana is advised.
- Pratisārana with fine powders of manashila, kāśisa, vyósha, rasānjana, saindhava and madhu.

- Prakshālana with warm water and ghee.
- Finally vranavat chikitsa.

Samyak Lekhita lakshana (S.U.13/9)

Proper scraping shows the following features :

- Absence of bleeding, discharge, itching and swelling.
- The scraped surface appears even, similar to nakha.

Durlikhita lakshana (S.U.13/10-12)

Improper scraping shows the following features :

- Redness of eyes, discharge from the site of scraping, swelling and blurring of vision.
- Bluish discolouration, heaviness, stiffness, itching and stickiness of eyelids along with increased inflammation.

Chikitsa: Snehana followed by lekhana.

Atilikhita lakshana (S.U.13/13)

Excessive scraping leads to eversion of eyelid, loss of eyelashes, pain, excessive discharge and bleeding.

Chikitsa

- Snehana, swedana and vātahara chikitsa
- Followed by vranavat chikitsa.

4. Védhya Roga

Védhya rogas in netra are sirótpāta, sirāharsha, sashópha akshi pāka, ashópha akshipāka, anyatóvāta, pūyalasa, vātaparyaya, 4 types of adhimāṇṭha and 4 types of abhishyanda.

Purvakarma

- Dravānnapana/yavāgupāna/sarpi pāna.
- Followed by snehana (abhyanga) and swedana.

Pradhana karma

An auspicious day, which is neither too hot, cold nor cloudy is selected. The patient is made to sit in a room devoid of wind, facing the sun. He is made to sit with hip and

knee flexed resting the elbow over the knee joints and placing the closed fist over the lateral aspect of the neck. A bandage is tied around the fist and neck. A knot is put behind the neck which is neither too tight nor too loose. The patient is then asked to close the mouth and blow. The sira which has to be punctured should be made prominent by tapping with middle finger. Kutarika shastra is placed over the sira and tapped with middle finger to puncture it. The blood starts oozing out as soon as it is punctured.

Paschat karma

When the bleeding stops, the site of puncture is pressed with thumb and the bandage is removed slowly. Then cotton dipped in taila is placed at the site of puncture and bandaged.

Patient is advised to take light and easily digestible food which is neither too hot nor too cold.

Site of Sirāvyadha in netra rogas (S.U.9/3-4 videha)

- 1) Aupanāsika sira
- 2) Lalāta sira
- 3) Apāṅga.

Indications of Sirāvyadha

- Pūyālasa, complications of arma, savṛṇa shukra (A.S.U.14/4,13,18)
- Pittaja, raktaja and kaphaja timira (A.S.U.16/18)
- Pilla rōga (A.S.U.20/9)

RAKTA MOKSHANA

Raktamókshana is a method of blood letting. It is considered to be one of the shodhana karma by Sushruta.

Types of Raktamókshana

I. Shastrakṛta: Pracchana and Sirāvyadha

II. Ashastrakṛta:

- a. Jalōuka (in pittaja vikāra)
- c. Alābu (in kaphaja vikāra)
- b. Shṛṅga (in vātaja vikāra)
- d. Ghati yātra

Indications of Raktamokshana in Netra roga

- Póthaki- Jaloukavacharana is recommended (A.S.U.12/8)
- Vranashukla- Sirāvyadha and jaloukāvacharana

- Pūyālasa- Sirāvyadha.
- Pittaja and kaphaja timira- Sirāvyadha.
- Vātaja, pittaja and kaphaja abhishyanda- Sirāvyadha.
- Raktabhishyanda- Sirāvyadha or Jalōukāvacharana.
- Pilla roga- Sirāvyadha.

AGNI KARMA

Agni karma is a therapeutic procedure performed using fire or hot instruments.

Importance of Agnikarma:

क्षारादग्निः गरीयान् क्रियासु व्याख्यातः, तत् दग्धानां रोगाणां अपुनर्भावात् भेषजशस्त्रक्षारैः असाध्यानां तत् साध्यत्वात् च ॥ (Su.Su.12/3)

Agnikarma is considered as most superior because the diseases which cannot be managed by medicines, surgery or kshāra karma can be effectively managed by Agnikarma.

Types of Agnikarma	Samyak Dagdha Lakshana
Twak dagdha	Shabdha prādurbhava (production of sound), dourgandha (foul smell), twak sankocha (constriction of skin).
Māmsa dagdha	Kapōta varnata (colour of pigeon), alpa shvayathu (mild swelling), alpa vēdhana (mild pain), shushka (dry), sankuchita (constriction).
Sirā snāyu dagdha	Krishna unnata varnata (black and raised), sravasanni-rodhascha (cessation of discharge).
Sandhi asthi dagdha	Ruksha (dry), arunata (reddish brown), karkasha (rough), sthira (firm).

Commonly used materials or equipments for Agnikarma

Shalāka, Pippali, Jambvóshta, Madhu, Madhuchista, Gudā, Mudga, Taila, Ghrita, Ajāshakrit, Gōdanta.

Pūrvakarma

- Patient fit for agnikarma is selected and is made to consume cold and unctuous food.

- Necessary equipments or materials needed for agnikarma should be kept ready.

Pradhāna karma

Depending on the site where agnikarma has to be performed, material that is selected is heated to red hot and placed over the site till samyak dagdha lakshanas are seen.

Paschāt karma

- To promote healing of the wound, paste of madhu and ghruta is applied on the cauterised site.
- Complications if any should be attended accordingly.

Indications of Agnikarma in Netra rogas

Netra roga	Indications
Vartmagata rogas	Krichronmila, Lagana, Arbuda, Bisa vartma, Shlishhta vartma, Paksmakōpa and Pakshmoparodha
Sandhigata rogas	Puyālasa and Alaji
Sarvagata rogas	Vātaja Adhimantha and Abhishyanda

KSHĀRAKARMA

Definition of Kshāra

तत्र क्षरणात् क्षणनाद्वा क्षारः । (Su.Su.11/4)

Kshāra is defined as that which destroys and removes the vitiated or unhealthy tissues.

Importance of kshāra

शस्त्रानुशास्त्रेभ्यः क्षारः प्रधानतमः छेदभेदलेख्यकरणात्त्रिदोषघ्नत्वात् विशेष क्रियावचारात् च ॥ (Su.Su.11/3)

Kshāra is considered as more important than shastra or anushastra. It can bring about surgical effects like incision, excision and scraping. It also helps in pacifying the vitiated tridoshas and can also be used in special therapeutic procedures.

Kshāra karma

Any parasurgical procedure performed by using kshāra is called kshāra karma.

Indications of kshāra karma in Netra vartma rogas

Lagana, Arsho vartma, Shushka arshas, Vartma arbuda, Pakshmakōpa and Upapakshmamaala.

Kshāra used in Netra rogas

Yavakshāra, Tuttha, Vibhītaki kshāra, Gunja kshāra.

Chapter

2E

- Drugs used for ocular infections
- Drugs used for allergic conditions
- Anti glaucoma drugs
- Essential diagnostic pharmacological agents in Netra Chikitsa
- Drugs used for ocular inflammations
- Anti cataract drugs
- Dry Eye medications

ESSENTIAL THERAPEUTIC MODERN PHARMACOLOGICAL AGENTS

Ocular drug delivery is often challenging because of its anatomical location and presence of external guarding system. Drugs may enter the ocular tissue via anterior or posterior routes. The entry through anterior route is important for the treatment of diseases of anterior segment. The delivery of drugs to the posterior segment is often difficult because of the presence of blood-retinal barrier which restricts the entry of drugs from the systemic circulation into the posterior tissues such as retina and vitreous.

Drugs used for ocular infections

- Antibacterial agents
- Antifungal agents
- Antiviral agents
- Anti acanthamoeba formulations

Antibacterial agents

Several antibacterial agents are formulated for topical use in various ocular infections:

- Aminoglycosides eg. Gentamycin and Tobramycin
- Fluroquinolones eg. Ciprofloxacin, Ofloxacin, Levofloxacin
- Macrolides eg. Erythromycin
- Sulfonamides eg. Sulfacetamide
- Others eg. Chloromphenicol

Antifungal agents

Fungal infections are serious, sight threatening conditions which warrants prompt diagnosis for effective treatment. The management of fungal infections poses a great

challenge to the physician. Ophthalmic indications for antifungal medications include fungal keratitis, scleritis, endophthalmitis, canaliculitis etc. They are broadly classified into-

- Polyene antifungals: Amphotericin, Natamycin.
- Azole antifungals: Fluconazole, Otriconazole, Voriconazole.

Antiviral

Viruses are obligatory intracellular organisms and their replication is dependent on the host's mechanism. Viral infections are a significant cause of ocular morbidity. Therefore, there is an obvious need for efficient prevention and treatment of ocular viral diseases. The available antiviral drugs are:

- Acyclovir
- Valacyclovir
- Famacyclovir
- Trifluridine

Anti acanthamoeba formulation

Acanthamoeba represents micro organisms which occur worldwide and a genus of amoeba. They provoke keratitis, which is very often severely progressive disease occurring in contact lens wearers. Commercially available anti acanthamoeba formulations are:

- Hydrogen peroxide
- Benzalkonium chloride

Drugs used for ocular inflammation

The pharmacological approach for the management of ocular inflammation involves administration of anti-inflammatory agents after the recognition of anti inflammatory activity of adreno cortico extracts. Early use of various systemic and topical cortico steroids started, followed by the advent of non-steroidal anti inflammatory drugs (NSAID'S) for controlling various inflammatory conditions of eye. Corticosteroids are used as main stay in treatment of ocular inflammations. However, their use is limited due to serious side effects.

Steroid anti inflammatory drugs are: Prednisolone, dexamethasone, fluometholone etc.

Non steroidal drugs: NSAID'S have proven to be safe and effective alternate to corticosteroids in the management of ocular inflammations. They are:

- Aspirin
- Diclofenac
- Indomethacin
- Naproxen etc.

Drugs used for Allergic conditions

Ocular allergy refers to a variety of hypersensitive disorders that affects lid, conjunctiva and/or cornea. They are commonly associated with immune mediated inflammatory reactions. Currently available topical drugs for allergic conjunctivitis are classified as follows:

Classification	Drugs
1. Vasoconstrictors	Naphazoline
2. Anti histamines	Pheniramine, Antazoline etc
3. Mast cell stabilizer	Chromplyn sodium, Nedocromil etc
4. Dual action anti allergic drugs	Olopatidine, epinastine etc
5. NSAID'S	Ketorolac
6. Corticosteroids	Fluomethalone, dexamethazone, prednisolone

Anti cataract drugs

The anti cataract agents claim to be effective and is broadly classified into following categories:

- Aldose reductase inhibitors
- Non steroidal anti inflammatory drugs
- Vitamins, minerals and antioxidants
- Agents acting on glutathione and miscellaneous agents

Anti Glaucoma drugs

Glaucoma is one of the leading cause of blindness in the world. Current therapy for chronic treatment of glaucoma includes:

- Beta blockers
- Prostaglandin analogues
- Adrenergic receptor agonists etc

Dry eye medications

The goals of dry eye treatment are to improve tear film quantity, stability and reverse ocular surface damage. The agents which are available for the treatment of dry eye are classified as:

- Tear substitutes and autologous serum.
- Anti inflammatory agents: Topical corticosteroid, topical cyclosporin, oral tetracyclines and topical NSAID's.
- Secretagogues: Cholinergic agents and mucin inducers.
- Nutritional supplements, essential fatty acids omega-3 fatty acids, omega-6-fatty acids, topical retinol.
- Hormonal therapy-topical estrogen and androgen.

Essential diagnostic modern pharmacological agents required in Netra Chikitsa

Ophthalmic dyes

1. Fluorescein sodium

- Fluorescein reveals epithelial defects of cornea, conjunctiva and aqueous humour leakage that may occur after trauma or ocular surgery.
- Used to determine the patency of nasolacrimal system.
- Used in the procedure of applanation tonometry.
- Used for posterior segment diagnosis (Retinal angiography)

2. Rose Bengal and lissamine green

- It is used as 1% solution and saturated paper strips.
- It stains devitalized tissue on the cornea and conjunctiva.

3. Ocular Anesthetics

- Proparacaine: used in conjunctival scraping etc for diagnostic procedures.

4. Mydriatic drops and cycloplegics

- Mydriatics are used to dilate the pupil by temporarily paralyzing the iris sphincter muscle.
- Cycloplegics temporarily paralyze accommodation so as to focus the lens for distant vision.

Review Questions

1. Describe Netra swāsthya rakshanōpāya.
2. Mention chedana sādhyā rogas of netra.
3. Mention dietary factors which are responsible for producing diseases of eyes.
4. What is kriyākalpa? Describe tarpana in detail.
5. Write in detail about putāpaka and why it should be performed after tarpana?
6. Write in detail about classification of Anjana.
7. Describe indications and contraindications of Anjana.
8. Describe Bidālaka and pindi.
9. What is Avaguntana?
10. Write therapeutic difference between Seka and Aschōtana.
11. Mention & describe the shastra chikitsas indicated in Netra rogas.
12. Importance of Pādābhyanga in netra raksha.
13. Mention some Chakshushya dravyas.
14. Explain the role of Panchakarma in netra rogas.
15. Write Rakshā karma procedures adopted during shastrakarma.

Scope for Research

1. Effect of Raksha karma vidhi explained in Ayurveda in sterilizing Operation theatre.
2. Analyse the Chakshushya dravyas mentioned in Ayurveda for their role in promoting vision.

Research update

1. Critical study on safety of a unique therapeutic modality- Tarpana: presented in pre-conference workshop- 'Update Ayurveda', Seth G.S Medical college, KEM Hospital, Mumbai, 1999.
2. A clinical study on the role of Akshi Tarpana with Jeevantiyadi Ghrita in Timira (Myopia) Department of Shalakya Tantra, Institute for Post Graduate Teaching and Research in Ayurveda, Gujarat Ayurved University, Jamnagar, Gujarat, 2011.

Chapter-3

SANDHIGATA ROGA

(DISEASES OF JUNCTIONAL AREAS OF EYE)

- | |
|---|
| A. Number of sandhigata rogas, detailed etiology, pathology, clinical features and management of Pooyālasa and Srāva Rogas. |
| B. Brief Study of krimi granthi, Parvani and Alaji Rogas. |
| C. Study of Acute and Chronic Dacryocystitis, Epiphora, Blepharitis including their etiology, pathology, signs & symptoms, differential diagnosis, medical & surgical management. |

Chapter

3A

- | | |
|-------------------|-------------------------------------|
| • Types of Sandhi | • Classification of Sandhigata Roga |
| • Puyālasa | • Upanāha |
| • Netra Srāva | |

NETRA SANDHI

The conjoining areas of any two mandalas make a Sandhi. They are 6 in number.

पक्ष्मवर्त्मगतः सन्धिवर्त्मशुक्लगतोऽपरः । शुक्लकृष्णगतस्सन्धयः कृष्णदृष्टिगतोऽपरः ॥
ततः कर्नीनकगतः षष्ठश्चापाङ्गः स्मृतः ॥ (Su. U.1/16)

The 6 sandhis are

- | | |
|-------------------------------|-------------------------------|
| 1. Pakshma vartmagata sandhi | 4. Krishna drishtigata sandhi |
| 2. Vartma shuklagata sandhi. | 5. Kaneenika sandhi. |
| 3. Shukla krishnagata sandhi. | 6. Apānga sandhi. |

1. Pakshma vartmagata sandhi

It is the junction between the eye lids and eye lashes and can be considered as the lid margin. Openings of meibomian glands, glands of zeis and glands of moll are present in this sandhi. Krimigranthi is one of the disease occurring here.

2. Vartma shuklagata sandhi

It is the junction between the vartma mandala and shukla mandala and can be considered as the site where the palpebral and bulbar conjunctiva meet i.e. Fornix (Superior, inferior, medial & lateral).

3. Shukla krishnagata sandhi

It is the junction between the shukla mandala and krishna mandala and can be considered as limbus. This sandhi is functionally very important for the drainage of aqueous humour. Shukla mandala is opaque and krishna mandala is transparent in nature. Parvani and Alaji are the diseases manifesting in this sandhi.

4. Krishna drushtigata sandhi.

It is the junction between the krishna mandala and drushti mandala. It can be considered as free margins of iriś (pupil). The disease Upanāha manifests here.

5. Kaneenika sandhi (Nāsa sameepa sthita sandhi)

It is the junction between the upper and lower lid medially and is considered as medial or inner canthus. It is directly connected with nasal cavity through naso lacrimal duct. Kanīnika sandhi has key role in the drainage of tears. The disease *pooyālasa* and four types of *srāva* are said to manifest in this sandhi.

6. Apāṅga sandhi. (Bhrupucchānta sameepa sthita sandhi)

It is the junction between the upper and lower lid laterally and is considered as lateral or outer canthus. Position of the apāṅga sandhi is little higher than kaneenika sandhi. It is considered as a marma point.

CLASSIFICATION OF SANDHIGATA ROGA

पूयालसः सोपनाहः त्वावाः पर्वणिकाऽलजी । क्रिमिग्रन्थिश्च विज्ञेया रोगाः सन्धिगता नव ॥ (Su.Ut. 2/3)

Classification of Sandhigata roga based on involved Sandhi

Sandhi	Roga
Śuklakrishnagata	Parvani, Alaji
Pakshmavartmagata	Krimigranthi
Krishnadrishtigata	Upanāha
Kanīnika	Puyālasa and 4 types of Srāva

Classification of Sandhigata roga based on dosha prakopa

Dosha prakopa	Roga
Sannipātaja	Alaji, Puyālasa, Pūyāsṛāva
Kaphaja	Krimigranthi, Upanāha, Kaphasṛāva
Pittaja	Pittasṛāva
Raktaja	Raktasṛāva, Parvani

Classification of Sandhigata roga based on Śāstra karma

Surgical procedure	Based on Sastra karma
Bhédana	Diseases
Vyadhana	Krimigranthi, Upanāha
Chédana	Puyālasa
	Parvati

Classification of Sandhigata roga based on Sadhyāsadhyatva

Prognosis	Diseases
Sādhyā	Puyālasa, Upanāha, Parvani, Krimigranthi
Asādhyā	4 types of Srāva, Alaji

PŪYALASA (Dacryocystitis)

(Pūya - pus, Alasa - collection)

Pūyalasa is a sannipātaja vyadhana sādhya vyādhi with predominance of pitta. The involved dhatus are rakta and mamsa.

पक्वः शोफः सन्धिजः संतत्रवेद्यः सान्द्रं पूयं पूति पूयालसः सः । (S.U. 2/4)

Pakva- Suppurated.

Shoppha- Swelling

Sandhi- Junction of eye (kaneenika)

Samsravédhyaha- Discharge

Saandram- Thick

Pooya- Pus

Pooti- Foul smell

Pūyālasa is characterized by a swelling in the kaneenika sandhi. On suppuration, a thick, purulent, foul smelling discharge is produced.

According to Vagbhata

पूयात्सो व्रणः सूक्ष्मः शोफ संरम्भ पूर्वकः । कनीन सन्धौ आध्मायी पूयात्त्वावी सवेदनः ॥ (A.H.U.107)

Adhmāyi- Swollen (bloated)

Samrambha- Redness

Sookshma vrana- Small ulcers

Pooya srāvi- Discharging pus

Savedana- With pain

Kaneenika sandhi- Inner canthus

Pūyāśa is a condition where in a swelling characterized with redness, pain, ulcers and continuous discharge of pus is seen in the kaneenika sandhi.

13 S.T.-I

Chikitsa

पूयालसे शोणितमोक्षणं च हितं तथा एव अपि उपनाहनं च ।
कुत्सोविधिश्चेक्षणं पाकघाती यथाविधानं भिषजा प्रयोज्यः ॥ (S.Ut.12/45)

The treatment according to clinical stage is-

- Shareera shodhana
- Upānāha sweda
- Raktamōkshana
- Anjana- a) Kāseesa, saindhava, ādraka with madhu.
b) Above combination with louha bhasma and tāmra bhasma.

In the Stage of Pāka, Vyadhana (incision & drainage) and Nādivrana chikitsa has to be done.

If not treated properly, Pooyālasa will lead to a stage called Pilla roga. Agnikarma is indicated if this condition continues.

UPANĀHA

(Cyst of Iris/ Mucocoele)

Upanaha is a Kaphaja, Bhedana Sādhyā Vyadhi.

ग्रन्थिर्नालो दृष्टिसन्ध्यावपाकः कण्डुप्रायो नीरुजस्तूपनाहः ॥ (S.U.12/4)

Granthi- Nodular swelling

Nālpa- Not small

Drishtisandhi- Junction of eye (Krishna drishti sandhi) **Apāka-** Non suppurative

Kanduprāyo- Associated with itching

Nīruja- Painless

Upānāha is characterized by a painless, large, non suppurative nodular swelling at the drishti sandhi associated with itching.

According to Vagbhata

कफेन शोफः तीक्ष्णः क्षार बुद्बुदकोपमः । पृथुमूलबलः स्निग्धः सवर्णो मृदु पिच्छिलः ।

महानपाकः कण्डुमानुपनाहः सनीरुजः ॥ (A.H.Ut.10/3.)

Shópha- Swelling

Kshāra budbudakópama- Resembles bubbles produced on boiling alkalis

Pruthu- Deep rooted

Snigdha- Unctuous

Savarna- Skin coloured

Mṛudu- Soft

Picchila- Sticky

Mahān- Big

Apāka- Non suppurative

Kaṇḍu- Itching

Nīruja- Painless

Upānāha is a big, painless, non-suppurative, deep-rooted, soft, sticky, skin coloured swelling associated with itching. It is caused by the vitiation of kapha. It's size and shape resembles the bubbles produced on boiling alkalis.

Chikitsa

Bhedana is the line of treatment for upanāha. Since it is a non suppurative swelling, effort should be made to bring it to suppurative stage before doing incision and drainage.

उपनाहं भिषक् स्विन्नं भिन्नं ब्रीहिमुखेन च । लेखयेन्मण्डलाग्रेण ततश्च प्रतिसारयेत् ।

पिप्पली क्षौद्रं सिन्धुतैर्बध्नीयात् पूर्ववत्ततः । पटोलपत्र आमलक क्वाथेनाक्ष्योतयेच्च तम् ॥ (A.H.Ut.11/1-2)

Stepwise treatment to be followed in Upānāha

1. Swedana is done initially to bring the non suppurative swelling to suppurative stage.
2. Bhedana is done using Vṛhimukha shastra.
3. Scraping the contents of the swelling by Mandalāgra shastra.
4. Pratisārana with the drugs like pippali, saindhava and madhu.
5. Clean the part with warm water.
6. Sprinkle the area with ghee.
7. Massage lightly with ghee and honey.
8. Lastly bandage the part.

Later Aschótana should be done with Patola patra and amalaki kwātha.

NETRASRĀVA

(Chronic Dacryocystitis, Epiphora)

Samprapthi of Netra Srāva

गत्वा सन्धीन् अश्रुमार्गेण दोषाः कुर्युः स्रावान् रुक् विहीनान् कनीनान् ।
तान् वै स्रावान् नेत्रनाडीं अर्थके तस्या लिङ्गं कीर्तयिष्ये चतुर्थी ॥ (S.U.2/5)

Sandheen- In the junction	Ashru maargēna- Through lacrimal duct
Srāvan- Secretions	Ruk viheenān- Pain less
Liṅgam- Symptoms	Keertayishye- Told

According to Videha

अश्रुस्रावः सिरा गत्वा नेत्रसन्धिषु तिष्ठति । ततः कनीनकं गत्वा चाश्रु कृत्वा कनीनके ॥
ततः स्रवत्यथास्रावं यथादोषमवेदनम् ॥ (S.U.2/5-7 Videha)

Ashrusrāva: Lacrimation	Sirāgatva : Goes through channels (ashruvaha)
Netrasandhi: Junction of eye	Tishtati: Localizes
Kaneenika: Inner canthus	Kritva: Does
Avedana : Painless	

The vitiated doshas goes through the siras (ashruvaha) and gets localized in the netrasandhis producing painless secretions (srāva) through kaneenika sandhi. The srāva manifests according to the involved dosha. This is also called as 'Netranādi'.

The four types of srāva are

1. Pooya srāva
2. Shlëshma srāva
3. Rakta srāva
4. Pitta srāva

Vāgbhata also describes 4 types of srāva, instead of pitta srāva, he mentions Jala srāva.

1. Pooya Srāva

पाकः सन्धौ संस्रवेद्यश्च पूयं पूयास्रावो न एकरूपः प्रदिष्टः । (S.U.2/6)

Paaka- Suppuration	Pooyam samsravet- Produces purulent discharge
Sandhau- In netra sandhi	Aneka roopa- Various types

The vitiation of tridoshas in ashruvaha srotas gives rise to inflammatory changes leading to various types of purulent discharge from the kaneenika sandhi. It is said to be an asādhya vyādhi.

According to Vagbhata

पूयास्रावे यत्नाः सास्त्रा वर्तसन्धेः कनीनकात् । स्रावयन्ति युहुः पूयं स्रावं त्वक् मांसपाकतः ॥ (A.H.U.10/6)

Mala- Tridosha	Saasra- With rakta
Muhuhu- Frequent	Puya- Pus
Twak mamsa pākata- Suppuration of twak and māmsa	

Rakta along with tridoshas suppurates twak and mamsa. Due to this, frequent discharge of blood mixed pus is seen in the kaneenika part of varthma sandhi.

2. Shlëshma Srāva

श्वेतं सान्द्रं पिच्छिलं संस्रवेद्यः श्लेष्मास्रावो नीरुजः स प्रदिष्टः ॥ (S.U.2/6)

Shwēta- White	Saandra- Thick
Picchila- Sticky	Samsravedyaha- Discharge
Neerujaha- Painless	

The vitiation of kapha in ashruvaha srotas leads to painless, white, thick, sticky discharge from the kaneenika sandhi. It is said to be an asādhya vyādhi.

According to Vagbhata

कफात् कफास्रावे श्वेतं पिच्छिलं बहलं स्रवेत् । (A.H.U. 10/2)

Shweta- White	Picchila- Sticky	Bahala- Profuse
----------------------	-------------------------	------------------------

The vitiation of kapha dosha produces white, profuse, sticky discharge from the Kaneenika sandhi.

3. Rakta Srāva

रक्तास्रावः शोणितोत्थः सरक्तमुष्णं नाल्पं संस्रवेत्प्रतिसान्द्रम् । (S.U. 2/7)

Raktasraava- Bloody discharge	Shonitottaha- Originated from rakta dosha
Saraktam- With blood	Naalpam- Not less (profuse)

Nātisāndram- Not too thick

Samsravet- Discharges

Ushnam- Hot

The vitiation of rakta in ashruvaha srotas leads to not too thick, but profuse, hot and bloody discharge from kaneenika Sandhi. It is an asādhya vyādhi.

According to Vagbhata

रक्ताद् रक्तास्रवे ताम्रं बहूष्णं चाशु संस्रवेत् । (A.H.U.10/4)

Tāmra- Coppery brown **Bahu ushna-** Very hot

The vitiation of rakta dosha produces coppery brown coloured, very hot discharge from the Kaneenika sandhi.

4. Pitta Srāva

पीताभासं नीलमुष्णं जलाभं पित्तास्रावः संस्रवेत् सन्धिमध्यात् ॥ (S.U. 2/7)

Peetābhāsam- Yellowish in colour

Neelam- Bluish

Ushna- Hot

Jalābham- Watery in-consistency

Sandhi madyat- Between the sandhi

The vitiation of pitta in the ashruvaha srotas leads to yellowish blue coloured, hot, watery discharge from the kaneenika sandhi.

It is also considered as an asādhya vyādhi.

5. Jala Srāva

वायु क्रुद्धः सिराःप्राप्य जलाभं जलवाहिनीः । अश्रु स्रावयते वर्तुशुक्ल सन्धेः कनीनकात् ॥
तेन नेत्रम् सरुग्रगण्डोफं स्यात् स जलास्रावः ॥ (A.Hr.U.10/1)

Vāyu kṛuḍa- Vitiated vata

Sirā prāpya- Reaches vessels

Jalābham- Watery

Ruk- Pain

Rāga- Red

Shópha- Swelling

Vāta gets vitiated and reaches the siras producing watery discharge from Vartma Shukla and Kaneenika sandhi. It is associated with pain, redness and swelling in the eyes.

Chikitsa

All the Sravās are said to be Asādhya

As Srāva is said to be Asādhya by both Sushruta and Vāgbhata, no treatment is explained in their texts. But some authors of Medieval period (Yogarātnakara, Chakradutta etc.) have mentioned the following treatment.

ह्लावेषु त्रिफला क्वाथं यथादोषं प्रयोजयेत् । क्षौद्रेण आज्येन पिप्पल्या मिश्रं विध्येच्छिरां तथा ॥

In all kind of Srāva, Triphala kwatha is indicated.

- Triphala kwātha+ honey in Kaphaja netra srāva
- Triphala kwātha+ ghee in Pittaja netra srāva
- Triphala kwatha + pippali in Vātaja netra srāva

Sirāvyadha is also indicated in the management of srāva.

Anjanās mentioned for srāva

1. **Pathyadi varti-** Pulp (majja) and fruits (phala) of Triphala is used as varti in rakta srava. (Chakradutta 59/200).
2. **Karpāsādyadi varti-** Kārpasi phala, jambu, amṛa, rasānjana along with madhu in chronic srāva. (Yogarātnakara Uttarakhanda Netraroga chikitsa).

Chapter

3B

- Parvāni
- Alaji
- Krimigranthi and its management

PARVANI

(Phlyctenular Conjunctivitis)

Parvāni is Raktaja Chédana Sādhya Vyādhi.

Lakshanas of Parvāni

ताप्रा तन्वी दाहशूलोपपन्ना रक्ताब्जेया पर्वणी वृत्तशोफा । जाता सन्धी कृष्णशुकले.....(S.U.2/8)

Taamra : Copper	Tanvi : Thin
Dāha : Burning	Shoola : Pain
Upapanna : Associated with	Jneya : Known as
Vritta : Circular	Shópha : Swelling
Jaata : Takes place	Krishnashukla sandhi : Sclerocorneal junction

Vitiation of rakta leads to the formation of a thin, circular swelling at the krishnashukla sandhi. It is coppery in colour & is associated with burning sensation and pain. This condition is called parvāni and is considered as the prodromal symptom of Alaji.

According to Vagbhata

वर्त्म सन्धि आश्रया शुक्ले पिटिका दाह शूलिनी ।।
ताप्रा मुद्रोपमा भिन्ना रक्तं स्रवति पर्वणी ।। (A.H.U.10/5)

Āshraya- Localized	Pitika- Nodule
Dāha- Burning	Shūla- Pain
Tāmra- Copper coloured	Mudgopama- Green gram shaped
Bhinna- Puncturing	

Sandhigata Roga

103

Parvāni is a copper coloured, green gram (mudga) shaped nodule localized in the vartma shukla sandhi. It is associated with burning sensation, pain and bleeding on puncturing.

Shashtra Chikitsa for Parvāni

सन्धी संखेद्य शस्त्रेण पर्वणीकां विचक्षणः । उत्तरे च त्रिभागे च बडिशेनावलम्बिताम् ।।
छिन्नाततोऽर्धमग्रे, स्यादश्रुनाडीह्यतोऽन्यथा । प्रतिसारणपत्रापि सैन्यवक्षोद्रमिष्यते ।।
लेखनीयानि चूर्णानि व्याधिशेषस्य भेषजम् । (S.U.15/23,24)

पर्वणी बडिशेनात्ता बाह्यसन्धिनिभागतः । वृद्धिपत्रेण वर्ध्याऽथे स्यादश्रुगतिरन्यथा ।।
चिकित्सा चार्मवत्क्षोद्रसैन्यव प्रतिसारिता । (A.H.U.11/3-4)

- Firstly swedana is done to the part to soften the tissue.
- Then hold & lift one third part of the lesion by Badisha yantra.
- Carefully excise half part of the parvāni pidika by Vriddipatra.
- Over excision may lead to complications like ashru nādi (Lacrimal sinus).
- Later pratisārana with Saindhava & Madhu is done.
- To remove the remnants of the lesion, lekhaṇa karma is also indicated.

Lekhāna Anjana for the above procedure (S.U. 15/25-28)

Powders of shaṅkha, samudraphēna, mandūki, shukṭi, sphaṭika, kuruvinda (padmarāga), pravāla, ashmaṇṭaka, vaidūrya, pulaka, mukta, lauha, tāmra and srotōṇjana is taken in equal quantity and mixed together. It should then be stuffed in meshashringi (Ram's horn) to prepare anjana.

ALAJI

(Advanced Stage of Phlyctenular conjunctivitis)

It is a Sannipātaja Asādhya Vyādhi

.....अलजी स्यात्तस्मिन्नेव ख्यापिता पूर्वलिङ्गैः ।। (S.U.2/8)

Tasminneva : It has

Khyaapita pūrvalingaihi : Symptoms as told earlier (as in parvāni).

Alaji is the progressive stage of Parvāni. Here, the swelling will be thick (sthula-Dalhana commentary) along with other symptoms of parvāni.

14 S.T.-I

According to Vagbhata

कनीनस्य अन्तः अलजी शोफो रुक् तोद दाहवान् । (A.H.U. 10/8)

Shópha- Swelling

Ruk- Pain

Tóda- Pricking sensation

Dāha- Burning sensation

Alaji is a swelling manifesting in the inner aspect of kaneenika sandhi. It is associated with pain, pricking and burning sensation.

Difference between Parvani and Alaji

Features	Parvani	Alaji
1. Dosha	Raktaja	Tridoshaja
2. Size of pitika	Thin	Thick (large)
3. Netra sandhi	Shukla Krishna (Su) Shukla vartma (Vag.)	Shukla Krishna (Su) Inner aspect of Kaneenika (Vag)
4. Symptoms like pain and burning sensation	Mild	Severe
5. Location of lesion	Superficial	Deep
6. Prognosis	Sādhya	Asādhya

KRIMIGRANTHI (Blepharitis)

Yogaratnakara names krimigranthi as Jantugranthi

It is a Kaphaja Bhédana Sādhya Vyādhī.

क्रिमिग्रन्थिवर्त्मनः पक्ष्मणश्च कण्डूं कुर्युः क्रिमयः सन्धिजाताः ।

नानारूपा वर्त्मशुक्लस्य सन्धौ चरन्तोऽन्तर्नयनं दूषयन्ति ॥ (S.U.2/9)

Krimigranthi- Cystic swelling produced by krimi.

Varthmanaha pakshmanaha- Appears in eye lid and lashes.

Kandu- Itching

Kuryuhu- Causes

Krimayaha- Micro organisms (maggots) **Sandhi jaataha-** Originates from netra sandhi

Nāna roopa- Various types of organisms. **Charanti-** Moves

Antar nayana- Inner part of eye **Dooshayanti-** Vitiates.

Krimigranthi is a disease in which small cystic swelling associated with itching is found in the junction between eyelids and eyelashes. These are caused by various types of krimis which moves further and vitiates the inner structures of the eye including vartmashukla sandhi.

According to Vagbhata

अपङ्गे वा कनीने वा कण्डु ऊषा पक्ष्म पोदवान् ।

पूयास्त्रावी कृमिग्रन्थिः ग्रन्थिः कृमियुतो अर्तिमान् ॥ (A.H.U.10/9)

Kāndu- Itching

Ūsha- Burning sensation

Arti- Pain

Krimi- Micro organism

Granthi- Cyst

In krimigranthi, cysts are formed by micro organisms either at the outer or inner canthus of the eyes. It is associated with pain, itching, burning sensation, pus discharge and cracks on the eyelids.

Chikitsa

सम्यक् स्वित्रे कृमिग्रन्थौ भिन्ने स्यात् प्रतिसारणम् । त्रिफलातुल्यकासीससैन्यवैश्च रसक्रिया ॥ (S.U.14/8)

- First Proper swedana is done on the lid margins.
- Krimigranthi present on the lid margin are incised.
- Then Pūśārana is done with paste made of triphalā, tuttha, kāseesa and saindha.

- Drainage of tears
- Epiphora
- Dacryocystitis
- Blepharitis

Drainage of Tears

Tears are secreted from the lacrimal gland. On blinking, lids push tears evenly across the eyes to keep it moist and healthy. Blinking also pumps tears into the puncta and by capillary action, they are drawn into the lacrimal sac and travels through the naso-lacrimal duct and finally tears gets drained into the nose from where it is evaporated.

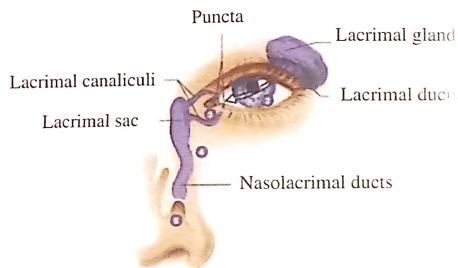


Fig. 3.1

EPIPHORA (Watering of Eyes)

Two terms are used in connection with watering of the eye:

- (i) Epiphora and (ii) Lacrimation.

1. Epiphora denotes watering due to obstruction to outflow of tears.
2. Lacrimation denotes watering due to excessive secretion of tears.

Causes of Epiphora

- Stenosis of the punctum: particularly the lower one-Congenital or acquired.
- Eversion of the lower punctum due to laxity of the orbicularis muscle as in senility, facial paralysis and ectropion.

- Obstruction in the lower canaliculus due to calculus or infection.
- Obstruction of the sac : due to tumour of the sac or following removal of the sac.
- Obstruction in the naso-lacrimal duct as in chronic dacryocystitis, nasal polyp and maxillary antrum tumour pressing on the duct.

Clinical evaluation of Epiphora

Ocular examination to exclude causes in the punctum and any swelling in the sac.

- **Regurgitation test :** Pressure is applied over lacrimal sac area above the medial palpebral ligament. Reflux mucopurulent discharge indicates obstruction at the lower end of sac or nasolacrimal duct.
- **Fluorescein dye disappearance test :** Two drops of fluorescein dye are instilled in both conjunctival sac and observations made after two minutes. A prolonged retention of dye in conjunctival sac indicates mechanical obstruction.
- **Lacrimal syringing test:** Normal saline is pushed into the lacrimal sac from lower punctum with the help of syringe and lacrimal canula. In the presence of obstruction, no fluid passes into the nose and it may reflect through the same punctum indicating obstruction in the same or common canaliculi. The fluid passes out through the opposite punctum indicating obstruction in the lower sac or naso-lacrimal duct.

Treatment

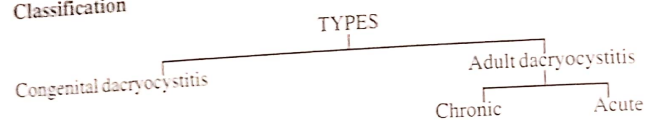
The causes of obstruction must be evaluated and treated accordingly.

- **In stenosis of the punctum-** Laser punctoplasty or amputotomy may be used to enlarge the outflow orifice.
- In eversion of the lower punctum as in ectropion, the only cure is to surgically realign the punctum with the globe.
- In obstructive conditions, punctal or canicular dilation and irrigation is done.
- Dacryocystorhinostomy (DCR) is indicated if blockage exists distally in the nasolacrimal system. This creates a surgical bypass of the common canaliculus directly into the nasal mucosa.

DACRYOCYSTITIS

It is the inflammation of the lacrimal sac.

Classification



Congenital dacryocystitis or dacryocystitis in new born

This condition arises due to failure in canalization of the naso-lacrimal duct, the lumen being blocked by epithelial debris. The condition may be bilateral.

Treatment

Sharp pressure over the sac area may force the content down. Thus the patency of the naso lacrimal duct is achieved. Probing of the nasolacrimal duct is helpful in this condition. Delay in treatment causes complete cicatricial obliteration or blocking of the duct.

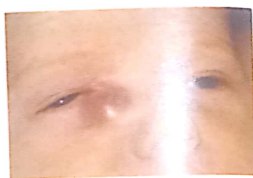


Fig. 3.2

Chronic dacryocystitis

Etiology

Age: Usually affects adults between 40 and 60 years of age.

Sex: Predominantly seen in females (80%) due to narrow lumen of the bony canal.

Bi-laterality: May be unilateral or bilateral.

Social incidence: Common in low socio-economic group.

Causative organisms

Staphylococci, pneumococci, streptococci and pseudomonas pyocyanea.

Pathology

Stricture of the nasolacrimal duct causes stagnation of the contents of the sac. This become infected and the sac wall becomes chronically inflamed. The epithelium



Fig. 3.3

of the sac wall multiplies to form several layers and the vascularity of wall increases and becomes atonic. The contents of the sac which are at first watery, later becomes mucoid due to excessive secretion of mucus by goblet cells and afterwards mucopurulent due to exudation of pus cells.

Symptom

The commonest symptom is watering eye.

Clinical signs

1. Catarrhal stage

- Persistent watering of the eye.
- Mild conjunctival hyperaemia at inner canthus of the affected eye.
- On applying pressure on the sac, very little or no regurgitation of fluid through punctum.
- On syringing the sac, fluid regurgitates through the upper punctum mixed with flakes of mucus.
- No local swelling over the sac area or tenderness.

2. Mucocoele stage

- In addition to watering, there is swelling over the sac area below the medial palpebral ligament which is not tender.
- On pressure over the sac, mucoid material regurgitates through the punctum.
- Encysted mucocoele- Sometimes both the canaliculi may be blocked and there is no regurgitation on pressure.
- Conjunctival hyperaemia at the inner canthus.

3. Pyocoele stage

- Conjunctival hyperaemia at the inner canthus becomes more pronounced.
- Similar swelling over the sac area below the medial palpebral ligament, which is not tender. Also there is no redness of the skin over the swelling.
- On pressure over the sac, there is regurgitation of mucopurulent matter through the punctum.

- Watering of the eyes remains as before.

Complications

- Acute on chronic dacryocystitis. i.e. recurrent acute attacks on chronic dacryocystitis.
- Development of the corneal ulcer, which is known as hypopyon ulcer or *ulcus serpens* of the cornea as the causative agent is pneumococcus derived from the sac.
- Chronic conjunctivitis.

Treatment

1. Conservative treatment: By repeated lacrimal syringing.
2. Balloon catheter dilation in partial nasolacrimal duct obstruction.
3. Dacryocystorhinostomy (DCR): The medial wall of the sac is anastomosed with the mucous membrane of the middle meatus of the nose.
4. Dacryocystectomy (DCT): Removal of the lacrimal sac.

Acute dacryocystitis

It is acute suppurative inflammation of the lacrimal sac characterized by the presence of painful swelling in the lacrimal sac.



Fig. 3.4

Etiology

It may develop in two ways.

1. As an acute exacerbation of chronic dacryocystitis.
2. As an acute peridacryocystitis due to direct involvement from the neighboring infected structures like paranasal sinuses, surrounding bones and dental abscess.

Causative organisms Commonly involved are streptococcus haemolyticus, pneumococcus and staphylococcus.

Pathology

The sac becomes filled with frank pus with abundant poly morphonuclear leucocytes. Inflammation spreads to the tissues surrounding the sac causing pericystitis. Lacrimal abscess is finally formed which usually bursts on the skin surface forming a lacrimal fistula. As soon as the pus drains out, the inflammation subsides.

Symptoms

1. Severe pain and sensation of heat over the sac area.
2. Fever.
3. Watering of eyes.

Clinical signs

1. Marked swelling and redness of the skin over the sac area.
2. Oedema of the skin of the lids and on the side of the nose.
3. Skin over the sac is tender and hot.
4. No regurgitation through the punctum.
5. Slight congestion of the conjunctiva.
6. Enlargement of the sub maxillary lymph nodes.
7. When abscess bursts, fistula is formed and signs and symptoms of acute inflammation subsides.
8. If this condition is not properly treated, there may be acute attacks of dacryocystitis in future.

Complications

- Osteomyelitis of the lacrimal bone.
- Orbital cellulitis.
- Facial cellulitis.
- Cavernous sinus thrombosis.
- Acute conjunctivitis.

Treatment

a) Before abscess formation

- Hot compresses over the affected sac.
- Systemic and topical antibiotics to control infection.
- Systemic anti inflammatory and analgesic drugs.

b) When inflammation has localized

- Incision over the sac to drain the pus.
- Removal of the sac when inflammation completely subsides.

When lacrimal fistula has formed, surgical techniques such as excision of the fistulous passage and removal of the sac is indicated.

DACRYOCYSTORHINOSTOMY

Dacryocystorhinostomy (DCR) is a surgical procedure to restore the flow of tears into the nose from the lacrimal sac when the nasolacrimal duct does not function.

Dacryocystorhinostomy (DCR) operation can be performed by two techniques:

- 1) Conventional external approach DCR, and
- 2) Endonasal DCR

Conventional external approach DCR

1. **Anaesthesia:** General anaesthesia is preferred. However, it may be performed with local infiltration anaesthesia in adults.
2. **Skin incision:** Either a curved incision along the anterior lacrimal crest or a straight incision 8 mm medial to the medial canthus is made.
3. **Exposure of medial palpebral ligament (MPL) and Anterior lacrimal crest:** MPL is exposed by blunt dissection and cut with scissors to expose the anterior lacrimal crest.
4. **Dissection of lacrimal sac:** Periosteum is separated from the anterior lacrimal crest and along with this, the lacrimal sac is reflected exposing the lacrimal fossa.
5. **Exposure of nasal mucosa:** A bony osteum is made by removing the anterior lacrimal crest exposing the thick, pinkish white nasal mucosa.
6. **Preparation of flaps of sac:** A probe is introduced into the sac through lower canaliculus and the sac is incised vertically. To prepare anterior and posterior flaps, this incision is converted into 'H' shape.
7. **Suturing of flaps:** Posterior flap of the nasal mucosa is sutured with posterior flap of the sac. It is followed by suturing of the anterior flaps.
9. **Closure:** MPL is sutured to periosteum, orbicularis muscle is sutured and skin is closed with silk sutures.

DACRYOCYSTECTOMY (DCT)

Dacryocystectomy is a well-established oculoplastic procedure that refers to a complete surgical removal of lacrimal sac.

1. **Anaesthesia:** General anaesthesia is preferred.
2. **Skin incision:** Either a curved incision along the anterior lacrimal crest or a straight incision 8 mm medial to the medial canthus is made.
3. **Exposure of medial palpebral ligament (MPL) and Anterior lacrimal crest:** MPL is exposed by blunt dissection and cut with scissors to expose the anterior lacrimal crest.
4. **Dissection of lacrimal sac :** Periosteum is separated from the anterior lacrimal crest and along with this, the lacrimal sac is reflected laterally with blunt dissection exposing the lacrimal fossa.
5. **Removal of lacrimal sac:** After exposing the sac, it is separated from the surrounding structures by blunt dissection followed by cutting its connections with the lacrimal canaliculi. It is then held with artery forceps and twisted 3-4 times to tear it away from the nasolacrimal duct (NLD).
6. **Curettage of bony NLD:** It is done with the help of a lacrimal curette to remove the infected parts of membranous NLD.
7. **Closure :** MPL is sutured to periosteum, orbicularis muscle is sutured and skin is closed with silk sutures.

The upper end of the duct is curetted & the incision is closed by sutures.

BLEPHARITIS**Definition**

Blepharitis is the most common disease caused due to subacute or chronic inflammations of lid margins.

It can be divided into following clinical types:

1. Bacterial Blepharitis (ulcerative).
2. Seborrheic or squamous Blepharitis.
3. Mixed staphylococcal with seborrheic Blepharitis.

4. Posterior Blepharitis or Meibomitis.
5. Parasitic Blepharitis.

1. Bacterial or ulcerative Blepharitis

It is chronic infection of the anterior part of the lid margin. There is suppurative inflammation of the ciliary follicles along with the glands of Zeis and Moll.

Etiology

Causative organisms: Staphylococci, rarely streptococci, moraxella.

Clinical features

Symptoms

Chronic irritation, itching, mild lacrimation, glueing of cilia and mild photophobia.

Signs

- Yellow crusts are deposited at the root of the eye lash by which the lashes are glued together.
- On removing the crusts, small ulcers appear around the base of the lashes which bleed freely.
- Rosette's- red thickened lid margins seen with dilated blood vessels.
- Falling of the eye lashes, which are either not replaced or when replaced become misdirected.

Treatment

1. Lid hygiene
 - Warm compresses for 5 to 10 minutes to soften the crusts.
 - Crust removal and lid margin cleaning with the help of cotton buds dipped in solution of 3% sodium bicarbonate.
 - Antibiotic eye ointment should be applied immediately after removal of crusts.
2. Antibiotic eye drops and oral antibiotics

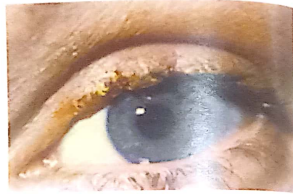

Fig. 3.5

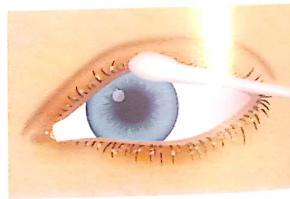


Fig. 3.6

3. Topical steroids like fluomethalone
4. Ocular lubricants

2. Seborrhoeic or squamous Blepharitis

Etiology

It is not essentially an infective condition. Metabolic causes, hygienic factors, eye strain and dandruff of the scalp usually lead to the development of this condition.

Symptoms

- Deposition of whitish material (soft scales) at lid margin.
- Mild discomfort.
- Irritation.
- Occasional watering of eyes.
- History of falling of lashes.

Signs

- White dandruff like scales on lid margin. On removing the scales, underlying surface is found to be hyperaemic and greasy (no ulcer).
- Lashes fall out easily but are usually replaced without distortion.
- Lid margins are thickened and sharp posterior border tends to be rounded.

Treatment

- General measures include improvement of health and balanced diet.
- Treatment of seborrhea of scalp.
- Removal of scales from lid margins with the help of luke warm solution of 3% sodium bicarbonate or baby shampoo.
- Frequent application of antibiotic and steroid ointment.

3. Posterior Blepharitis or Meibomitis

It is an inflammation of meibomian glands. It can occur in chronic and acute forms.

Acute meibomitis is caused due to staphylococcal infection and is characterized by painful swelling around the involved gland. Pressure on it results in expulsion of pus.

Chronic meibomitis is a commonly occurring meibomian gland dysfunction in those with acne, rosacea and/or seborrhoeic dermatitis.

Fig. 3.7

Fig. 3.8

- Lid hygiene.
- Topical antibiotics in the form of eye ointment and drops.
- Systemic tetracyclines.
- Topical steroids.
- Ocular lubricants.

4. Parasitic Blepharitis (lash infestation)

Blepharitis associated with infestation of lashes by crab louse.

Chronic irritation, itching, burning and mild lacrimation.

- Lid margins inflamed.
- Nits (eggs) may be seen adherent to the root of eye lashes.

- Mechanical removal of nits & louse.
- Application of antibiotic ointment and yellow mercuric oxide.
- Delousing the patient.

Review Questions

1. Describe the disease 'Pūyālasa'. What are the treatment modalities of the disease?
2. Classify & Enumerate Sandigatha rogas.
3. Describe Krimigranthi.
4. Describe 'jalasrāva'.
5. Describe lakshana and chikitsa of 'Upanāha'.
6. Differentiate Pūyālasa and Pooyasrāva.
7. Classify Srāva and write it's differential diagnosis.
8. Write Sādhyāsadyata of sandhigata netra roga.
9. Describe the diseases occurring in kaneenika sandhi.
10. Describe vyavachedaka nidāna for Parvati and Alaji.
11. Describe Shukla Krishna sandhi and diseases occurring in this sandhi.
12. Explain the shastra chikitsa indicated for Parvati.
13. Describe the surgical management of Krimigranthi as per Ayurveda.
14. Define dacryocystitis & classify it.
15. Surgical management of dacryocystitis.

Research works

1. A clinical study on Dāruharidra kvātha sēka and Amalakyādi rasakriya lepa in the management of Krimigranthi with special reference to Anterior Blepharitis. Dr. Viśwalekshmi, Dept of Shalakya Tantra, SDM, Hassan, Karnataka, 2014.
2. Efficacy of Ashmantakādi anjana in Pūyālasa (Acute Dacryocystitis) MUHS2012-13.

Scope for research

1. Evaluation on the efficacy of Raktamōkṣhāna in the management of Pūyāśa.
2. Clinical study to evaluate Triphala varti Anjana in management of Sṛāva.

Chapter-4

VARTMAGATA ROGA (DISEASES OF LIDS)

- | |
|--|
| A. Number of vartmagata rogas, and detailed knowledge of etiology, pathology, clinical features and management of Anjananāmika, Utsangini, Lagana, Vātahata vartma, Pakshma kōpa, Sikata vartma, Pothaki, Klinna vartma, Krichhronmeelana and Kukūnaka diseases of Vartma. |
| B. Brief Knowledge of Vartmārbuda, Utklishta vartma, Nimesha, Pakshmashāta, Vartmārsha. |
| C. Knowledge of Hordeolum, Ptosis, Trachoma, Trichiasis, Entropion, Ectropion including their etiology, signs and symptoms, differential diagnosis, medical & surgical management. |

Chapter

4A

- | |
|--|
| <ul style="list-style-type: none"> • Patala and sandhis of Vartma mandala • Utsangini, Kumbheeka, Pōthaki, Varthma Sharkara, Shushkārsha, Anjananāmika, Bahala Vartma, Vartmāvabandha, Klisha Vartma, Vartma Kardama, Shāva Vartma, Shlishta Vartma, Klinna Vartma, Vātahata Vartma, Lagana, Bisā Vartma, Pakshmakōpa, Krichhronmilana, Kukūnaka, Kuñchana, Alaji. |
|--|

VARTMAGATA ROGA (DISEASES OF LIDS)

Vartmas are eyelids which cover the eyes externally. They are two in number-Urdhwa and Adha. It is also called as netra puta (covering of eye) or pakshma mūla (root of eyelashes).

Patala and sandhis of Vartma mandala

There are two patalas in Vartma - 1. Bāhya and 2. Abhyantara.

Vartma mandala is associated with four sandhis

- | | |
|------------------------------|---------------------|
| 1. Pakshma vartmagata sandhi | 3. Kaneenika sandhi |
| 2. Vartma shuklagata sandhi | 4. Apānga sandhi |

Panchamahabhuta and doshās present in Vartma


Muscular and vascular nature of vartma indicates the presence of Prithvi and Agni mahābhūta. Predominant doshas present are Kapha and Pitta. Movement of lids is by the action of vāta (vyāna) and since it is situated in the mūrdha, presence of pranavāyu also can be presumed.

Samprapti of Vartmagata rogas

पृथग्दोषाः समस्ता वा यदा वर्तमव्यपाश्रयाः । सिरा व्याप्यावतिष्ठन्ते वर्तमस्वधिकमूर्च्छिताः ॥
विवर्ध्म मांसं रक्तं च तदा वर्तमव्यपाश्रयान् । विकाराञ्जनयन्त्याशुनामतस्तान्निबोधत ॥ (S.U.3/3-4)

15 S.T.-I

Pruthagdoshā- Individual doshas	Samasta va- Together (tridosha)
Yadā- When vartma	Sirā- Blood vessels
Vyāpya- Spreads	Avatishṭati- Localizes
Vartma- Eyelid	Adhika mūrchita- More aggravated
Vivardhya- Increases	Māmsa rakta cha- Muscle and blood
Vartma Vyapashrayan- Localizes in eyelids	Vikaaran- Diseases
Janayanti- Produces	



Vartma gata rogas are 21 in number

उत्सङ्गिन्यथ कुम्भीका पोथक्यो वर्तमशर्करा । तथाऽशौवर्तमशुष्काश्चैवाङ्गनामिका ॥
बहलं वर्तम यच्चापि व्याधिर्वर्तमविबन्धकः । क्लिष्टकर्मवर्तमख्यौ श्याववर्तम तथैव च ॥
प्रक्लिन्नमपरिक्लिन्नं वर्तम वातहतं तु यत् । अबुद्धं निमिषश्चापि शोणितार्शश्च यत् स्मृतम् ॥
लगणो बिशनामा च पक्ष्मकोपस्तथैव च । एकविंशतिरित्येते विकारा वर्तमसंश्रयाः ॥
नामभिस्ते समुद्दिष्टाः.....॥ (S.U 3/5-8)

S.N.	Sushruta (Total 21)	Vagbhata (Total 24)
1.	Uṭsangini	Utsanga
2.	Kumbhika	Kumbhee pidaka
3.	Póthaki	Póthaki
4.	Vartma sharkara	Sikatā vartma
5.	Arshó vartma	Arshó vartma
6.	Sushkārsha	-
7.	Anjana nāmika	Anjana nāmika

8.	Bahala vartma	Bahala vartma
9.	Vartmāvabandha	-
10.	Klishta vartma	-
11.	Kardama vartma	Kardama vartma
12.	Shyāva vartma	Shyāva vartma
13.	Praklinna vartma	-
14.	Apariklinna vartma	-
15.	Vātahata vartma	Vātahata vartma
16.	Arbuda	Arbuda
17.	Nimēsha	Nimēsha
18.	Shonitārsha	-
19.	Lagana	Lagana
20.	Bisā vartma	Bisā vartma
21.	Pakshma kōpa	-
22.		Kṛuchronmeelana
23.		Pittótklishta vartma
24.		Pakshma shāta
25.		Kaphótklishta vartma
26.		Dōshótklishta vartma
27.		Utklishta vartma
28.		Slishta vartma
29.		Kukūnaka
30.		Pakshmoparodha
31.		Alaji

Classification based on Doshas

Vāta	Kapha	Raktha	Sannipāta
Nimēsha	Klinna vartma	Kliṣhta	Uṭsangini
Vātahata Vartma	Lagana	Anjana nāmika	Kumbheeka
	Póthaki	Shonitārsha	Vartma sharkara
			Arsho vartma
			Shushkārsha
			Arbuda
			Aklinna vartma
			Vartmāvabandha

				Bahala vartma
				Shyāva vartma
				Bisā vartma
				Vartma kardama
				Pakshma kōpa

Classification based on Sādhyāsādhya

Asādyā : a. Vātahata vartma
b. Nimésa
c. Shónitārsha

Yāpya: Pakshma kōpa

Classification based on Shastra Chikitsa

Lekhana	Bhedana	Chedana	Ashastrakrutha
Utsangini	Lagana	Arshō vartma	Praklinna vartma
Kumbika	Anjana nāmika	Shushkārshas	Aklinna vartma
Póthaki	Bisa vartma	Arbuda	
Vartma sharkara			
Vartmāvabandha			
Bahalavartma			
Shyāva vartma			
Vartma kardama			
Klisha vartma			

UTSANGINI

(Chalazion or Meibomian cyst)

It is a Tridoshaja Lekhana Sādhya Vyādhi.

अभ्यन्तरमुखी बाह्योत्सङ्गेऽथो वर्त्मनश्च या । विज्ञेयोत्सङ्गिनी नाम तद्रूपपिडकाचिता ॥ (S.U. 3/9-10)

Abhyantara mukhi- Opening inwards

Bāhya- Externally

Utsānga- Elevated or prominent

Adhō vartma- Lower lid

Vignéya- Known as

Tat rupa- Similar shaped

Pidakāchita- Nodular swelling

Utsangini is a condition in which one or more pidakas or nodular swelling erupts in the lower lids. Special feature of these pidakās are that even though they look prominent outwards, their openings are directed inwards.

As per Dalhana's commentary

Utsangini is a pidaka formed in the lower lid, opening inwards but prominent outwards, hard to touch, slightly painful & surrounded by similar pidaka. When the Utsanga pidakas are incised or cut, a secretion similar to contents of an egg (Kukkutānda rasa) is seen.

According to Vagbhata (Utsānga)

रक्ता रक्तेन पिडिका तत् तुल्य पिटिकाचिता । उत्सङ्गाख्या ॥ (A. H. U. 8/12)

Rakta pitika- Red coloured nodules

Tulya pitikāchita- Surrounded by similar pitikas.

A raktaja condition in which red coloured pidika is surrounded by similar pitikas is called Utsanga.

Utsangini is formed only in lower lid

Utsanga is formed in either of eyelids.

Chikitsa

Surgical procedures

- (a) Chédana- If pidika is large (b) Bhédana- If pidikas are small.
(c) Lékhana- After chedana or bhedana karma.

Vāgbhata has mentioned the following steps for the management of utsanga (A.S.U 12/11)

1. Bhedana- Incision of the pidika using appropriate instrument
2. Nishpeedana- Squeezing out the contents of the pidika
3. Lékhana- Scraping of the remnant tissue
4. Pratisārana- Rubbing with the drugs like tagara, ela, saindhava, manashila with honey.
5. Pariseka with Kashaya prepared out of haridra, madhuka and patóla.

KUMBHEEKA

(Meibomian cyst, Stye, Chalazion)

Kumbheeka is a Sannipātaja Lekhana Sādhya Vyādhi.

कुम्भीकबीजप्रतिमाः पिडका यन्तु वर्त्यजाः । आध्यापयन्ति पित्रा याः कुम्भीकपिडकास्तु ताः ॥ (S.U.3/10-11)

Kumbhika bija-	Seeds of pomegranate	Pratima-	Like
Pidaka-	Nodule	Yastu-	It
Vartmaja-	In the lid	Adhmāpayanti-	Swollen
Bhinna-	Puncturing		

Kumbheeka is a disease in which the pidakas resembling pomegranate seed occurs frequently in the vartma. On puncturing the pus gets drained but it swells up again due to the accumulation of pus.

According to Vagbhata

कृष्णाः पित्तेन बह्व्यो अन्तर्वर्त्य कुम्भीक बीजवत् । आध्यापयन्ते पुनर्भिन्नाः पिटिकाः कुम्भि संज्ञिताः ॥ (A.H.U. 8/6)

Krishna-	Black	Bahvayo-	Multiple
Antar vartma-	Inner aspect of eye lid	Kumbheeka beeja-	Seeds of pomegranate
Adhmāyante-	Swells up	Bhinna-	Puncturing

According to Vagbhata, in this the pitikas are black in colour, swollen resembling pomegranate seeds, usually seen in the inner aspect of the eyelid. On puncturing, the pus gets drained out but it gets swollen up again.

Chikitsa

Achārya Vagbhata has advised-

(i) Lekhana (ii) Pratisārana (iii) Parisēka

- The area of the kumbheeka pidika should be scraped. (If the pidakas are small and hard they should be allowed to suppurate after which it can be incised and scraped).
- Pratisārana with saindhava.
- Parisēka with kashaya prepared out of patola, amalaka, yashtimadhu followed by ghrita prepared out of the above drugs.

POTHAKI
(Trachoma)

Pothaki is a Kaphaja Lékhana Sādhya Vyādhi. It is one of the Pilla roga.

स्त्राविण्यः कण्डुरा गुर्व्यो रक्तसर्पपसत्रिणाः । पिडकाश्च रुजावत्यः पोथक्य इति संज्ञिताः ॥ (S.U. 3/11)

Srāvinya-	Discharge	Kaṇḍu-	Itching
Gurvyo-	Heavy/Hard	Rakta-	Red
Sarshapa-	Mustard	Sannibhaha-	Resemble
Pidaka-	Follicle	Rujavatyaha-	Very painful
Iti Sanjnitāha-	Is called as		

It is a vartmagata roga in which the pidakas resemble red mustard seed. The pidakas are hard (heavy), painful, associated with itching and discharge. The condition having the above features is called as Pothaki.

According to Vagbhata

पोथक्यः पिटिकाः श्वेताः सर्पपाभा घनाः कफात् । शोफ उपदेह रुक् कण्डू पिच्छिलाश्च समन्विताः ॥ (A.H. U. 8/9)

Pitika-	Follicle	Shweta sarshapabha-	Resembles white mustard
Ghana-	Hard	Shópha-	Swelling
Ruk-	Pain	Kandu-	Itching
Picchila ashru-	Slimy or sticky lacrimation/discharge.	Upadēha-	Coating

Picchila ashru- Slimy or sticky lacrimation/discharge.

Pothaki is a condition in which hard follicles with coating, resembling the seeds of white mustard originates in vartma due to vitiation of kapha dosha. The associated symptoms are oedema, sticky discharge, pain and itching.

Chikitsa

पोथकीश्चाप्यवलिखेत् प्रच्छयित्वाऽग्रतः शनैः ॥ (S.U.13/15)

Two methods of treatments are indicated in pothaki:

1. Blood letting
2. Scraping.

Initially blood letting is indicated. This is to be followed by scraping the part slowly.

According to Acharya Vagbhata

The management of Pothaki is as follows

1. Lékhana.
2. Pratisarana with shunti, saindhava and pippali.
3. Prakshālana with ushnāmbu.
4. Sechana with kashāya prepared out of khadira, ādhaki and shigru.
5. Aschótana with kashāya prepared out of haridra, daruharidra and yashtimadhu mixed with honey.
6. Aschótana with decoction of tender leaves of āmra and jambu.
7. Anjana prepared from vidanga, lāksha, dāruharidra, twak, haratāla, manashila and honey.

VARTMA SHARKARA (SIKATA VARTMA)
(Lithiasis conjunctivae-A form of Trachoma)

Vartma sharkara is a Sannipātaja Lékhana Sādhyā Vyādhi.

The word Sharkara or Sikata literally means Sugar or Sand particles. It denotes the size and shape of the pidakas in the lids.

पिडकाभिः सुसूक्ष्माभिर्यनाभिरभिसंवृता । पिडका या खरा स्यूला सा ज्ञेया वर्त्मशर्करा ॥ (S.U. 3/12)

Pidaka- Nodule	Susūkshma- Very small	Ghana- Hard
Abhisamvṛuta - Surrounded by	Khara - Rough	Sthūla- Large
Sajñēya- Called as		

A disease in which large rough nodule surrounded by very small nodules seen in the lids is called Vartma sharkara.

According to Vagbhata

वर्त्मनो अन्तः खरा रूक्षाः पिटिकाः सिकतोपमाः । सिकता वर्त्म ॥ (A. H.U. 8/18)

Vartmanó antaha- Within lids	Khara- Rough	
Rūksha- Dry	Pitika- Nodule	Sikatōpama- Like sand

Vagbhata has described the disease as Sikatāvartma in which multiple small nodules resembling sand particles are seen within lids.

Chikitsa

कुम्भीकिनीं शर्करां च तथैवोत्सङ्गिनीमपि । कल्पयित्वा तु शस्त्रेण लिखेत् पश्चादतन्द्रितः ॥ (S.U.13/16)

The treatment for Kumbheeka, Vartmasharkara and Utsangini are same

- a) Initially excision of the pidakas is done by sharp instruments.
- b) This should be followed by Lekhana karma.

SHUSHKĀRSHA
(Polyp of Palpebral conjunctiva)

It is Tridoshaja Chédana Sādhyā Vyādhi.

दीर्घोऽङ्कुरः खरः स्तब्धो दारुणो वर्त्मसम्भवः । व्याधिरेष समाख्यातः शुष्कार्श इति संज्ञितः ॥ (S.U.3/14)

Deerga- Long	Ankura- Sprout/projections	Khara-Rough
Stabdha- Immobile	Daruna- Troublesome	

Vartma Sambhava- Originates from lids **Vyadhiresha-** Disease is

Samākhyāta- Known as **Sanjñita-** Called as

The disease in which a long sprout like, rough, immobile troublesome projection occurs in the lids is called Shushkārshas.

Chikitsa

Chédana with mandalāgra shastra. The base of the shushkarsha should be excised using sharp instruments like mandalāgra shastra.

ANJANANĀMIKA (Stye)

It is Raktaja Bhedana Sādhyā Vyādhi.

दाह तोदवती ताम्रा पिडका वर्त्मसम्भवा । मृद्वी मन्दरुजा सूक्ष्मा ज्ञेया साऽञ्जननामिका ॥ (S.U. 3/15)

Dāha- Burning sensation	Tōdavati- Having pricking pain
Tāmra- Copper	Pidaka- Nodule
Mṛudvi- Soft	Maṇḍa ruja- Mild pain
Sookshma- Minute	Jñeya sa- That is known as.

A small, soft, copper coloured pidaka occurring in the vartma, associated with symptoms like burning sensation and mild pricking pain is known as Anjananāmika.

According to Acharya Vagbhata

The management of Pothaki is as follows

1. Lékhana.
2. Pratisarana with shunti, saindhava and pippali.
3. Prakshālana with ushnāmbu.
4. Sechana with kashāya prepared out of khadira, ādhaki and shigru.
5. Aschōtana with kashāya prepared out of haridra, daruharidra and yashtimadhu mixed with honey.
6. Aschōtana with decoction of tender leaves of āmra and jambu.
7. Anjana prepared from vidanga, lāksha, dāruharidra, twak, haratāla, manashila and honey.

VARTMA SHARKARA (SIKATA VARTMA)

(Lithiasis conjunctivae-A form of Trachoma)

Vartma sharkara is a Sannipātaja Lékhana Sādhya Vyādhi.

The word Sharkara or Sikata literally means Sugar or Sand particles. It denotes the size and shape of the pidakas in the lids.

पिडकाभिः सुसूक्ष्माभिर्घनाभिरभिसंवृता । पिडका या खरा स्थूला सा ज्ञेया वर्तशर्करा ॥ (S.U. 3/12)

Pidaka- Nodule	Susūkshma- Very small	Ghana- Hard
Abhisamvṛta - Surrounded by	Khara - Rough	Sthūla- Large
Sajpēya- Called as		

A disease in which large rough nodule surrounded by very small nodules seen in the lids is called Vartma sharkara.

According to Vagbhata

वर्तनो अन्तः खरा रुक्षाः पिटिकाः सिकतोपमाः । सिकता वर्त ॥ (A. H.U. 8/18)

Vartmanó antaha- Within lids	Khara- Rough	
Rūksha- Dry	Pitika- Nodule	Sikatōpama- Like sand

Vagbhata has described the disease as Sikatāvartma in which multiple small nodules resembling sand particles are seen within lids.

Chikitsa

कुम्भीकिनी शर्करां च तथैवोत्सङ्गिनीमपि । कल्पयित्वा तु शस्त्रेण लिखेत् पश्चादतन्द्रितः । (S.U.13/16)

The treatment for Kumbheeka, Vartmasharkara and Utsangini are same

- a) Initially excision of the pidakas is done by sharp instruments.
- b) This should be followed by Lekhana karma.

SHUSHKĀRSHA

(Polyp of Palpebral conjunctiva)

It is Tridoshaja Chédana Sādhya Vyādhi.

दीर्घोऽङ्कुरः खरः स्तब्धो दारुणो वर्तसम्भवः । व्याधिरेष समाख्यातः शुष्कार्श इति संज्ञितः ॥ (S.U.3/14)

Deergha- Long	Ankura- Sprout/projections	Khara-Rough
Stabdha- Immobile	Daruna- Troublesome	

Vartma Sambhava- Originates from lids Vyadhiresha- Disease is

Samākhyāta- Known as Sanjñita- Called as

The disease in which a long sprout like, rough, immobile troublesome projection occurs in the lids is called Shushkārshas.

Chikitsa

Chédana with mandalāgra shastra. The base of the shushkarsha should be excised using sharp instruments like mandalāgra shastra.

ANJANANĀMIKA (Stye)

It is Raktaja Bhedana Sādhya Vyādhi.

दाह तोदवती ताम्रा पिडका वर्तसम्भवा । मृद्वी मन्दरुजा सूक्ष्मा ज्ञेया साऽञ्जननामिका ॥ (S.U. 3/15)

Dāha- Burning sensation	Tōdavati- Having pricking pain
Tāmra- Copper	Pidaka- Nodule
Mṛudvi- Soft	Maṇḍa ruja- Mild pain
Sookshma- Minute	Jñeya sa- That is known as.

A small, soft, copper coloured pidaka occurring in the vartma, associated with symptoms like burning sensation and mild pricking pain is known as Anjananāmika.

According to Vagbhata (Raktaja)

मध्ये वा वर्त्मनो अन्ते वा कण्डुऋषाण्वती स्थिरा ।

मुद्ग मात्रा असृजा ताम्रा पिटिका अञ्जननामिका ॥ (A.H.U. 8/14)

Madhye- In the middle Vartmano ante- End of eyelid

Osha- Burning Rugwati- Painful

Mudga mātra- Size of green gram Asṛuja tāmra- Coppery red in colour

Pitika- Nodule.

A firm greengram sized red coloured pitika formed in the middle or end of eyelids is called as Anjananāmika. It is caused by the vitiation of rakta and is associated with symptoms like itching, burning sensation and pain.

Chikitsa

स्वित्रां भिन्नां विनिष्पीड्य भिषगञ्जननामिकाम् । शिलैलानतसिन्धूतैः सक्षौद्रैः प्रतिसारयेत् ॥ (S.U.14/6)

Steps to be followed

1. Swedana- Hot fomentation.
2. Bhedana- Incision to let out pus.
3. Nishpeedana Extraction of pus completely.
4. Pratisāraṇa with manahshila, ela, tagara, saindhava and honey.

Description of Anjananamika

According to Sushruta: External hordeolum

Vagbhata: Internal and External hordeolum

BAHALAVARTMA (Multiple Chalazion)

It is a Tridoshaja Lekhana Sādhya Vyādhi.

वर्त्मोपचीयते यस्य पिङ्काभिः समन्ततः । सवर्णाभिः समाभिश्च विद्याद्बलवत् ॥ (S.U.3/16)

Vartmopachīyate-Covers the lid due to swelling

Yasya- The Pidakābhihi- Nodule

Savarnābhihi- Same coloured pidika

Vidyāt- Called Tat-This is

Samantataha- From all sides

Samābhischa- Same shape

A condition in which pidakas of same shape and colour arises from all the sides of vartma forming a uniform swelling is called as Bahala Vartma.

According to Vagbhata

बहलं बहलैः मांसैः सवर्णैः चीयते समैः । (A.H.U. 8/19)

Bahala- Bulky

Māmsa- Muscular

Savarna- Same colour

Chīyate Samaihi- Spreads evenly.

Bahalavartma is characterized by muscular growths which are similar in colour and shape giving bulky appearance to the eyelid.

Chikitsa

Lekhana-Same as Pothaki

VARTMĀVABANDHA

(Imperfect closure of eye lids following inflammatory swelling or angioneurotic oedema.)

It is Sannipātaja Lékhana Sādhya Vyādhi.

कण्डुमताऽल्पतोदेन वर्त्मशोफेन यो नरः । न समं छादयेदक्षि भवेद्वन्धः स वर्त्मनः ॥ (S.U.3/17)

Kandumata- Itching

Alpatōdena- Mild pricking pain

Vartmashophēna- Oedema of eyelid

Yo naraha- In human beings

Na samam- Not equal

Chādayet- Close

Akshi- Eye

Bhabet- Takes place

Bandhaha sa vartmanaha- Is called as vartmāvabandha.

A disease characterized by oedema of the eyelids, associated with itching and mild pricking pain resulting in improper closure of eyelids in human beings is called as Vartmāvabandha.

Chikitsa

1. Same as Pothaki (Refer pothaki chikitsa)
2. Shōthahara chikitsa

KLISHTA VARTMA (Allergic conjunctivitis)

It is a Raktaja Lékhaṇa Sādhya Vyādhi.

यद्वर्तम वेदनं तात्र यद्वर्तं सममेव च । अकस्माच्च भवेद्रक्तं क्लिष्टवर्तं तदादिशेत् ॥ (S.U.3/18)

Mridu- Soft	Alpavédanam- Mild pain	Tāmram- Copper colour
Yadvartma- The eyelid	Samameva- Evenly	Cha-and
Akasmāt- Suddenly	Bhavet- Takes place.	

Klishta Vartma is a condition in which the eyelids which are soft & copper in colour with mild pain, suddenly becomes red in colour.

Chikitsa- Lékhaṇa

The treatment for Vartmāvabandha, Vartmaklishta, Vartma bahala and Pothaki are same.

VARTMA KARDAMA

(Inflamed lid with conjunctivitis)

It is a Sannipāthaja (kapha, pitta and rakta) Lékhaṇa Sādhya Vyādhi.

क्लिष्टं पुनः पिमयुतं विदहेच्छोणितं यदा । तदा क्लिन्नत्वमापन्नमुच्यते वर्तमकर्मः ॥ (S.U.3/19)

Klishtam- Klishta vartma	Punaha- Again	Pittayutam- With pitta
Vidahet- Inflammation	Shónitam- Blood	Yada- When
Tada- Then	Klinnatvam- Moistness	Aapannam- Attains

Vartmakardama is the progressive stage of klishta vartma wherein vitiated kaphayukta rakta again undergoes vidahana due to pitta leading to excessive moistness in eyelids.

According to Vagbhata

कृष्णं तु कर्मं कर्मोपमम् ॥ (A.H.U. 8/18)

Krishnam - Black

Kardamópamam- Moist like muddy clay.

Vartma kardama is a condition in which eyelids appear black and moist like muddy clay.

Chikitsa

- Lékhaṇa
- Vrana shothahara
- Treatment as in Abhishyanda is to be done.

SHYĀVA VARTMA

(Inflamed lids with conjunctivitis)

It is a Sannipataja Lékhaṇa Sādhya Vyādhi.

यद्वर्तं बाह्यतोऽन्तश्च श्यावं शूनं सवेदनम् । दाहकण्डूपरिक्लेदि श्याववर्तेति तन्मतम् ॥ (S.U.3/20)

Vartma- Eyelid	Bahyato- Outer	Anṭaha- Inside
Shyāva- Greyish/blackish	Shūna- Inflammation	
Védana- Pain	Dāha- Burning Sensation	
Kaṇdu- Itching	Parikledi- Sticky	Tanmatam- Called as

A condition in which the eyelids become grey or black in colour with painful swelling on both sides (internally and externally) associated with sticky discharge, itching and burning sensation is called as shyāva vartma.

According to Vagbhata

श्याव वर्तं मलैः सास्त्रैः श्यावं रुक् क्लेदं शोफवत् । (A.H.8/17)

Malaihi- Tridosha	Sāsrāihi- Along with rakta	Shyāvam- Greyish
Ruk- Pain	Kléda- Discharge/moistness	Shophavat- Swelling

Dosha- Tridosha and rakta

Shyāvavartma is a disease which occurs due to the vitiation of tridoshas along with rakta. It leads to painful swelling and greyish discolouration of the lids. Moistness is due to the discharge.

(Pain- Vāta, Burning sensation- Pitta, Moistness- Kapha)

Chikitsa

- Lékhaṇa and pratisāraṇa.
- Internal medicine to reduce the inflammation.

SHLISHTA VARTMA

श्लिष्टाख्यं वर्तनी श्लिष्टे कण्डू श्वयथु रागिणी । (A.H.U. 8/17)

Vartmani shlishte- Adhered lids **Kandu-** Itching
Shvayatu- Swelling **Rāgini-** Redness

The disease in which eyelids adhere together and is associated with itching, swelling and redness is called Shlishta vartma.

Chikitsa (A.H.U. 8/27)

- Lekhana

KLINNAVARTMA PRAKLINNA VARTMA
(Conjunctivitis)

It is a Kaphaja Bhesaja Sādhya Vyādhi.

अरुजं बाह्यतः शूनमन्तः क्लिन्नं स्रवत्यपि । कण्डूनिस्तोदभूयिष्ठं क्लिन्नवर्तं तदुच्यते ॥ (S.U. 3/21)

Arujam- Painless **Bahyataha-** Externally **Shoonam-** Swollen
Aṇṭaha- Inner surface **Klinnam-** Sticky **Sravatyapi-** Discharge
Kaṇḍu- Itching **Nistōda-** Pricking pain
Bhuyishta- More/severe **Taduchyate-** Called as

Klinna vartma is a disease of the lids characterized by painless swelling externally and sticky discharge internally. It is associated with symptoms like severe itching and pricking pain.

Few authors considered klinna and aklinna vartma as Pilla roga (S.U.3/21-22 Dalhana).

Chikitsa

- As kapha is the dominant dosha, Kapha hara chikitsa should be adopted.

AKLINNA VARTMA
(Ankyloblepharon)

It is a Tridoshaja Bhesaja Sādhya Vyādhi.

यस्य धौतानि धौतानि संबध्यन्ते पुनः पुनः । वर्तमान्यपरिपक्वानि विद्यादक्लिन्नवर्तं तत् ॥ (S.U.3/22)

Dhoutani- Washing

Punaha punaha- Again & again

Aparīpakvāni- Not suppurated

Aklinna vartma is a non suppurative condition where in eyelids stick together again and again even after repeated washing.

Chikitsa (Ashastrakruta)

- Tridosahara chikitsa.
- Sweda or grāhi aushadha

VĀTAHATA VARTMA
(Lagophthalmos or Ptosis)

It is a Vātaja Asādhya Vyādhi.

विमुक्तसन्धि निश्चेष्टं वर्तं यस्य न मील्यते । एतद्वातहतं विद्यात् सरुजं यदि वाऽरुजम् ॥ (S.U.3/23)

Vimukta- Loose, weak **Sandhi-** Junction
Nischeshtam- Not functioning **Na meelyate-** Unable to close
Etat- This is **Vidyat-** Called as **Sarujam-** With pain
Yadi vaa- Or **Arujam-** Pain less.

Vātahatavartma is a condition in which the patient is unable to close the eyelids. Here the loose/weak sandhi (vartma shukla sandhi, apanga/kaneenika sandhi) becomes non-functional. This disease may or may not be associated with pain.

According to Vagbhata's description, it can be correlated to drooping of eyelids (Ptosis)

वर्तं यत् न मील्यते ॥ विमुक्तसन्धि निश्चेष्टं हीनं वातहतं हि तत् । (A.H.U. 8/5)

Nimilyate- Closing eyelids **Vimukta sandhi-** Loosened/weakened joint
Nischeshta- Without movement (opening of lids) **Hina-** Weak.

The condition in which the eyelids are unable to do its function of opening due to the weakness of sandhi (kaneenika and apanga) is called as Vātahata vartma.

Chikitsa: Asādhya

LAGANA (Chalazion)

It is Kaphaja Bhédana Sādhya Vyādhī

अपाकः कठिनः स्थूलो ग्रन्थिर्वर्त्मभवोऽरुजः । सकण्डूः पिच्छिलः कोलप्रमाणो लगणस्तु सः । (S.U.3/27)

Apākaha- Non suppurative Katina- Hard Sthūla- Large

Granthi- Cystic growth Vartma Bhavo- In the vartma Aruja- Painless

Sa kandu- With itching Picchila- Sticky

Kōla Pramāna- Size of kola/badara.

Lagana is a large, non- suppurative, painless, hard, cystic swelling formed in the eyelid. Associated symptoms are itching and stickiness. The size of lagana is said to be similar to that of badara or kōla.

According to Vāgbhata

ग्रन्थिः पाण्डुः अरुक्पाकः कण्डूमान् कठिनः कफात् ।

कोल मात्रः स लगणः किञ्चित् अल्पः ततोऽथ वा ॥ (A.H.U.8/11)

Granthi- Cyst Pāndu- Pale Arukpākaha- Painless and non suppurative

Kandūmān- Itchy Katinaha- Hard Kōla Mātra- Size of kōla

Kinchith alpa tathōtha Va- Size of kola or less than that.

Lagana is a pale, hard, cystic swelling caused due to vitiation of kapha dosha. It is non suppurative, painless and is associated with itching. The size of Lagana is similar to badara (kola) or even less.

Bhavaprakasha names it as Nagana and Sharangadhara as Alagana

Chikitsa

रोचनाक्षरतुल्यानि पिप्पल्यः क्षौद्रमेव च । प्रतिसारणमेकैकं भिन्ने लगण इष्यते ॥

महत्यपि च युञ्जीत क्षारगन्नी विधिकोविदः । (S.U.14/5-6)

1. Bhedana- An incision on the lagana with Yrihimukha Shastra.

2. Pratisārana with gorochana, yavakshāra, tuttha, pippali and honey (in small cystic swelling).

3. Kshāra and Agnikarma (in large cystic swelling).

BISAVARTMA

(Porous Oedema of Eye lids)

It is Tridoshaja Bhedana Sādhya Vyādhī as per Sushruta.

According to Vagbhata it is Yāpya Vyadhi.

शूनं यद्वर्त्म बहुभिः सूक्ष्मैश्छिद्रैः समन्वितम् । विसं अन्तर्जल इव विसवर्त्मेति तन्मतम् ॥ (S.U.3/28)

Shūnam- Swelling

Yad- The

Vartma- Eye lid

Bahubhihi- Numerous

Sūkshma- Minute

Chidraihi- Pores

Samanvitam-Associated with Bisa- The stalk of lotus Antara- Inside

Jalam- Water

Iva- Like

Tanmatam- That is called as

Bisa vartma is a condition in which eyelids are swollen with numerous minute pores on it similar to stalk of lotus in water.

According to Vāgbhata

दोषैः वर्त्म बहिः शूनं यत् अन्तः सूक्ष्म खाचितम् ।

सस्त्रावम् अन्तः उदकम् बिसाभं विसवर्त्म तत् ॥ (A.H.U. 8/15)

Doshaihi- Due to tridoshas

Vartma bahihi shūnam-

Swelling on external surface of lid

Yad antam- Internally

Sūkshma- Minute

Khaachitam- Pores

Sa Srāvam- Discharge

Antaha- Internally

Udakam- Watery

Bisābham- Resembling lotus stalk.

The vitiated doshas produce swelling in the external surface of the lids.

It also produces constant discharge from the minute pores present in the inner surface of the eyelids. Since the discharge from the pores looks similar to water oozing out from the Bisa it is called as Bisa vartma.

Chikitsa: (S.U.14/3-4)

Line of treatment:

1. Swédana

2. Bhédana

17 S.T.-I

3. Avachurnana with saindhava, kāseesa, pippali, pushpanjana, manashila and ela.

4. Application of honey with ghee. 5. Bandhana (bandage).

If it doesn't respond to the above treatment pratisarana, kshāra & agni karma can be tried.

PAKSHMAKŌPA (Trichiasis with entropion)

Synonyms of pakshma kōpa- Upapakshmamāla, Parivaala (Acharya Dalhana)

It is Tridosha Yāpya Vyādhi.

दोषाः पक्ष्माशयगतास्तीक्ष्णाग्राणि खराणि च । निर्वर्तयन्ति पक्ष्माणि तैर्घृष्टं चाक्षि दूयते ॥
उद्धृतेरुद्धृतेः शान्तिः पक्ष्मभिश्चोपजायते । वातातपानलद्वेषी पक्ष्मकोपः स उच्यते ॥ (S.U. 3/29-30)

Doshāha- Tridosha	Pakshmāshaya- Root of eye lashes
Gata- Goes to	Teekshna- Sharp Agrani- Tip
Kharāni- Rough	Cha- And Nirvartayanti- Misdirected/inverted
Pakshmāni- Eyelashes	Tairgrushtani- Friction/foreign body sensation
Chakshi- In eyes	Duyate- Pain
Uddhrutair uddhrutaihi- Repeated extraction	
Shānti- Subsides	Pakshmaabhihi- In the eyelids
Upa jaayate- Takes place	Vata- Air
Ātapa- Sunlight	Anala- Heat
Dwēshi- Intolerance	Sa Uchyate- That is called as.

The vitiated tridoshas invades the root of eyelashes making them sharp, rough and inverted. The inverted lashes pricks the inner part of eye causing discomfort, pain and intolerance to air, sunlight and heat. The patient finds relief when cilia are epilated.

Vagbhata names it as Pakshmoparodha

पक्ष्मोपरोधे सङ्कोचो वर्त्मनां जायते तथा । खरता अन्तर्मुखत्वं च रोम्णाम् अन्यानि वा पुनः ॥
कण्टकैस्त्रिं तीक्ष्णाग्नेः घृष्टं तैर्लिख्यते । उच्यते च अनिलादिद्विदल्याहः शान्तिः उद्धृतेः ॥

(A.H.U. 8/21-22)

Saṅkōcho Vartmanām- Atrophy of lids Kharata- Roughness

Antarmukhatvam romānaam- The lashes direct inwards

Anyāni va punaha- New extra lashes grow Kantakairiva- Like thorns

Teekshnaagraihi Ghrushtam- The sharp edges of lashes rub against eye ball

Tairakshi shooyate- Hurts the eye Ushyate- Burning

Anilaadi dwidalpāhaha- Patient avoids air etc,

Shantihi uddrutaihi- Finds relief on removal of lash.

The atrophy of eyelids causes inversion of eyelashes. There will be extra growth of eye lashes which are rough and sharp. The sharp edges of these eyelashes pricks on to the inner surface of the eyes causing inflammation. Because of this, the patient is intolerant to air, heat and light and hence avoids it. On epilation the patient finds temporary relief.

Chikitsa

All four methods of treatment are explained for Pakshmakōpa

- 1) Shashtra
- 2) Agni
- 3) Kshāra
- 4) Aushadhi.

Shastrakarma

1. The patient who has undergone snehana (abhyantara & bāhya) is made to sit comfortably.
2. Then a barley seed shaped (yavākriti) incision is made at a site 2/3rd part below the eyebrows and 1/3rd part above the eyelid margin using tiryak shashtra.
3. The site of incision is sutured with tail hair of horse (ashwa baala). The lid is then lifted above with the suture thread and placed over lalaata and bandhana is done with a cloth. (By this procedure, the lids are elevated and doesn't prick on to the inner surface of the eyes).
4. Wound management is done by applying ghee & honey over it.
5. When healing of wound is attained, suture is removed.

Agni-Kshāra Karma

If the disease does not subside with Shastra karma then, Agni and Kshāra karma can be done at the same site.

- If all treatment measures fail, then extra line of lashes should be excised using badisha yantra.
- A heated fine needle can be used to burn the roots of the eye lashes.
- Pratisāraṇa should be done with haritaki or tuvaraka.
- As it is a Yāpya vyādhi, virechana, aschōtana, dhūmapāna, nasya, lepana, anjana, snehana, rasakriya etc can also be tried.

KRUCHRONMEELANA**(Blepharospasm)**

(Kṛichra = difficulty, Unmeelana = in opening)

चलस्तत्र प्राप्य वर्त्माश्रयाः सिराः । सुप्तोत्थितस्य कुरुते वर्त्त स्तम्भं सवेदनम् ॥
पांशुपूर्णाभ नेत्रत्वं कृच्छ्रोन्मीलनं अश्रु च ।

विमर्दनात् स्याच्च शमः कृच्छ्रोन्मीलं वदन्ति तत् ॥ (A.H.U.8/3-4)

Chala- Vāta **Suptotthita-** Arising from sleep **Stambha-** Stiff
Savēdana- Painful **Paamshupoornaabha-** Feeling of eye being filled with sand
Kṛuchronmeelana- Difficulty to open eyes **Ashru-** Lacrimation/discharge
Vimardanāt shamaha- Finds relief on rubbing **Dosha-** Vāta

The vitiated vāta takes āshraya in the varmagata sirās producing symptoms such as pain, foreign body sensation (eyes filled with sand), difficulty in opening the eyes and discharge on arising from sleep. The person finds relief on rubbing the eyes. This condition is called kruchronmeelana.

Chikitsa (A.H.U.9/1)

- Vātahara chikitsa like snigdha nasya, snaihika dhuma, anjana etc.
- Drāksha ghrita prepared out of purāna ghrita, drāksha kalka, water and sugar.

KUKŪNAKA (Ophthalmia neonatorum)

Sushruta has mentioned Kukūnaka in Nayanābhighata pratisheda Adhyaya and not included in the 76 Netra rogas.

कुक्कुणकः शिशोरेव दन्तोत्पत्ति निमित्तजः । स्यात् तेन शिशुः उच्छून ताम्राक्षो वीक्षणाक्षमः ॥
सर्वत्र शूल पैच्छल्यः कर्ण नासा अक्षि मर्दनः । (A.H.U.8/19-20)

Shishoreva- Occurs in children only **Dantotpatti nimittaja-** Due to teeth eruption
Uchchuna- Swelling of eyes **Taamraaksho-** Copper colour
Veekshanaakshamam- Inability to see **Shoola-** Pain **Paicchilya-** Stickiness
Karna naasa akshi mardana- Child often rubs ear-nose-eyes.

Kukunaka is an eye lid disorder occurring in children during eruption of teeth. The following signs and symptoms are seen:

- Swelling of eyes
- Inability to see properly
- Sticky discharge
- Coppery or redness of eye
- Pain in the lids
- Itching of ear, nose and eye.

According to Sushruta (S.U.19/8-10)

Sushruta has considered the disease kukunaka as vartma roga. Vitiated stanya causes aggravation of kapha, vata, pitta and rakta causing kukūnaka in children.

Following symptoms are seen:

- Continuous rubbing of eyes, nose and forehead
- Photophobia
- Excessive lacrimation or discharge from the eyes.

Chikitsa

Since the child feeds on breast milk, both the mother and the child should be treated in kukunaka.

For Mother (Dhatri) (A.H.U.9/24-26)

- Snehapāna with ghrita prepared using khadira, triphala, nimbapatra.
- Vamana using pippali, yashti, sarshapa and saindhava lavana.
- Virechana with kashāya prepared out of abhaya, pippali and drāksha.
- Stana lepa- Application of paste of musta, haridra, daruharidra and pippali over the breast.

- Dhūpana- Sarshapa with ghee is used for fumigation of breast.
- Kashāya of patōla, musta, drāksha, gudūchi and triphala should be given internally after shodhana.

For Infant (A.H.U.9/27-31)

Since kapha is the main vitiated dosha in children, it should be expelled out by vamaṇa karma.

Other treatments

- Lékhana of vartma or Raktamokshana with jalouka.
- Pariséka with kashāya prepared of dhātri, ashmantaka and jambupatra.
- Vamaṇa with apāmārga beeja, krishna, saindhava lavana, madhu and stanya.
- Aschótana with triphala ghrita, guduchi ghrita.
- Anjana with ela, rasonadi varti.
- Pratisarana with trikatu, madhu, saindhava lavana or rasanjana.

Special Anjana yogas for kukūṇaka

- I. Nepalājadyanjanā (manashila, maricha, shankanābhi, rasanjana, saindhava, guda, makshika).
- II. Madhurasadhyanjana (murva, yashtimadhu etc.)
- III. Gutikanjana (trikatu, palāndu, yashti, saindhava lavana, laksha, gairika).

KUṆCHANA (Blepharospasm)

Bhavaprakasha and Yogaratnakara have mentioned this disease.

वाताद्या वर्त्त संकोचं जनयन्ति मला यदा । तदा द्रष्टुं न शक्नोति कुञ्चनं नाम तद्विदुः॥ (Y.R.)

The disease in which there is difficulty in vision due to constriction (closure) of the eye lids because of the vitiation of vatādi doshās is called Kuṇchana.

Chikitsa

No specific treatment is mentioned for kunchana. Therefore based on dosha dushti treatment can be given.

ALAJI

(Internal hordeolum/Style)

Sushruta mentions the term 'Alaji' in Sandhigata roga where as Vagbhata has mentioned it in Vartmagata roga.

कनीनके बहिः वर्त्त कठिनो ग्रन्थिरुन्नतः ।

ताम्रः पक्वो अस्त्रं पूयस्तुत् अलजी आध्यायते मुहुः ॥ (A.H.U.8/23)

Kaneenake- Inner canthus

Bahi vartma- External surface of lid

Kathino granthi- Hard swelling

Unnata- Raised

Taamra- Copper coloured

Pakwa- Suppurating

Asra pooyasrut- Discharges blood and pus

Aadhmayante muhuhu- Fills up again.

A hard, raised, copper coloured, cystic swelling present in the kaneenika sandhi on the external surface of the eyelid is called Alaji. On suppuration, there will be discharge of pus and blood which gets filled up again.

Chikitsa (A.S.U.12/15)

Bhédana, lekhana, kshāra karma, agnikarma and vṛanópachāra.

Chapter

4B

- Varthma arbudam
- Nimésha
- Arshóvartma
- Utklishta varthma
- Pakshmathāta
- Shonitārsha

VARTHMA ARBUDAM (Lid Tumour)

It is a Tridoshaja Chédana Sādhya Vyādhi.

वर्तमानस्थं विषमं ग्रन्थिभूतमवेदनम् । विज्ञेयमर्बुदं पुंसां सरक्तमवलम्बितम् ॥ (S.U. 3/24)

Vartma- Eye lid	Antarastham- Inner aspect
Vishamam- Uneven/Irregular	Granthibhutam- Cystic growth
Avedanam- Painless	Vijneyam- Is known as
Pumsam- In human beings	Saraktam- Hyperaemic
Avalambitam- Hanging down	

An irregularly shaped, hyperaemic, painless cystic growth hanging from the inner aspect of the lid is known as Arbuda.

According to Vagbhata

वर्तन्ति मांस पिण्डाभः श्रयथुः ग्रथितो अरुजः ।
सार्धैः स्यात् अर्बुदो दोषैः विषमो बाह्यतः चलः ॥ (A.H.U. 8/24)

Vartmanṭa- Inner aspect of lid	Māmsa pindābha- Resembles bolus of flesh	
Shvayathu- Swelling	Grathito- Thickened	Aruja- Painless
Sasraihi syat doshaihi vishamo- Due to vitiation of tridosha along with rakta		
Bahyataha chala- Mobile externally.		

Arbuda is a painless, irregularly shaped, thickened muscular swelling resembling a bolus of flesh seen in the inner aspect of eyelid which is mobile externally (on palpation). It is caused by the vitiation of rakta and tridoshas.

Vartmagata Roga

143

Chikitsa

This condition is managed surgically by Chédana karma. (As explained in the chapter of Shashtra Karma).

UTKLISHTA VARTMA (Allergic Conjunctivitis)

This condition is mentioned only by Acharya Vāgbhata. Here 'Utklishta' means excessive vitiation of doshas.

यत् वर्तमान्त्विष्टम् उत्क्लिष्टम् अकस्मात् म्लानतामियात् ।
रक्त दोष त्रय उत्क्लेशात् भवति उत्क्लिष्ट वर्तम् तत् ॥ (A.H.U. 8/16)

Utklishta- Aggravation (vitiation) **Akasmāt-** Suddenly without reason
Mlanatamiyat- Becomes weak (withered)

Raktadosha trayotkleshat- Due to vitiation of rakta and tridosha.

Utklishta vartma is an inflammatory condition of the eyelids which has sudden onset caused due to vitiation of rakta and tridoshas.

Other features of Utklishta vartma are:

तथोत्क्लिष्टं राजिमत् स्पर्शनाक्षमम् । (A.H.U.8/12)

- **Rājimat-** Linear marks on lids (blood vessels)
- **Sparshanakshamam-** Tenderness

On the basis of the involved dosha and its signs and symptoms, Utklishta vartma is classified into four types:-

1. Pittōtklishta
2. Kaphotklišhta
3. Raktotklišhta
4. Sannipātotklišhta

1. PITTOTKLISHTA

सदाह क्लेद निस्तोदं रक्ताभं स्पर्शन अक्षमम् ।
पित्तेन जायते वर्तम् पित्तोत्क्लिष्टं उच्यते तत् ॥ (A.H.U. 8/7)

Sadāha- Burning sensation **Klēda-** Discharge/moistness **Nistōda-** Pricking pain

Raktābha- Redness **Sparshanakshamam-** Tenderness

Pittotklišhta is a condition in which vitiation of pitta causes reddish discolouration of the vartma. It is associated with symptoms such as burning sensation, discharge, pricking pain and tenderness.

18 S.T.-I

Chikitsa (A.H.U.9/16-18)

1. Snehapāna- Madhura skanda dravya siddha ghrita.
2. Sirāmokshana
3. Virechana- Trivrit
4. Lekhana
5. Kshālana- Yashtimadhu kashāya.
6. Séka- Chandana ksheera paka.

2. KAPHÓTKLISHTA

कफोत्क्लिष्टं भवेद्वर्णं स्तम्भ क्लेद उपदेहवत् । (A.H.U.8/10)

Stambha- Stiffness

Kléda- Unctuous substance

Upadeha- Coating

In kaphotklishta, the eye lids becomes stiff and coated with unctuous substance. It is caused due to vitiation of Kapha.

It can be considered as a stage of kaphaja abhishyanda.

Chikitsa (A.H.U.9/22-23)

1. Lekhana
2. Pratisārana- saindhava, kaseesa, manashila, pippali, rasānjana with madhu.
3. Vamana
4. Anjana
5. Nasya and all other kaphahara therapies should be done.

3. RAKTÓTKLISHTA

In Raktotklishta, the blood vessels look prominent, there will be severe pain and photophobia.

4. SANNIPATÓTKLISHTA

In this all the symptoms of tridoshas are seen.

SIGNS & SYMPTOMS OF UTKLISHTAS

Clinical features	Pittótklishta	Kaphótklishta	Raktótklishta	Sannipatótklishta
Shlaishmika Kala	Red	Watery	Reddish & more prominent	Watery reddish
Discharge	Present	Mild	Nil	Present
Pain	Pricking	Mild	Severe	Moderate
Special features	Burning sensation	Lids become stiff and are coated with Kleda	Photophobia	All the symptoms

NIMÉSHA

(Excessive blinking of Eye)

It is a Vātaja Asādhya Vyādhi.

निमेषणीः सिरा वायुः प्रविष्टो वर्त्मसंश्रयाः । चालयत्यति वर्त्मानि निमेषः स गदो मतः॥ (S.U.3/25)

Nimeshani sira- Branches of 3rd cranial nerve **Pravishto-** Vitiated vayu enters

Vartmasamshraya- Localizes in the eye lids **Chaalayati-** Moves

Ati- Excessive

Vartma- Eye lids

Sa gado mataha- That disease called as

The disease in which vitiated vāyu enters nimeshani siras and get localized in the eyelids bringing about excessive movement of the lids is called as Nimesha.

According to Vāgbhata

चालयन् वर्त्मनी वायुः निमेष उन्मेषणं मुहुः । करोति अरुङ् निमेषोऽसौ.....॥ (A.H.U.8/5)

Chaalayan- Movement **Nimesha unmeshanam-** Closing and opening of lids

Muhuhu- Repeatedly **Aruk-** Painless.

Excessive movement of the eyelids like closing and opening caused due to vitiation of vāta is called as Nimesha. It is a painless condition.

Chikitsa

It is an Asādhya vyādhi

PAKSHMASHĀTA (Madarosis)

It is a disease described by Achārya Vāgbhata in which there will be falling of eyelashes.

करोति कण्डूं दाहं च पित्तं पक्ष्मान्तम् आस्थितम् ।
पक्ष्मणां शान्तनं चानु पक्ष्मशातं वदन्ति तम् ॥ (A.H.U.8/8)

Kandu- Itching **Dāha-** Burning sensation **Pakshmaantam-** Root of eyelashes
Asthitam- Lodged

Pakshmanaam shatanam- Falling of eye lash.

The disease in which the vitiated pitta gets lodged in the root of the eyelashes resulting in itching, burning and falling of eyelashes is called as pakshmashāta.

Chikitsa (A.H.U.9/18-20)

- I. 'Kuttana'- A procedure of pricking at the root of eyelashes with the help of needle.
- II. Jaloukavacharana is done at the root of eyelashes
- III. Vamana with ikshu rasa or ksheera
- IV. Nasya with ghrita prepared out of madhura sheeta dravyas
- V. Pushpakāseesanjana- The powder of pushpakaseesa is given bhāvana with tulasi swarasa in copper vessel for ten days.

ARSHOVARTMA/VARTMA ARSHA

(Papillary form of Trachoma)

It is a Sannipātaja (Sushruta), Raktaja (Vāgbhata) Chedhana Sādhya Vyādhi.

एवार्कबीजप्रतिमाः पिडका मन्दवेदनाः । सूक्ष्माः खराश्च वर्त्मस्थास्तदशोवर्त्म कीर्त्यन्ते ॥ (S.U.3/13)

Ervaru bija pratima- Like seeds of cucumber **Pidaka-** Nodule

Maṇḍa vėdāna- Mild pain **Sookshma-** Minute **Khara-** Rough

Cha- and **Vartmastha-** In the eyelid **Tat-** That **Keertyate-** Called as

Small or minute, rough and slightly painful pidakas resembling the seeds of cucumber occurring in the eyelids is known as Arshōvartma.

According to Vagbhata (It is Raktaja Vyādhi)

अशो अधिमांसं वर्त्मन्तः स्तब्धं स्निग्धं सदाह रुक् ।
रक्तं रक्तेन तत् स्रावि छिन्नं छिन्नं च वर्धते ॥ (A.H.U.8/13)

Adhimāmsa- Extra muscular growth

Stabdha- Immobile

Snigdha- Unctuous

Ruḥ- Pain

Raktasrāvi- Bleeding

Chinnam chinnam cha vardhate- Regrows after excision.

The polyp like immobile, unctuous, red coloured extra muscular growth occurring within the lids is called Arshōvartma. It is associated with pain, burning sensation and bleeding. The peculiar characteristic feature of Arshōvartma is that it will regrow even after excision.

Chikitsa

Sushruta: Chėdana with Mandalagra shastra (Refer Chapter Ashta vidha shastra karma).

Vagbhata: Asādhya and hence should not be treated.

SHONITĀRSHA (Cancer of Lid/Naevus/Warts)

It is a Raktaja Asādhya Vyādhi

छिन्नाश्छिन्नाविवर्धन्ते वर्त्मस्था मृदवोऽङ्गुराः । दाहकण्डूरुजोपेतास्तेऽर्शाः शोणितसम्भवाः ॥ (S.U.3/26)

Chinnaha Chinnaha- Repeated excision

Vivardhante- Grows again

Vartmastha- In the eyelid **Mrudu-** Soft

Ankura- Sprouts/growth

Dāha- Burning

Kaṇḍu- Itching

Rujopeta- Associated with pain

Sthe- These are

Arsha- Tumour (warts)

Shonita sambhava- Originated from rakta.

Soft, painful growths associated with itching and burning sensation occurring in the vartma due to the vitiation of rakta is called Shonita arsha. This recur even after repeated excision.

Chikitsa

It is an Asādhya Vyādhi.

Chapter

4c

- Applied anatomy of Eye Lids
- Internal Hordeolum
- Trachoma

- Hordeolum Externum
- Ptosis
- Entropion, Ectropion

Applied anatomy of Eyelids

Eye lids are made up of the following layers from anterior to posterior:

- **Cutaneous layer:** It consists the skin of the eyelid which is extremely delicate and elastic.
- **Subcutaneous layer:** Underneath the skin, is the loose areolar tissue which does not contain any fat. Due to this, accumulation of oedematous fluid or blood takes place.
- **Layer of striated muscle:** It consists of oval sheet of concentric muscle fibres covering the lids called orbicularis muscle. It helps in closing the eyelids and is supplied by zygomatic branch of facial nerve. Therefore lagophthalmos occurs due to paralysis of facial nerve. The upper lid also contain levator palpebrae superioris muscle (LPS). It raises the upper lid and is supplied by upper division of oculomotor nerve.
- **Submuscular areolar tissue:** It is a layer of loose tissue in which nerves and vessels lie. Therefore to anaesthetise lids, injections are given here.
- **Fibrous layer:** It forms the frame work of lids and consists of two parts : the central tarsal plate and peripheral septum orbitale which is perforated by vessels and nerves entering the lids from the orbit.
- **Layer of non striated muscle fibres:** It consists of palpebral muscle of Muller which lies deep to the septum orbitale and is supplied by sympathetic fibres.
- **Conjunctiva :** The part of conjunctiva which lines the lids are called palpebral conjunctiva.

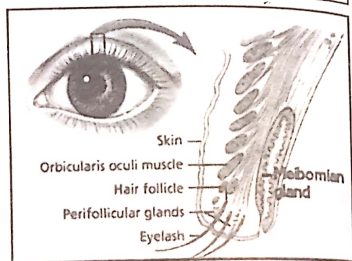


Fig. 4.1

Glands of eyelids

- **Meibomian glands:** They are also known as tarsal glands and are embedded in the tarsal plates vertically. They are about 30-40 in the upper lid and 20-30 in the lower lid. They are modified sebaceous glands and their ducts open at the lid margin. Their secretion constitutes the oily layer of tear film.
- **Gland of Zeis :** They are also sebaceous glands situated on the margin and open into the follicles of the eyelashes.
- **Glands of Moll:** These are modified sweat glands. They lie between the cilia on the lid margin. They open into the hair follicles or into the duct of Zeis gland.

The eye lid margin : It is a thick border with anterior rounded and posterior sharp margin which lies in close contact with the eyeball, it consists of the eye lashes which are arranged in 2-3 rows in the upper and 1-2 rows in the lower lid.

Blood supply of the lids

Arteries

- a. Lacrimal and palpebral branches of the ophthalmic artery.
- b. The facial artery
- c. The superficial temporal artery
- d. The infra-orbital artery

Venous drainage - the veins empty into

- a. Ophthalmic vein
- b. Temporal vein
- c. Facial vein

Lymphatic drainage: The lymphatics from the outer half of the lids drain into the pre-auricular lymph glands and those from the inner half to the submaxillary lymph nodes.

Nerve supply

Motor nerves: Facial, oculomotor and sympathetic fibres.

Sensory nerve supply: Branches of trigeminal nerve such as lacrimal, supra orbital, supra trochlear for upper lid and infratrochlear, infra orbital for lower lid.

HORDEOLUM EXTERNUM OR STYE

It is a condition where there is acute suppuration and inflammation of glands of zies or moll. Usually a single styte occurs but occasionally there may be multiple.

Etiology

- Age: It can occur in any age, but is common in children and young adults.
- Eye strain due to refractive errors, constant rubbing of eyes, chronic blepharitis.
- Metabolic factors: Diabetes, debility and excessive intake of carbohydrate.

Causative organism

Coagulase positive staphylococcus aureus

Symptoms

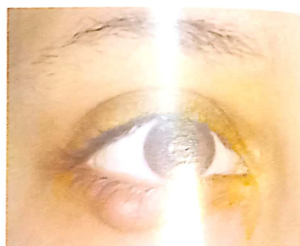
- Acute pain and swelling in the lid margin
- Mild watering
- Photophobia

The signs can be understood in two stages

1. Stage of cellulitis: in which the swelling at the lid margin is localized, hard, red and tender with marked oedema.
2. Stage of abscess formation: in which a visible pus point on the lid margin i.e. the base of the affected cilia.

Treatment

- In the stage of cellulitis- Hot compresses are useful.
- In the stage of abscess formation- Epilation (removal) of the involved cilia to drain pus.
- In large abscess- Surgical incision.
- Topical antibiotics in the form of eyedrops and eye ointments.
- Oral anti inflammatory and antibiotics to relieve pain, oedema and infection.



Fig

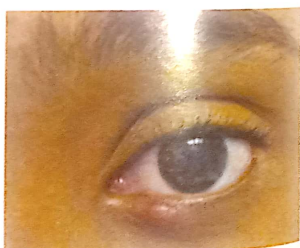


Fig. 4.3

CHALAZION

Chalazion is a chronic sterile granulomatous inflammatory lesion of the meibomian gland. A chalazion secondarily infected is referred to as an internal hordeolum. It is also called as tarsal or meibomian cyst. (Fig. 4.3)

Pathology: A low grade infection, usually staphylococcal, enters through a duct of meibomian gland. As a result there is infiltration of the wall of the duct with leucocytes and proliferation of epithelium of the duct. Thus the duct gets blocked and the meibomian secretion accumulates and causes enlargement of the gland.

Symptoms

- Mild irritation and heaviness in the lids.
- Painless swelling in the eyelid gradually increasing in size.

Signs

- Small, cystic swelling of the size of pea on the lid, away from the lid margin.
- Swelling is not tender, is fixed to the tarsus, with freely moving skin over it.
- No sign of inflammation.
- On everting the lid, the palpebral conjunctiva where the chalazion points appear velvety red or purple.
- Marginal chalazion, occurring occasionally may be present as small reddish grey nodule on the lid margin.

Treatment

- In small and soft chalazion, conservative treatments such as hot fomentation, topical antibiotics, oral anti inflammatory drugs and intra lesional steroidal injections are indicated.
- In bigger chalazion, incision and curettage should be done. An incision is made vertically on the conjunctival side or horizontally on the skin side. Then the contents are scooped out. Post operative care is done by administering proper antibiotics and anti-inflammatory drugs.

INTERNAL HORDEOLUM

It is the suppurative inflammation of a meibomian gland due to staphylococcus. It is also often called a suppurated chalazion. Sometimes it may be caused due to secondary infection of a chalazion.

Etiology: Same as external hordeolum.

Symptoms: Same as external hordeolum but are more intense.

Signs

Similar to external hordeolum, but the pus points are seen on the tarsal conjunctiva and not on the root of eyelash.

Treatment

- Hot compresses and broad spectrum antibiotic orally.
- Vertical incision on the tarsal conjunctiva to drain pus.

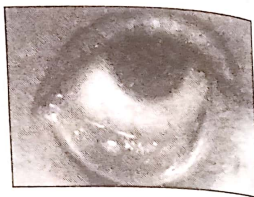

Fig. 4.4

PTOSIS

Normally upper one-sixth i.e. about 2 mm of the cornea is covered by the upper lid. Abnormal drooping of the upper eye lid below its normal position is called 'Ptosis'.

Types and etiology of Ptosis

1. **Congenital ptosis:** It is caused due to the congenital weakness or mal development of levator palpebrae superioris (LPS).

2. **Acquired ptosis**

Based on the cause it is classified as :

- Neurogenic or paralytic ptosis :** caused due to complete or partial 3rd nerve palsy and Horner's syndrome.
- Myogenic ptosis :** caused due to
 - Trauma to the levator muscle
 - Muscular dystrophy of levator muscle
 - Myasthenia gravis
- Aponeurotic ptosis:** caused by a defect in the levator aponeurosis.
- Mechanical ptosis:** caused due to weight of the upper lid as result of oedema, inflammation, hypertrophy or tumour.

Signs:

- The upper lid covers the cornea more than normal.
- Palpebral fissure is narrower than normal.
- On an attempt to elevate the upper lid, there is elevation of the eyebrow and wrinkling of the skin of the forehead due to hyperaction of the frontalis muscle.
- Head is tilted backwards so as to draw the lid upwards beyond the pupillary area.



Fig. 4.5

Treatment

- For acquired ptosis the cause must be treated.
- For congenital ptosis, surgical procedures are necessary.

Surgical procedures in Ptosis

- Tarso-conjunctivo-mullerectomy (Fasanella-servat operation)-** It is indicated in cases having mild ptosis and good levator function. The upper lid is everted and the upper tarsal border along with its attached muller's muscle and conjunctiva are resected (the muscle is shortened).
- Levator resection-** It is indicated in moderate and severe cases of ptosis. It is contra indicated in patients with poor levator function. In this the required amount of levator muscle is resected.
- Frontalis sling operation-** It is performed in patients having severe ptosis with no levator function. In this operation the lid is anchored to frontalis muscle via sling.

TRACHOMA

The word 'Trachoma' comes from the Greek word for 'rough' since the surface conjunctiva appears rough in cases of chronic trachoma.

Trachoma is a kind of keratoconjunctivitis i.e. the cornea and conjunctiva will be affected simultaneously. It is characterized by mixed follicular and papillary response of conjunctival tissue. It is one of the leading cause of preventable blindness in the world.

Etiology

Causative agent: Chlamydia or Bedsonia group of organisms.

- Age: Usually children in endemic areas.
- Sex: Females are affected more, both in number and severity.
- Socio economic status: Usually poorer classes are affected due to unhygienic conditions.
- Climate: Common in countries with dry and dusty weather.

Mode of infection

The infection spreads by contamination with the conjunctival discharge through fingers, towels or flies.

Symptoms

- Mild foreign body sensation in the eyes.
- Lacrimation.
- Mucoid or mucopurulent discharge.

Signs

Signs of trachoma can be categorized under two headings, i.e. 1. Conjunctival and 2. Corneal signs.

Mac Callan has divided trachoma into four stages.

Stage I and II show the following changes

Changes in conjunctiva

- Congestion in bulbar and palpebral conjunctiva.
- Formation of papillae in the upper tarsal conjunctiva and fornix. The conjunctiva looks velvety in appearance.
- Follicle formation is characteristic lesion. They commonly appear in the conjunctiva of the upper tarsus and fornix but may also be present in lower fornix and bulbar conjunctiva.

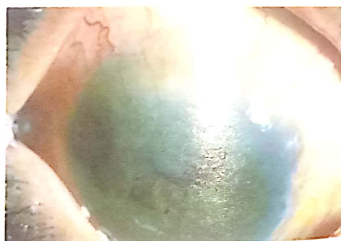


Fig. 4.7

Changes in the cornea

- Epithelial keratitis i.e. keratitis affecting the epithelium only. This occurs in the upper part of cornea.

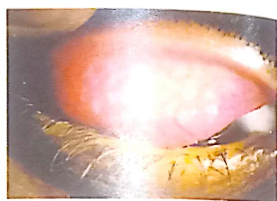

Fig. 4.6

- Trachomatous pannus- This vascularized infiltrate, known as pannus is limited first at the upper part of the cornea, but in course of time may appear all around the limbus.
- Corneal ulcers- Small ulcers may develop at the advancing edge of the pannus, causing much lacrimation and photophobia.

Stage III-Stage of cicatrization

It is a stage of cicatrization when healing starts. Trachoma is healed by cicatrization. The first evidence of cicatrization is seen in the upper lids where white scar is formed. The follicles and conjunctiva undergo atrophic changes and blood vessels get constricted. In the cornea the pannus retrogresses, leaving behind a corneal haze. The corneal ulcers heal leaving facets, which cause great disturbance in vision.

Stage IV-Stage of complications

- Entropion of the upper lid, Trichiasis i.e. misdirection of the eyelashes.
- Chalazion or Symblepharon formation.
- Corneal opacities.
- Pseudo ptosis due to the thickening of the upper lid.

W.H.O. grading of Trachoma (FISTO)

1. TF- Trachomatous inflammation (follicular): five or more follicles(>0.5mm) on the superior tarsus.
2. TI- Trachomatous inflammation (intense): diffuse involvement of the tarsal conjunctiva, obscuring 50% or more of the normal deep tarsal vessels, papillae are present.
3. TS- Trachomatous conjunctival scarring: easily visible fibrous white tarsal bands.
4. TT- Trachomatous trichiasis: atleast one lash touching the globe.
5. CO- Corneal opacity sufficient to blur details of atleast part of the papillary margin.

Diagnosis

Clinical diagnosis is made from its typical signs. Conjunctival cytology is one of the common test indicated.

Management

The SAFE strategy for Trachoma management supported by WHO.

- Surgery for treating entropion and trichiasis.
- Antibiotics should be administered to those affected and to all family members. A single dose of azithromycin (20 mg/kg) is the drug of choice. Erythromycin 500 mg and topical 1% tetracycline ointment.
- Facial cleanliness is a preventive measure.
- Environment improvement.

TRICHIASIS

This is a condition wherein the eyelashes are misdirected inwards so as to rub against the eye ball with normal position of the lid margin.

Etiology

- Cicatrizing trachoma
- Ulcerative blepharitis
- Healed membranous conjunctivitis
- Externum hordeolum
- Mechanical injuries, burns and operative scar on the lid margin.

Symptoms

- Foreign body sensation
- Photophobia
- Lacrimation
- Pain

Signs

- Ciliary congestion
- Reflex blepharospasm
- Superficial opacities and vascularization of the cornea
- Corneal ulcer

Treatment

1. Epilation- Mechanical removal of misdirected cilia with epilation forceps.
2. Electrolysis- Method of destroying the lash follicle by electric current.

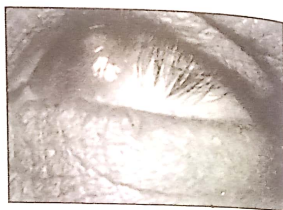


Fig. 4.8

3. Cryoepilation- A cryoprobe (-20 degree C) is applied for 20 - 25 seconds. It is very effective in eliminating profuse lashes.
4. Surgical correction is indicated when many cilia are misdirected.

ENTROPION

It is a condition in which the lid margin turns inwards causing the lashes to rub against the eye.

Causes of entropion

A. Congenital

It is seen since birth and is usually associated with microphthalmos and anophthalmos conditions of eye.

B. Acquired

- **Spastic entropion-** It develops typically in a case of blepharospasm due to any cause, particularly chronic irritative corneal condition. It also occurs after prolonged bandaging of the eye.
- **Mechanical entropion-** It occurs due to lack of support provided by the globe to the lids, as seen in conditions like phthisis bulbi, enophthalmos or after enucleation.
- **Senile entropion-** It is the commonest type usually affecting the lower lid. There is lack of support of the eyelid due to disappearance of orbital fat and also due to atrophic and inelastic condition of the skin in senility.
- **Cicatricial entropion-** The entropion occurs due to contraction of the conjunctival scar as in trachoma and burns. Upper lid is usually affected.

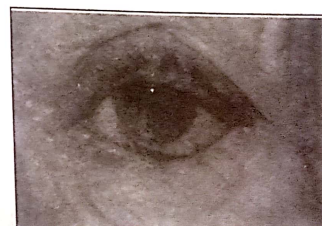


Fig. 4.9

Symptoms

Occurs due to rubbing of the cilia against the cornea and conjunctiva. These include foreign body sensation, irritation, lacrimation and photophobia.

Signs

On examination the lid margins are found turned inwards.

Treatment

It is treated surgically based on any of the following principles:

- Altering the direction of the lashes.
- Transplanting the lashes.
- Straightening the distorted tarsus.

(Simplest operation is the skin muscle operation in which an elliptical area of the loose skin and the underlying orbicularis oculi muscle are resected).

ECTROPION

It is a condition in which the lid margin rolls outwards. i.e. becomes everted.

Causes of ectropion

- **Spastic ectropion**- It occurs due to powerful contraction of the orbicularis muscle, when the skin is elastic and the eyeball is prominent. Both lids may be affected.
- **Senile ectropion**- Usually only the lower lid is affected due to laxity of the tissues of the lid and due to loss of tone of the orbicularis muscle in old age.
- **Paralytic ectropion**- It mainly occurs in the lower lid as a result of weakness of the orbicularis muscle due to paralysis of the facial nerve.
- **Mechanical ectropion**- It is caused by the weight of a mass in the eyelid e.g. tumour or by the pressure on the eyelid from behind as in proptosis. The lower lid is usually affected.
- **Cicatricial ectropion**- It follows burns, ulcers, trauma or skin diseases of the eyelid.



Fig. 4.10

Symptoms

Epiphora is the main symptom.

Signs

Lid margin is rolled outwards. Depending on the degree of outrolling, ectropion can be divided into three grades:

Grade I- Only punctum is everted.

Grade II- Lid margin is everted and palpebral conjunctiva is visible.

Grade III- The fornix is also visible.

Treatment

The method of treatment depends on the underlying etiology. Surgical management of the ectropion is as follows:

1. Senile ectropion is treated with horizontal lid shortening. This is achieved either by excision of a tarso-conjunctival wedge or with a lateral canthal sling procedure.
2. Mild localized cicatricial ectropion is treated surgically by excision of the offending scar tissue combined with a procedure that lengthens vertical skin deficiency, such as Z-plasty.

Another surgical procedure indicated in mild degree ectropion is V-Y operation. In this a V-shaped incision is given, skin is undermined and suturing is done in a Y-shaped pattern.

3. In Paralytic ectropion, temporary treatments include:

- Lubrication with tear substitutes
- Botulinum toxin injections into levator to induce temporary ptosis
- Temporary tarsorrhaphy- a procedure in which the upper and lower lids are sutured together.

Permanent treatment: include procedures like Medial canthoplasty, Lateral canthal sling, upper eyelid lowering etc with an aim to reduce the vertical and horizontal dimensions of the palpebral aperture.

Review Questions

1. Write the sādhyāsādhyata of vartmagata rogas. Describe the surgical treatment of 'Kumbhi' according to Ashtanga Hridaya.
2. Write the lakshana and chikitsa of 'Pothaki'.
3. Describe in detail about Vātahatha Vartma.
4. What is Pakshmashāta. Explain the shastra chikitsa in Pakshmakōpa.
5. Elaborate the lakshana and chikitsa of 'Kukūnaka'.
6. Write vyavachedaka nidana for Anjananāmika.
7. Describe Nimésha.
8. What are lekhana sādhyā vartma rogas.
9. What are the eye diseases in which you find some or other impairments in the lid movements?
10. Describe any two diseases in which you find "Swelling of the lids".
11. Describe Krichronmeelana.
12. List out the diseases of vartma where in jaloukavacharana is indicated.
13. Define & classify utklishta vartma.
14. Describe & differentiate Arshóvartma and Shónitārsha.
15. Describe anatomy of Eye lids with a neat diagram.

Research updates

1. Study of efficacy of Rasanjan and Madhu pratisaran after Bhedankarma in Anjananamika with special reference to External hordeolum. MUHS, 2012-13.
2. A clinical study on Pothaki (Trachoma) and its management with Hareetakyadi eye drops, Dr. Narayan G. Balavatti, Dept. of Shalakya tantra, IPGT & RA, Jamnagar, 2007.

Scope for Research

1. Literary review on pilla rogas.
2. Evaluate the efficacy of Shastra and Agnikarma in the management of Pakshmakōpa.

●

Chapter-5

SHUKLAGATA ROGA (DISEASES OF SCLERA AND CONJUNCTIVA)

- | |
|---|
| A. Number of Shuklagata rogas, detailed knowledge of etiology, pathology, clinical features and management of Arma, Arjuna and Shuktika |
| B. Brief Knowledge of Sira pidika, Sira jāla, Pishtaka, Balāsagrathita. |
| C. Study of Pterygium, Scleritis, Episcleritis, Sub-Conjunctival Hemorrhage including their etiology, signs and symptoms, differential diagnosis medical & surgical management. |

Chapter

5A

- Sandhis of Shukla Mandala
- Classification of Shuklagata Roga
- Arma- Its types and management
- Shuktika
- Arjunā

SHUKLA MANDALA ROGAS

Shukla mandala is the visible white portion of the eye comprising of conjunctiva and sclera. The visible area is about 25mm long and 15mm wide. The boundaries of shukla mandala consists of 4 netra sandhis:

- Vartma shukla
- Shukla Krishna
- Kaneenika
- Apaṅga sandhi.

Doshas and Dhatus in Shukla mandala

The sthanika dosha of shukla mandala is kapha because of the predominance of the jalamahābhūta and pitta is the anubhandha dosha due to the presence of blood vessels signifying the agni mahābhūta. Rasa, rakta and Māmsa are the dhatus involved.

Classification of Shuklagata Rogas

प्रस्तारिशुक्लक्षतजायिमांसस्नाय्वर्मसंज्ञाः खलु पञ्च रोगाः ।

स्युः शुक्तिका चार्जुनपिष्टकौच जालं सिराणापिडकाश्च याः स्युः ॥

रोगा बलासग्रथितेन सार्धमेकादशाक्ष्णोः खलु शुक्लभागे ॥ (S.U.4/2-3)

As per Sushruta-Shuklagata rogas are 11 and Vagbhata has added two more diseases making it 13.

S.N.	Sushruta, Bhavaprakasha and Yogaratanakara	Vagbhata, Sharangadhara
1.	Prastāri arma	Prastāri arma
2.	Shūkla arma	Shukla arma
3.	Kshataja arma	Shōnita arma
4.	Adhimāmsa arma	Adhimāmsa arma

Shuklagata Roga

163

5.	Snāyu arma	Snāvarma
6.	Shuktika	Shuktika
7.	Arjuna	Arjuna
8.	Pishtaka	Pishtaka
9.	Sirājāla	Sirājāla
10.	Sirāpidaka	Sirāpitika (chippita)
11.	Balāsagrathita	Balāsagrathita
12.		Sirōtpāta
13.		Sirāharsha

Classification based on Dosha

S.N.	Dosha	Disease
1.	Vāta	-
2.	Pitta	Shuṭtika
3.	Kapha	Shuklārma, Pishtaka, Balāsagrathita
4.	Rakta	Kshatajārma, Arjuna, Sirājāla
5.	Sannipāta	Prasthāri arma, Adhimāmsārma, Snāyu arma, Sirā pidika

Classification based on Shastra Karma

S.N.	Shastra karma	Disease
1.	Chedana/Lekhana	5 types of Arma, Sirājāla, Sirāpidika
2.	Ashastrakruta	Shuktika, Arjuna, Balāsagrathita, Pishtaka

Sādhyā Asādhyata of Shuklagata roga

All the Shuklagata rogas are said to be Sādhyā.

20 S.T.-I

ARMA (Pterygium)

Nirukti

The term Arma originated from "Ru" dhatu along with "Manain" pratyaya meaning "always growing".

Definition

इयति गच्छति इति अर्म ।

A gradually spreading fleshy growth occurring in the shleshma kala of shukla mandala is called as Arma.

Types of Arma

There are five types of Arma:

- | | |
|---------------------------|-------------------|
| 1. Prastāri arma | 4. Adhimāmsa arma |
| 2. Shukla arma | 5. Snāyu arma |
| 3. Kshataja (Lohita) arma | |

1. Prastāri arma (Pterygium)

It is Tridoshaja Chédana Sādhya Vyādhi

प्रस्तारि प्रथितमिहार्म शुक्लभागे विस्तीर्णं तनु रुधिरप्रभं सनीलम् ।। (S.U.4/4)

Prathita- Fleshy mass Shukla bhāge- In sclera Visteerna- Widely spreading

Tanu- Thin Rudhira prabha sa nilam- Bluish red.

Prasthāri arma is a bluish red coloured, thin and widely spreading fleshy mass occurring in the shukla bhaga of netra.

According to Vagbhata

मृदु आशु वृद्धि अरुक् मांसं प्रस्तारि श्याव लोहितम् । प्रस्तारि अर्म मलैः सार्वैः..... ।। (A.H.U.10/17)

Mṛudu- Soft Ashu vriddhi- Rapidly spreading

Aruk- Painless Shyāva lohita- Black/red

Malaiḥ sasraihi- Tridosha and rakta

A soft and painless, rapidly spreading, black or red coloured growth occurring in the shukla mandala due to the vitiation of tridosha and rakta is called Prasthāri arma.

2. Shukla arma (Pingecula)

It is a Kaphaja Chédana Sādhya Vyādhi.

शुक्लाख्यं मृदु कथयन्ति शुक्लभागे सश्वेतं सममिह वर्धते चिरेण । (S.U.4/5)

Akhyam- Known as

Mrudu- Soft

Kathayanti- Told

Shuklabhage- In the sclera

Sa shwetam- White in colour

Samam- Even

Iha- This is

Vardhate chiréna- Slow growing.

A soft, uniform, whitish coloured growth occurring in the shukla bhaga of netra which progresses slowly and continuously is known as Shuklarma.

According to Vagbhata

कफात् शुक्ले समं श्वेतं चिरवृद्धि अधिमांसकम् । शुक्लार्म..... ।। (A.H.U.10/11)

Samam- Uniform

Shvetam- White

Chira- Slowly & continuously

Vriddhi- growing

Adhimāmsaka- Muscular growth

Shuklarma is a slowly progressing, white coloured, uniform muscular growth caused due to vitiation of kapha dosha.

3. Kshatāja arma/Lohita arma
(Progressive pterygium or hemangioma)

It is a Raktaja Chédana Sādhya Vyādhi.

वन्मांसं प्रचयमुपैतिशुक्लभागे पद्माभं तदुपदिशन्ति लोहितार्म । (S.U.4/5)

Yat- This

Māmsam- Fleshy

Prachayamupaiti- Growth takes place

Padmaabham- Like lotus flower

Tat- That

Upadishanti- Called as.

A fleshy growth resembling the colour of lotus flower occurring in the shukla bhaga of netra is called as Lohitārama.

Vāgbhata has named it as Shōnitarma

According to Vagbhata

शोणितार्मं समं श्लक्ष्णं पद्माभं अधिमांसकम् ।। (A.H.U.10/16)

Samam- Uniform

Shlakshna- Smooth

Padmābha- Resembles lotus

Adhimamsakam- Fleshy growth

Shonitārma is a uniform fleshy growth which is smooth and resembles colour of lotus.

4. Adhimāmsa arma (Pseudo Pterygium)

It is a Sannipātaja Chédana Sādhyā Vyādhi

विस्तीर्णं मृदु बहलं यकृतकाशं श्यावं वा तदधिकमांसजाम् विद्यात् ॥ (S.U.4/6)

Visteernam- Spreading

Mṛudu- Soft

Bahalam- Bulky

Yakrut prakasham- Resembling liver

Shyavam- Grey

Vaa- or

Vidyat- Known as.

A grey coloured, bulky, soft, widely spreading muscular growth having resemblance to liver is known as Adhimāmsaja arma.

According to Vagbhata

शुष्क असृक् पिण्डवत् श्यावं यत् मांसं बहलं पृथु । अधिमांसमर् तत्.....॥ (A.H.U.10/18)

Shuṣhk asruk pindavat shyavam yatmāmsam- The muscular growth which is grey like dried blood clot.

Bahala- Large/bulky

Pruthu- Thick.

A large, thick, grey coloured muscular growth resembling the colour of dried blood clot is called as Adhimāmsaja arma.

5. Snāyu arma (Snavarma) (Pterygium-Fibrous)

It is a Sannipātaja Chédana Sādhyā Vyādhi.

शुक्ले यत् पिशितमुपैतिवृद्धिमेतत् स्नाय्वर्मेत्यभिपठितं खरं प्रपाण्डु ॥ (S.U.4/6)

Shukle- In the sclera

Yat- This

Pishitam- Fleshy

Upaiti- Takes place

Vruddhim- Growth

Abhipathitam- Called as

Kharam- Rough

Prapandu- Pale.

A pale and rough, fleshy mass which grows in the shukla bhāga of eye is called as Snāyu arma.

Vagbhata has named it as Snāvarma.

स्नायवर्मा स्नायवसन्निभ ॥ (A.H.U.10/18)

Snāva- Tendon

A Tendon like growth in the Shukla bhāga of eye is called as Snāvarma.

Arma Chikitsa

Sushruta has categorized arma under chédana sādhyā vyādhis. But in the following conditions when the disease is not very grave, lekhana karma can be done. So both lekhana and chédana are indicated in arma.

Indications for Lekhana karma

अर्मा चाल्पं दधिनिभं नीलं रक्तमथापि वा । धूसरं तनु यच्चापि शुक्रवत्तदुपाचरेत् ॥ (S.U.15/17)

The arma which is alpa (small) and tanu (thin), dadhi nibha (white in colour), nīla (bluish), raktam (red), dhusaram (pandu) can treated by Lekhana karma. The anjanas mentioned in treatment of savrana & avranashukra are also helpful in this condition.

Indications for Chédana karma

चर्माभं बहलं यत्तु स्नायुमांसघनावृतम् । छेद्यमेव तदम स्यात् कृष्णमण्डलगं च यत् ॥ (S.U.15/18)

- If the arma is thick like skin (chamabha).
- Large and elevated (bahalam).
- Fleshy and covered with fibrous tissue and blood vessels (snayu mamsa ghana avrutha).
- If it is encroaching krishna mandala (Krishnamandalaga).

Contra-indications for chédana karma

तत् छेद्यं असितप्राप्तं मांसस्नावसिरावृतम् । चर्मोद्दालवत् उच्छ्रायी दृष्टिप्राप्तम् तु वर्जयेत् ॥ (A.S.U.13/25)

- If the growth has reached the asita bhāga (cornea) and drushti bhāga (pupil).
- If it is fleshy, tendinous and covered with blood vessels.
- If it is elevated like charmoddāla (leather bag).

Shastra Karma in Arma

Instruments required

- Mandalāgra shastra
- Muchundi yantra
- Badīsha yantra
- Sūchi and sūtra

Pūrva karma

- The patient is subjected to Samshōdhana and Samsarjana karma
- Snigdha anna is given to the patient.

Pradhāna karma

- Patient is positioned comfortably either in sitting or sleeping posture.
- Rub the arma with saindhava lavana to make it soft.
- Swēdana is done to the part.
- Arma should be moved (parighattana) to loosen it.
- The patient is asked to look laterally (apānga side).
- The site where the wrinkle is formed is lifted with the badīsha and muchundi yantra or the distal end of the arma is lifted using suture thread (suchi-sutra). The arma shouldn't be pulled up briskly as it may cause tearing.
- Using mandalāgra shastra separate the arma from Krishna and shukla mandala until kaneenika sandhi is reached.
- Then the arma is cut leaving medial 1/4th part.
- Over excision (very close to kanīnika sandhi) leads to nādi vṛana (sinus), and insufficient excision will lead to regrowth of the arma.

Paschāt karma

- Pratisārana should be carried out with yavakshāra, trikatu and saindhava lavana followed by-
- Swēdana
- Bandhana.
- Snēhana with ghrīta.

- Remove the bandha after three days.
- Vrana shōdhana and rōpana measures are followed till the complete healing takes place.
- Aschōtana with kshīrapāka of karanja bīja, āmalaka, madhūka along with madhu twice daily reduces pain.
- Lekhana anjana prepared using lōha chūrna, saindhava lavana etc, should be applied to remove the left over 1/4th part of arma.

Samyak chēdana lakshana

विशुद्धवर्णमविलम्बं क्रियास्वक्षि गतक्लमम् । छिन्नेऽर्मेणि भवेत् सम्यग्यथास्वमनुपद्रवम् ॥ (S.U.15/19)

- Vishudda varṇa- Normal colour of eye Aklishtam- No difficulty
Kriyāsu akshi- Function of eye Gataklamam- Relief from pain
Chinne Armani- Excised pterigium Yathaswam- Properly
Anupadravam- Devoid of complication

If surgery is performed properly, then the following features are observed:

- Normal colour and functions of the eye
- Relief from pain
- Devoid of any complications.

Table: Showing Classification and Lakshanas of Arma explained according to various Authors.

Prasthāri Arma

	Sushruta	Vagbhata
Colour	रुधिरप्रभ, सनीला	इयाव लोहित
Nature of the Growth	विस्तीर्ण	आशुवृद्धि
Nature of the mass	तनु	मृदु
Dosha	त्रिदोष	त्रिदोष with रक्त

Shuklārma

	Sushruta	Vagbhata
Colour	शुक्ल सश्चेत	शुक्ल
Nature of The Growth	वर्धते चिरेण	चिरवृद्धि
Nature of The Mass	मृदु	अधिमांसकम्
Dosha	कफ	कफ

Kshataja/Lohitha Arma

	Sushruta	Vagbhata
Colour	पद्माभं	पद्माभं
Nature of the Growth	प्रचयमुपैति	अधिमांस
Nature of the Mass	इलक्ष्णं	मृदु
Dosha	रक्त	रक्त

Adhimāmsa Arma

	Sushruta	Vagbhata
Colour	यकृत्प्रकाश इयाव	असृक् पिण्ड इयाव
Nature of the Growth	विस्तीर्ण	पृथु
Nature of the Mass	मृदु बहलं	शुष्क बहलं
Dosha	सन्निपातज	सन्निपातज

Snayu-Arma

	Sushruta	Vagbhata
Colour	प्रपाण्डु	
Nature of the Growth	वृद्धिमेतत्	
Nature of the mass	खरं	स्नावसन्निभं
Dosha	त्रिदोषज	

SHUKTIKA (Xerophthalmia)

It is a Pittaja Bhesaja Sādhya Vyādhi.

इयावाः स्युः पिशितनिभाश्च बिन्दुवो ये शुक्त्याभाः सितनयने स शुक्तिसंज्ञः । (S.U.4/7)

Shyāva- Grey Syuhu-Does Pishitanibha- Fleishy

Bindavo- Dot Shuktyabha- Dull white colour like jalashukti (pearl shell).
A greyish coloured fleshy dot, resembling pearl shell, occurring in the shuklabhaga of netra is called Shuktika.

According to Vagbhata

पित्तम् कुर्यात् सिते बिन्दून् असित इयाव पीतकान् ॥ मलाक्तादर्शं तुल्यं वा सर्वं शुक्लं सदाह रुक् ।
तोगोऽयं शुक्तिकासंज्ञः स शकृत् भेद तुद् ज्वरः ॥ (A.H.U.10/10-11)

Bindoon- Dots Asita- Black Shyāva- Grey
Pitaka- Yellow Malākta darsha Tulya- Appears similar to dirt covered mirror

Sadaha- Burning sensation Ruk- Pain

Shakrud bhēda- Atisara/diarrhoea Trut- Thirst Jwara- Fever.

It is a condition in which vitiation of pitta causes black, grey or yellow coloured dots in the shukla mandala. The whole of sclera looks like mirror embedded with dust. The systemic symptoms present in shuktika are burning sensation, pain, diarrhoea, thirst and fever.

Chikitsa (S.U.10/14-15)

- Treatment is similar to those mentioned for pittaja abhishyanda.
- After virechana, application of anjana prepared with cooling dravyās.
- Ghrita pāna, séka, āschatana, lepa and nasya are also useful.

Anjana yogas in Shuktika

- Anjanas prepared with bhasma or sukshma churna of vaidurya, sphaṭika, pravāla, shanka, roupya and suvarna mixed with sugar and honey.
- Mustādi anjana
- Lodrādi anjana
- Amalakyādi anjana

ARJUNA (Subconjunctival haemorrhage)

It is a Raktaja Sādhya Vyādhi.

एको यः शशरुधरोपमस्तु बिन्दुः शुक्लस्थो भवति तमर्जुनं वदन्ति ।। (S.U.4/7)

Eko- Single Shasharudhiropamastu- Resembling blood of rabbit

Bindu- Dot Shuklasta- In the shukla bhaga

Condition in which a red coloured dot resembling the blood of rabbit is seen in shukla bhaga of netra is called Arjuna.

According to Vagbhata

नीरुक् श्लक्ष्णो अर्जुनं बिन्दुः शशलोहित लोहितः । (A.H.U.10/17)

Niruk- Painless Shlakshna- Smooth Bindu- Dot,

Shasha lohita lohitaha- Lesion resembles blood of rabbit.

A soft painless dot resembling the colour of blood of rabbit seen in shukla bhaga of netra is called as Arjuna.

Chikitsa (S.U.12/19-23)

- Pittahara line of treatment
- Raktābhishyandavat chikitsa (A.S.U.14/8)
- Dravyas for Seka and anjana
Ikshurasa, Madhu, Sita, Stanya, Dārvi, Yashtimadhu, Saindhava.
- Dravyas for Aschótana (either alone or in combination).
Sitā, Madhuyashti, Mastu, Katvanga, Bijāpura, Kōla, Dādin a.

Anjana yogas

- Shaṅka, Sitā, Samudraphēna
- Sphatika, Pravāla, Shaṅka, Madhuyashti, Madhu.
- Saindhava, Kshaudra and Kataka.
- Rasānjana with Kshaudra.
- Kāseesa with Madhu.

Chapter**5B**

- Pishtaka and its Management
- Sirājāla, Sirāpidaka- its features and treatment
- Balāsagrathita
- Sirótpātā and Sirāharṣha

PISHTAKA (Pingecula/Lymphangioma)

pishtaka literally means paste made of rice flour.

It is a Kaphaja Bhéshaja Sādhya Vyādhi. Bhavaprakasha describes the involvement of Kapha and Vayu.

उत्पन्नः सलिलनिधोऽथ पिष्टशुक्लो बिन्दुर्यो भवति स पिष्टकः सुवृत्तः । (S.U.4/8)

Utsanna- Elevated

Salila Nibha- Water like

Suvrutta- Round

Pishtashukla- Grounded rice flour

Bindu- Dot/Spot

An elevated round spot in the shukla mandala which is either clear like water or white like grounded rice flour is known as Pishtaka.

According to Vagbhata

बिंदुभिः पिष्टघवलैः उत्पन्नैः पिष्टकं वदेत् । (A.H.U.10/13)

Bindubhihi- Spots Pishta- Flour Dhavalaihi- White Utsanna- Elevated

Multiple, elevated, white spots resembling rice flour paste seen in the shukla bhāga of netra is called pishtaka.

Chikitsa

- Treatment is similar to Abhishyanda and Adhimantha
- Anjana yogas in pishtaka
- a. **Mahoushadhadi anjana:** Trikatu, saindhava, shweta maricha- all are taken in equal quantity and bhavana is given with mātulunga swarasa to prepare this anjana.

- SIRĀJAALA

(Haemangioma of Sclera/Scleral Staphyloma)

It is a Raktaja Chédana Sādhyā Vyādhi.

जालाभः कठिनसिरो महान् सरक्तः सन्तानः स्मृत इह जालसंज्ञितस्तु ॥ (S.U.4/8)

Jālabaha- Network like	Kathina- Hard	Sirā- Blood vessel	Mahān- Large
Sarakta- Red in colour	Santaanaha- Laver		

A layer of hard, large, red coloured capillary network occurring in shukla mandala is known as sirājāla.

According to Vāgbhata

सिराजाले सिराजालं बृहत् रक्तं घनोन्नतम् । (A.H.U.10/16)

Sirājāla- Network of blood vessels	Bruhat- Large	Raktam- Red
Ghanam- Thick	Unnatam- Raised/elevated	

Large, red coloured, thick, elevated network of blood vessels seen in the shukla mandala is called sirājāla.

Chikitsa

- Lēkhana is advised if the network of blood vessels are smooth and fragile.eg: Shaṅka samudraphénadi lekhaniya churna.
- Chédana is advised if the network of blood vessels are thick and engorged. The Sirās has to be excised as in Arma.

Surgical procedure in Sirājāla

सिराजालेसिरा यास्तु कठिनास्ताश्च बुद्धिमान् । उल्लिखेन्मण्डलाग्रेण बडिशेनावलम्बिताः॥ (S.U.15/20)

- Snehana and Swedana is given to the affected part.
- Hold the hard siras with the help of badisha yantra and excise the part with mandalāgra Shastra.
- After surgery, lekhana pratisarana as in Arma is advised.

SIRĀPIDAKA (Episcleritis)

Śirā- Blood vessels **Pidaka-** Nodular swelling

It is a Sannipātaja Chédana Sādhyā Vyādhi.

शुक्लस्थाः सितपिडकाः सिरावृता यास्ता विद्यादसितसमीपजाः सिराजाः। (S.U.4/9)

Shuklasthaha- In sclera

Siravruta- Covered by blood vessels

Asita sameepaja- Close to cornea.

Sitā pidaka- White nodular swelling

A white coloured, nodular swelling covered by blood vessels seen in shukla mandala lying close to cornea is called as Sirāpidaka.

According to Vagbhata- It is called 'sirā'

Sharangadhara names it as **Sirachippita**

.....दाहर्षवत्यः सिरावृताः । कृष्णासत्राः सिरासंज्ञाः पिटिकाः सर्पयोपमाः ॥ (A.H.U.10/19)

Dāha- Burning sensation

Gharsha- Foreign body sensation

Sirāvrutaah- Covered by sirās

Krishnaasanna- Near Krishna mandala

Sarshapopama pitika- Mustard seed shaped granular swelling.

'Sīrā' is a condition in which mustard seed shaped granular swelling covered with blood vessels are seen near the krishna mandala. The symptoms such as foreign body sensation and burning sensation of the eyes are also seen.

Chikitsa

Similar to Arma and Sirajāla.

- If the nodular swelling is soft and small- Lekhana is indicated.
- In hard and large swelling- Chédana is indicated.

Lekhana chūrnanjana (S.U.15/25-28)

Shankha, Samudraphēna, Manduki, Samudraja, Sphatika, Kuruvinda, Pravāla, Ashmantaka, Vaidurya, Pulaka, Mukta, Louha, Tāmra, Rajata-all the above ingredients are taken in equal quantity and mixed with half the quantity of Sroto anjana and stored in Mesha sringa.

The anjana thus prepared is indicated in Armā, Sira pidaka and Sirā jāla.

BALASAGRATHITA

(Pinguecula/any cyst or tumour of conjunctiva)

Synonyms of Balāsagrathita: Balāsākhyā and Balāsāhwaya (A.H.U.10/12)

It is a Kaphaja Sādhyā Vyādhi

कांस्याभो भवति सितेऽम्बुबिन्दुतुल्यः सन्नेयोऽमृदुररुजो बलासकाख्यः । (S.U.4/9)

Kamsyābho- Colour of bronze **Sitē-** In the sclera**Ambu bindu tulayaha-** Like water droplet **Amrudu-** Hard **Arujō-** Painless

A painless, hard nodule resembling water droplet and shining like bell metal (bronze) occurring in Shuklabhāga of netrā is called balāsaka or balāsa grathita.

According to Vagbhata

.....शोफस्तु अरुजः सवर्णो बहलोऽमृदुः । गुरुः स्निग्धोऽम्बुबिन्दुभा बलासग्रथितं स्मृतम् ॥ (A.H.U.10/12)

Shōpha- Swelling **Neeruja-** Painless **Savarno-** Of same colour**Bahalo-** Large **Amrudu-** Kathina/hard **Guru-** Heavy/large**Snigdha-** Unctuous **Ambu bindvabho-** Resembling water droplet.

A hard, large, heavy, unctuous, painless swelling of similar colour, resembling water droplet occurring in shukla mandala is called Balāsagrathita.

Chikitsa

Since the disease balāsagrathitha is caused by kapha, treatment indicated for kaphaja abhishyanda is to be adopted (except sirāvyadha) (A.H.U.11/7-8)

'Kshārānjana' is a special treatment mentioned for Balasagrathitha.

Preparation of Kshārānjana

- Apakwa yava (Barley) is soaked in godugdha. Later it is dried and burnt with drugs like arjaka, aasphota, kapittha, bilva, nirgundi and jatikusuma and the ash produced by this is collected. The ash thus obtained is boiled with the saindhava, tutha and gorōchana to prepare ksharanjana.

- Vāgbhata includes Sirotpāta and Sirāharsha in Shuklagata Roga.

- Sushruta includes Sirotpata and Sirāharsha in Sarvagatha Roga.

SIROTPĀTA

Sirotpāta is a disease of shukla mandala caused due to vitiation of rakta. The clinical features are congestion of the sclera associated with burning sensation, pain and discharge. There will be no swelling. (Ref. Sarvagatha Rogas).

SIRĀHARSHA

It is a raktaja vydhana sādhyā vyadhi. If sirotpata is left untreated it leads to a condition called sirāharsha. In this the signs and symptoms of sirotpāta are seen in more aggressive form and the patient will be unable to visualize properly. (Ref. Sarvagatha Rogas).

Chapter**5C**

- Applied anatomy of Sclera and Conjunctiva
- Types of Pterygium and its surgical Management
- Scleritis and Episcleritis
- Subconjunctival Haemorrhage

DISEASES OF THE SCLERA AND CONJUNCTIVA**Applied anatomy of Sclera**

The sclera constitutes the outer coat of the eye. It is opaque, thick, rigid and white in appearance. It is made of bundles of collagenous fibriles and is covered by tenon's capsule. In the anterior part it is also covered by bulbar conjunctiva. Histologically sclera consists of three layers:

1. Episcleral tissue which is thin and densely vascularised.
2. Sclera proper which is an avascular structure and consists of dense bundles of collagen fibres and,
3. Lamina fusca which is the innermost part and blends with the suprachoroidal and supraciliary laminae of the uveal tract.

Inner surface of sclera is in contact with choroid with a potential suprachoroidal space in between. In its anterior most part near the limbus, there is a furrow which encloses the canal of Schlemm. The sclera is perforated by many vessels and nerves and is supplied by branches of the long ciliary nerve.

Anatomy of conjunctiva- (Refer chapter-7C)

PTERYGIUM

The term Pterygium is derived from Latin word meaning 'wing'.

Pterygium is a wing shaped triangular fold of conjunctiva encroaching upon the cornea either from the nasal or the temporal side within the inter palpebral fissure.

Pathology: It is a degenerative and hyperplastic condition of the conjunctiva.**Etiology**

Not definitely known. It usually occurs in elderly males working outside. The disease is commonly seen in people living in hot climates. Therefore, prolonged exposure to sun, dry heat, wind and dust can be considered as the cause.

necrotic and is replaced by a thin fibrous tissue. There is marked infiltration of scleral fibres, with ultimate thinning of sclera.

Classification

Based on anatomical location and type of scleral inflammation, it can be classified as:-

1. Anterior scleritis

- Non necrotizing which is diffuse or nodular.
- Necrotizing which is with or without inflammation.

2. Posterior scleritis: Inflammation of sclera behind the equator.

Symptoms

- Marked pain in the eye, which may radiate to the jaw and temple.
- Photophobia and lacrimation may be mild to moderate.
- Occasional diminution of vision.

Signs

- Usually the anterior part of the sclera is affected in one sector.
- Pinkish red area appears with hyperaemia of the surrounding conjunctiva.
- The patch of scleritis is slightly elevated and markedly tender, when pressure is applied on it over the lid.

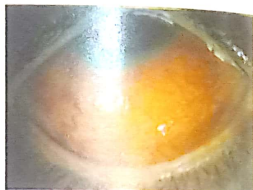

Fig. 5.2

Treatment

- Non necrotising scleritis: Mild cases respond to oral NSAIDs (Non steroidal anti-inflammatory drugs). If NSAIDs are ineffective, systemic corticosteroids should be added. Topical steroid eye drops is also recommended.
- Necrotising scleritis is almost always treated by topical steroids and heavy doses of oral steroids.
- In non responsive cases immune-suppressive agents are used.

EPISCLERITIS

A transient inflammation of the superficial layers of the sclera is known as episcleritis. The disease may be unilateral or bilateral predominantly affecting young women.

Etiology

- Associated with systemic diseases such as gout, psoriasis, rheumatism etc.
- As an allergic reaction to an endogenous toxin, tubercular or streptococcal, from a septic focus.
- Infectious episcleritis may be caused by herpes zoster virus or syphilis.

Symptoms

- Pain and redness in the eye.
- Mild ocular discomfort such as gritty, burning or foreign body sensation.
- Rarely mild photophobia and lacrimation.

Signs

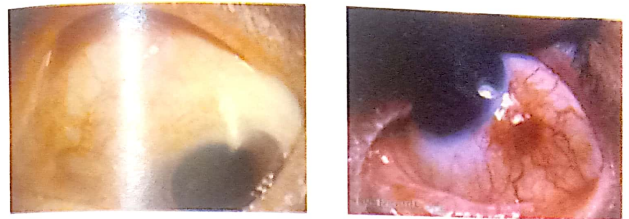


Fig. 5.3

Two clinical types of episcleritis are (i) simple (diffuse) and (ii) nodular

- Simple episcleritis** (diffuse) is characterised by engorged episcleral vessels which run in radial direction beneath the conjunctiva. The inflammation is confined to one or two quadrants of the eye. The involved area looks markedly oedematous and vascularised.
- Nodular episcleritis** is characterised by pink or purple nodule which is hard, tender and immobile and the overlying conjunctiva freely moves over it.

Differentiating between Episcleral and Scleral Vessels

Episcleral vessels can be moved with a cotton bud. If you apply phenylephrine 10%, they blanch (remember that this will also dilate the pupil). Scleral vessels appear darker, follow a radial pattern, are immobile and do not blanch.

Treatment

- Topical artificial tears, NSAIDs or mild corticosteroid eye drops.

- Cold compresses on closed eyelids.
- Systemic Non-Steroidal Anti Inflammatory Drugs. (Nsaids)

SUB-CONJUNCTIVAL HAEMORRHAGE (Ecchymosis)

Subconjunctival haemorrhage occurs very commonly. It may be seen as small petechial haemorrhages to one spreading under the whole of bulbar conjunctiva. The exposed part of bulbar conjunctiva is the usual site because this is easily liable to be injured and because blood can easily accumulate in the loose subconjunctival tissue in that area. In the early stage, the haemorrhage looks bright red in colour but later on becomes blackish red.

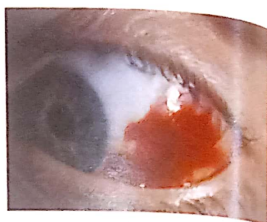

Fig. 5.4

Etiology

- Direct trauma to the eye, head or orbit.
- Blood diseases such as leukaemia, purpura, haemophilia.
- Arteriosclerosis and hypertension or local vascular anomalies like varicosity or aneurysm.
- Acute inflammation of the conjunctiva.
- Acute febrile infection like meningococcal septicaemia.
- Vicarious menstruation- bleeding may occur from ear, nose and conjunctiva.

Clinical features

Subconjunctival haemorrhage is usually symptomless.

On examination, subconjunctival haemorrhage looks as a flat area of homogenous bright red colour with well defined limits. In traumatic subconjunctival haemorrhage, posterior limit is visible when it is due local trauma to the eye but most of the time it is absorbed completely within 7 to 21 days. During absorption the colour changes from bright red to orange and then yellow.

Treatment

- Treat the cause.
- Placebo therapy with astringent eye drops.
- Cold compresses to check the bleeding in initial stage.
- Hot compresses may help in absorption in later stages.

Review Questions

1. What is Arma? Classify and write its management in detail.
2. Classify Shuklagatha rogas based on chikitsa.
3. Differentiate Sirótpātha and Sirāharsha.
4. Write in detail about surgical management of Arma.
5. Define Shuktika. Write about its management.
6. Write the pitta predominant conditions of shuklamandala.
7. Write in detail about surgical management of Sirajāāla.
8. Write chikitsa for Balāsagrathita.
9. Describe some anjana yogas mentioned in the treatment of Pishtaka.
10. Describe Arjuna and its management.

Research works

1. A comparative study on the efficacy of Pippalyadi anjana and Shatavaryadi churna abhyantara in the management of Arma. Dr. Navya 2009 GAMC - RGUHS Bangalore.
2. Role of Guduchyadi rasakriyanjana in the management of Arma. Dr. Shailendra G B. 2006.

Scope for Research

1. Critical analysis of different types of Arma.
2. Study on the effect of Vaiduryadi anjana in the management of Shuktika.

Chapter-6

KRISHNAGATA ROGA

(DISEASES OF CORNEA AND UVEA)

- | | |
|---|--|
| A | Number of krishnagata rogas, detailed knowledge of etiology, Pathology, Clinical features, differential diagnosis, complications and management of Savrana/kshata Shukla (Shukra), Avrana shukra (Shukla). |
| B | Brief knowledge of Sirā shukla, Akshipākatyaya and Ajakājāta. |
| C | Knowledge of Corneal ulcer, Corneal Opacity, Uveitis, Acute Iridocyclitis, Staphyloma, their aetiology, pathology, symptoms, differential diagnosis, complications and management. |

Chapter

6A

- Pramāna of Krishnamandala
- Layers of Krishnamandala
- Classification of Krishnagata rogas
- Savrana Shukra
- Avrana Shukra and it's management

KRISHNAGATA ROGAS

Krishna Mandala

(Krishna- Black, Mandala- Circular part).

Krishna mandala is the central 1/3rd part of the visible portion of the eye ball. This appears black in colour but is purely transparent. Krishnamandala gets its colour because of the underlying pigmented structure- Krishna patala (iris).

The predominant mahabuta in krishnamandala is vayu, may be because of its contact with atmospheric air, property of transparency and function of attracting light rays into eyeball.

Pramāna of Krishna mandala

नेत्रायामत्रिभागं तु कृष्णमपडलमुच्यते । (S.U. 1/13)

It is 1/3rd of Netra āyāma.

- It is Dwi yava (barley) pramāna. (Dalhana)
- तत्र शुकलात् तृतीयांशं कृष्णम् । (A.S.Sh.8/36)

It is 1/3rd of Shukla mandala.

Layers of krishna mandala

Acharya Vagbhata has mentioned three layers of krishnamandala while describing sādhyāsadyata of kshata shukla. They are:

22 S.T.-I

1. Twacham- Outer layer
2. Dwiteeya patala- Second layer
3. Triteeya patala- Third layer

Classification of Krishnagata roga

यत् सव्रणं शुक्र(क्ल)मथाव्रणं वा पाकात्ययश्चाप्यजका तथैव ।
चत्वार एतेऽभिहिता विकाराः कृष्णाश्रयाः संग्रहतः पुरस्तात् ॥ (S.U.5/3)

S.N.	Sushruta	Vāgbhata	Shāraṅgadhara
1.	Savṛṇa Shukra	Kshata Shukla	Kshata Shukra
2.	Avṛṇa Shukra	Shuddha Shukla	Shuddha Shukra
3.	Ajakājāta	Ajakā	Ajakā
4.	Akṣhipākātyaya	Pakātyaya Shukla	Sirāsāṅga
5.		Sirā Shukla	Sirā Shukra

Classification based on dosha

Dosha	Disease
Kaphaja	Ajakā
Sannipātaja	Pākātyaya, Sirāshukla (Vagbhata)
Raktaja	Savṛana & Avṛana shukla

Classification based on Sadhyāsādhyata

Sadhya	Avṛṇa shukla
Asadhya	Savṛṇa, Pākātyaya, Ajaka, Sirāshukla

SAVRANA SHUKRA/SHUKLA (Corneal Ulcer)

Sa-associated with; **Vrana-ulcer**; **Shukla-ulcer** will be whitish in colour.

Presence of ulcer in the krishnamandala is called Savrana shukla.

It is a Raktaja Asādhya Vyādhi.

निमग्नरूपं हि भवेत्तु कृष्णो सूच्येव विद्धं प्रतिभाति यद्वै ।

स्त्रावं स्रवेदुष्णमतीव रुक् च तत् सव्रणं शुक्र(क्ल)मुदाहरन्ति ॥ (S.U.5/4)

Sūchi- Needle

Pratibhāti- Similar to

Sravédushna- Warm lacrimation

Udaharanti- Called as

Bhavettu- Takes place

Eva- Like

Yadvai- Which

Ateeva Ruk- Severe pain

Krishne- In cornea

Viddham- Pierced

Sravam- Discharge

Cha- and Tat- That

An ulcer occurring in the krishnamandala which is deep like pierced by a needle is called savrana shukla. It is associated with severe pain, discharge and warm lacrimation.

According to Vidhana, Krishnamandala looks like coral (vidhrumābha) in savrana shukra because of vascularization (raktarājīnibha)

Sādhyā Savrana shukla

दृष्टेः समीपे न भवेत्तु यच्च न चावगाढं न च संस्त्रवेद्धि ।
अवेदनावन्न च युग्मशुक्रं तत्तिसिद्धिमाप्नोति कदाचिदेव ॥ (S.U.5/5)

Savrana shukra is considered as curable if

- **Drishtehe sameepe na:** Ulcer is not near the pupil.
- **Na cha avagaadam:** Ulcer is not deep seated.
- **Na cha samsraveddhi:** Without discharge.
- **Avédanāvat:** Painless
- **Na cha yugmashukra:** Not more than two ulcers

Asādhyā Savrana Shukla

विच्छिन्नमध्यं पिशितावृतं वा चलं सिरासक्तमदष्टिकृच्च । द्वित्वग्तं लोहितमन्तश्च चिरोत्थितं चापि विवर्जनीयम् ॥
उष्णाश्रुपातः पिडका च कृष्णे यस्मिन् भवेन्मुद्रितभं च शुक्लम् । तदप्यसाध्यं प्रवदन्ति केचिदन्यच्च यत्तिरिपितुल्यम् ॥

Savrana shukra is considered incurable if following features are seen:

- **Vicchinna madhyam:** Central perforation of the cornea.
- **Pishitāvrutam:** Ulcer covered by fleshy growth.
- **Chalam Sirasaktam:** Spreading vascularized ulcer.
- **Adrishti krit cha:** Ulcer obstructing the vision.

- **Dvitvak gatam:** Ulcer involving two patalas.
- **Lohitam antatashcha:** Redness inside.
- **Chirotittham:** Chronic ulcer
- **Ushna ashru paataha:** Warm lacrimation/discharge.
- **Pidakā cha krishné yasmin bhavet mudganibham:** Formation of nodular lesion resembling mudga (green gram).
- **Tittiripaksha tulyam:** Ulcer resembling feathers of tittira bird.

Vāgbhata names Savrana shukla as Kshata shukra

पित्तं कृष्णो अथवा दृष्टौ शुक्रं तोद अश्रु रागवत् । छित्वा त्वचं जनयति तेन स्यात् कृष्णमण्डलम् ॥
पक्वजम्बुनिभं किञ्चित् निम्नं च क्षतशुक्रकम् ॥ तत् कृच्छ्रसाध्यं, वाय्वं तु द्वितीयपटल व्यधात् ॥
तत्र तोदादि बाहुल्यं सूचीविद्धाभ कृष्णता । तृतीयपटलत् छेदादसाध्यं निश्चितं ब्रूयैः ॥ (A.H.U.10/22-24)

Pittam- Due to pitta dosha	Krishne- In cornea	Athavā- or	Drishtau- In pupillary region
Rāga- Redness	Shukram- Ulcer	Toda- Pain	Ashru- Discharge
Janayati- Produces	Chitva- Cut/tear	Tvacham- Prathamam patalam	
Kinchit- Slightly to cure	Pakvajambhunibha- Resembling ripe jambhu fruit	Nimnam- Depressed	Kricchrasādhya- Difficult
	Yāpya- Manageable	Vyadhāt- Piercing	
Suchi viddhaabha- Similar to piercing by needle	Nichitam- Covered		

The features of kshata shukra described by Vāgbhata can be understood in three stages

I- Stage

Ulcer caused due to vitiation of pitta in the krishna or drushti mandala brings about cut/tear in the prathama patala. It is associated with pricking pain, lacrimation and redness. The ulcer formed is deep and resembles ripe jambu fruit. This stage is kricchra sadhya.

II- Stage

The ulcer progresses to the second patala aggravating all the above symptoms. Krishnamandala appears as though pierced by needle. This stage is Yāpya.

III- Stage

The ulcer further progresses to the third patala, producing excessive ulceration covering the whole of cornea. This stage is Asādhya.

Chikitsa

Different treatment modalities are explained in the management of Savrana/Kshata shukra.

According to Sushruta (S.U 12/28-35)

- Patient should initially undergo Antah parimarjana chikitsa in the form of Sirāvyadha, Virechana, Shiró virechana.
- Followed with pradeha, pariseka, nasya, aschótana, abhyanga, tarpana and putapāka.
- Gharshana (rubbing) with shirisha beeja, maricha, pippali and saindhava or saindhava alone is done in superficial (prathama patalagata), deep (dvithiya patalagata or so) and rough savrana shukra.
- Then Lekhanānjana should be applied.

Anjana yogas for Savrana Shukra

- Jāthimukulādi anjana: Jatimukula, Lāksha, Gairika and Chandana.
- Tāmra bhasmādi anjana: Tāmra bhasma (16 parts), Shankha bhasma (8 parts), Manashila (4 parts), Maricha (2 parts), Saindhava (1 part).
- Shankādi añjana: Shaṅka, Kolasthi, Kataka, Drāksha, Yashtimadhu and Swarnamākshika.
- Kshārānjana- Madhu, Gódanti, Samudraphéna and Shirisha kusuma.
- Anjana with Madhūka sara and honey.
- Anjana with Vibhitaki asthi majja and honey.
- Mahāneela Gutikanjana.

Internal use: Shadaṅga guggulu, Lohādi guggulu, Paṭoladi ghrita etc are indicated in savrana shukla.

AVRANA SHUKRA (Corneal Opacity)

It is Raktaja Sādhya Vyādhī.

सितं यदा भात्यसितप्रदेशे स्यन्दात्मकं नातिरुगश्रुयुक्तम् ।

विहायसीवाच्छयनानुकारि तद्वर्णं साध्यतमं वदन्ति ॥ (S.U.5/8)

गम्भीरजातं बहलं च शुक्रं चिरोत्थितं चापि वदन्ति कृच्छ्रम् । (S.U.5/9)

Sitam- White	Yada- Those	Bhāti- Takes place.
Asitapradeshe- Krishna bhaga		Syandatmakam- Due to abhishyanda

Nati ruk- Mild pain **Ashruyuktam-** Lacrimation

Vihayaseeva accha ghananukari- Like white clouds in the sky

Sadhyatamam- Curable **Vadanti-** Called as

Gambhira jaatam- Deep seated **Bahalam-** Thick

Chiroththitam- Chronic **Chapi-** Also **Kruchram-** Difficult to cure.

Abhishyanda causes the krishna bhaga of netra to appear white in colour similar to the sky covered with clouds and is associated with mild pain and lacrimation. This condition is called Avrana shukra and is curable. But if the Avrana shukla becomes deep seated, thick and chronic, it becomes difficult to cure.

Vagbhata names it as Shuddha shukra

शुद्धशुक्लं कफात्साध्यं नातिरुक् शुद्धशुक्लम् । (A.H.U.10/25)

Shanka shuklam- White as conch shell **Naati ruk-** not very painful

In shuddha shukra the krishna bhaga of netra looks white in colour like that of a conch shell and is not very painful. It is caused by the vitiation of kapha dosha.

Chikitsa

- One should undergo shódhana karma like Sirāvyadha, Viréhana, Nasya and repeated Putapaka before applying Anjana.

Anjana yogas indicated in Avrana shukra

(Anjana should possess lekhana and ropana properties. Anjanas told in Savrana shukla can be used in Avrana shukla also).

- Bhasma of swarna, tāmra, seesa, rūpya and louha + powder of manahshila, gairika, panchalavana, navaratna, danta (go/ashva), goshringa kāsīsadi avasādana yoga (explained in Mishraka adhyāya).
- Kukkutanda kapala bhasma, lashuna, trikatu, karanja bija, ela-powdered and applied.
- Mahāneela gutika** (A.H.Chi.11/39-41).

The drugs like brihati, madhuyashti, tāmra bhasma, saindhava, shunti are powdered well and triturated with amalaki swarasa. The paste thus obtained is applied to inner surface of a copper vessel and fumigated repeatedly with yava, ghrita and amalaki. Later, the powder is scraped out and rolled into pills by mixing with water and honey.

Chapter

6B

- Akshipākātyaya
- Ajakājāta
- Sirā Shukra

AKSHI PAAKĀTYAYA (Serpiginous ulcer/Hypopyon corneal Ulcer)

"Akshi pākātyaya" means Excessive suppuration of eyes.

It is a Tridosha Asādhya Vyādhi.

संछाद्यते श्वेतनिभेन सर्वं दोषेण यस्यासितमण्डलं तु । तमक्षिपाकात्ययमक्षिकोपसमुत्थितं तीव्ररुजं वदन्ति ॥ (S.U.5/9)

Samchadyatē- Covering whole of cornea **Shwetaniibha-** Whitish in colour

Sarva doshena- Due to tridosha **Yasya-** In which

Asita mandalam- Cornea **Akshi Kopa-**Inflammatory/abhishyanda

Samuttitha- Caused due to **Tivra ruja-** Severe pain

Vadanti- Told as.

An inflammatory condition caused due to akshi kopa (abhishyanda) in which there will be vitiation of tridosha leading to severe pain and whitish discoloration of whole of cornea is called Akshipākātyaya.

Vagbhata names it 'Paakatyaya Shukla'

दोषैः स अस्रैः सकृत् कृष्णं नीयते शुक्लरूपताम् । धवलाभ्र उपलिप्ताभं निष्पावार्धदलाकृतिः ॥
अति तीव्र रुजा राग दाह श्वयथु पीडितम् । पाकात्ययेन तत् शुक्रं वर्जयेत् तीव्र वेदनम् ॥ (A.H.U.10/28-29)

Doshaihi sasraihi- Tridosha with rakta **Sakrut Krishna-** (sadruk Krishna) i.e., involvement of drushti mandala and Krishna mandala.

Neeyate- Obtains **Shukla rupatam dhavalabhra-** White in color like cloud

Upalipabha- As if covered **Nishpāva arḍha dala akruti-** Shape of half bean

Ati teevra ruja- Severe pain **Raga-** Redness **Dāha-** Burning

Shvayathu- Swelling.

The features of Pākātyaya shukra can be summarized thus:

- Involved dosha: Tridoshās and Rakta.
- Colour of cornea: Whitish discolouration similar to cloudy sky.
- Shape of the cornea: Convex resembling half part of bean seed.
- Signs and symptoms: Acute pain, congestion, burning sensation and swelling.
- Pākātyaya shukra should not be treated when there is severe pain.

Chikitsa

Both Sushruta and Vāgbhata has mentioned it as an Asādhyā Vyādhi.

AJAKĀJĀTA (Staphyloma)

It is Raktaja Asādhyā Vyādhi (Vagbhata)

It is Kapahja Asādhyā Vyādhi- Sushruta (Dalhana)

अजापुरीषप्रतिमो रुजावान् सलोहितो लोहितपिच्छिलाश्रुः ।
विदार्य कृष्णं प्रचयोऽभ्युपैति तं चाजकाजातमिति व्यवस्येत् ॥ (S.U.5/10)

Aja purisha pratima- Similar to dry excreta of goat	Rujavaan- painful
Sa lohita- Red colour	Picchilashruhu- Sticky discharge
Vidārya- Perforating	Krishnam- In cornea
Prachayo abhyupaiti- Protrusion	Tam cha- That is
	Iti- Called as.

A disease in which reddish tinged mass resembling dry excreta of goat protrudes out by penetrating the Krishnamandala and is associated with pain and sticky discharge is called as Ajakājāta.

Vāgbhata names it as 'Ajaka'

आताम्र पिच्छिलास्रं सुदात् ताम्रं पिटिका अतिरुक् ।
अजाविट् सदृशोच्छ्रायकाण्यर्था वर्ज्या असृजा अजका ॥ (A.H.U.10/26)

Aataamra- Eshat tamra/slightly coppery coloured	Picchila- Sticky
Asra- Blood	Srut- Flow
Uchrāya- Elevated	Pitika- Pustule
Varjya- Not suitable for treatment	Atiruk- Very painful
	Karṣhnya- Black Asruja- Due to rakta

Ajaka is a disease caused due to vitiation of rakta dosha, with sticky discharge and coppery black painful, elevated pitika resembling excreta of goat seen in krishna mandala. It is not suitable for treatment as it is incurable.

SIRĀ SHUKRA

Sirāshukra is explained only by Achārya Vāgbhata.

Doshas involved are Tridosha and Rakta.

It is an Asādhyā Vyādhi.

सिरा शुक्रं मलैः साक्षैस्तज्जुष्टं कृष्णमण्डलम् । सतोददाहताग्राभिः सिराभिरवतन्यते ।
अनिमित्तोष्णशीताच्छयनास्त्रस्तुच्चं तत्त्यजेत् । (A.H.U.10/27)

Malaihi sasraihi- Due to tridosha and rakta	Jushtam- Possessed of
Toda- Pain	Dāha- Burning sensation
Tāmrabhihi sirabhihi- Coppery coloured siras	Avatanyate- Covered by
Animitta- Without reason	Ushna- Hot
Sheeta- Cold	Accha- Clear/Ghana- Thick
Asra- Blood	Srut- Flow Tyajet- Avoid.

Sira shukra is a disease caused due to vitiation of tridosha and rakta, wherein krishna mandala is covered by coppery coloured blood vessels. Symptoms like pain and burning sensation are seen. Without any reason there will be hot, cold, thick or clear discharge from the krishnamandala.

Chikitsa

Sirā shukra is said to be Asādhyā. But if there is no loss of vision, it should be treated like Savṛṇa shukra.

- Anatomy of Cornea
- Corneal Ulcer
- Corneal Opacity
- Uveal tract
- Uveitis
- Staphyloma

DISEASES OF THE CORNEA

Anatomy of Cornea

The cornea is the transparent front portion of the eye like the crystal of a watch. Cornea does not have blood vessels and receives nutrients via diffusion from the tear fluid through the outside surface and the aqueous humour through the inside surface.

It has unmyelinated nerve endings sensitive to touch, temperature and chemicals. In humans, the cornea has a diameter of about 11.5 mm and a thickness of 0.5-0.6 mm in the center and 0.6-0.8 mm at the periphery. The Cornea acts as a protective membrane as well as a strong refractive surface. It has a refractive power of about +40D.

It borders with the sclera at the limbus.

Layers of Cornea

The human cornea has five layers.

From the anterior to posterior they are:




Fig. 6.1

1. **Corneal epithelium:** It is a non keratinized stratified squamous epithelium and is continuous with the conjunctival epithelium. It is kept moist with tears. Damage to this area results in invasion of conjunctival epithelium on to the cornea.
2. **Bowman's layer:** Bowman's Layer is an acellular, condensed region of the apical stroma, composed of collagen fibrils. These fibrils interact with and attach onto each other. It shows considerable resistance to infection. Once the bowman's layer is destroyed it is unable to regenerate and hence heals by scarring.
3. **Corneal stroma (substantia propria):** A thick, transparent middle layer, consisting of regularly arranged collagen fibers. They are parallel and are superimposed like book pages. Up to 90% of the corneal thickness is composed of stroma.
4. **Descemet's membrane:** A strong, homogenous modified basement membrane of the corneal endothelium, which bounds the stroma posteriorly. It is resistant to chemicals, trauma and pathological process. Unlike bowman's membrane descemet's membrane can regenerate.
5. **Corneal endothelium:** it is simple squamous, approx 5 μ m thick, of mitochondria-rich cells responsible for regulating fluid and solute transport between the aqueous and corneal stromal compartments. Unlike the corneal epithelium the cells of the endothelium do not regenerate. If the endothelium does not maintain a proper fluid balance, stromal swelling and subsequent loss of transparency will occur and this may cause corneal edema.

Innervation

It is densely innervated with sensory nerve fibres via the ophthalmic division of the trigeminal nerve by long and short ciliary nerves.

CORNEAL ULCER (ULCERATIVE KERATITIS)

Corneal ulcer may be defined as discontinuation of normal epithelial surface of cornea associated with necrosis of the surrounding corneal tissue. It is characterized by oedema and cellular infiltration.

Cornea is protected by normal defence mechanisms present in tears. Normal corneal epithelium cannot be penetrated by any organism except diphtheria bacillus and gonococcus.

Pre-conditions for an ulcer to develop are:

1. Trauma to the corneal epithelium as by a minute foreign body, misdirected eyelash or conjunctival concretion.
2. Unhealthy condition of epithelium due to persistent oedema as in absolute glaucoma.

These preconditions are then followed by infection. The infection may be exogenous, carried by a foreign body or local from conjunctivitis or dacryocystitis. Thus after the infection has settled, there is necrosis of corneal tissue which is sloughed off and an ulcer is formed.

Symptoms of corneal ulcer

- Pain in the eye due to exposure and irritation of the sensory nerve endings.
- Lacrimation which may be profuse, due to reflex sensory stimulation.
- Photophobia - i.e. intolerance to light.
- Headache and blurring of vision.

Signs of corneal ulcer

- Marked blepharospasm i.e. forcible closure of eyelids due to sensory irritation. The eye lids may be oedematous.
- Rough and raw yellowish white area on the cornea which stains with fluorescein.
- Haziness of the cornea surrounding the ulcerated area.
- Ciliary congestion with conjunctival hyperaemia.
- Profuse watering but usually no muco-purulent discharge.
- The iris is slightly muddy in colour and the pupil is small.

Treatment of corneal ulcer**1. Treatment of uncomplicated corneal ulcer**

- Specific treatment for cause like topical or systemic antibiotics.
- Non specific supportive therapy like cycloplegic drugs, systemic analgesics and vitamins (A, B complex and C).
- Physical and general methods like hot fomentation, wearing dark goggles, rest and good diet.

2. Treatment of Perforated Corneal Ulcer

- Depending on the size of the perforation, measures like tissue adhesive glue, covering with conjunctival flap etc should be adopted.
- Best option is an urgent therapeutic keratoplasty.

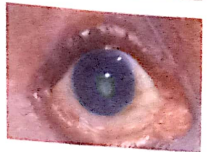


Fig. 6.2

CORNEAL OPACITY

Corneal opacification or corneal opacity literally means loss of normal transparency of cornea.

Etiology

Congenital corneal opacities are uncommon. Permanent corneal opacities are due to corneal ulcer, deep keratitis, dystrophy or degeneration. The corneal tissue is destroyed and replaced by disorderly arranged fibrous lamellae covered with thick irregular epithelium.

Clinical features

Visual disturbances and cosmetic disfigurement are the common symptoms. The visual impairment caused by corneal opacity may vary depending on its site and density. The opacity situated in the periphery of the cornea does not affect vision while opacity in the pupillary area causes loss of vision.

Types of Corneal Opacity

Depending on its density the corneal opacity is called as :

- **Nebula:** It is a faint opacity which results due to superficial scars in the Bowman's layer and superficial stroma.
- **Macula:** It is a semi dense opacity produced when scarring involves about half the thickness of corneal stroma.
- **Leucoma (leucoma simplex):** It is a dense white opacity which results due to scarring of more than half the thickness of corneal stroma.

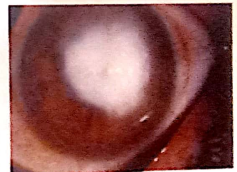

Fig. 6.3

Treatment

- There is no satisfactory medical treatment for corneal opacity. The surgical procedures indicated are :

- Optical iridectomy: performed in cases with central corneal opacities.
- Photo therapeutic keratectomy (PTK): is performed in superficial corneal opacities (nebula).
- Keratoplasty: performed in uncomplicated cases with corneal opacities.
- Coloured contact lens and tattooing of scar is performed for cosmetic purposes.

UVEAL TRACT

Anatomy

The uvea is the vascular layer of the eye and comprises the iris, ciliary body and choroid.

Iris

Iris is a delicate diaphragm placed between the cornea and the lens. The iris is attached at its root to the middle of the anterior surface of the ciliary body. The iris stroma is loosely arranged collagenous network in which the sphincter pupillae muscle, vessels and nerves of the iris pigment cells are embedded.

Ciliary Body

The ciliary body is roughly triangular in cross section with base forward. It extends anteriorly to the scleral spur and posteriorly as far as ora serrata. The ciliary body is composed of unstriated ciliary muscle fibres, stroma and blood vessels.

Choroid

The choroid is a thin vascular membrane extending from the optic disc to ora serrata. It is largely composed of layers of large and small vessels, pigment cells, smooth muscle fibres and nerves.

UVEITIS

The inflammation of the uveal tract is known as uveitis. Since the uveal tract is a vascular membrane, the inflammatory process tends to affect the uvea as a whole and does not remain confined to a single part. However, clinically there is always some associated inflammation of the adjacent structures such as retina, vitreous, sclera and cornea.

Causes

- Exogenous infections: eg. A penetrating injury

- Local causes: eg. Trauma, corneal ulcer, scleritis, herpetic infection, intraocular malignant tumor, sympathetic ophthalmia, orbital cellulitis etc.
- Non-specific causes due to allergy: Eg. tubercular allergy.
- Specific causes : eg. Tuberculosis, syphilis, gonorrhoea, virus infection.
- Systemic causes : eg. Rheumatism, gout, diabetes mellitus, sarcoidosis, ankylosing spondylitis, septicemia condition.
- Age and Sex: May occur in any age and equally in both the sexes.

Symptoms

- Pain: The ocular pain is usually referred along the branches of 5th cranial nerve. The pain is worst at night.
- Redness: Due to the circumcorneal congestion.
- Photophobia.
- Lacrimation.
- Defective vision or blurriness of vision.

Signs

- Lid oedema.
- Circumcorneal congestion.
- Corneal signs such as corneal oedema, keratic precipitates, posterior corneal opacity.
- Anterior chamber signs such as aqueous cells, aqueous flare, hypopyon (sterile pus in the anterior chamber) or hyphaema (blood in the anterior chamber).
- Pupil is small, inactive and irregular due to formation of synechia i.e. adhesion between pupillary margin and the anterior lens capsule and muddy colour of iris.
- Opacities in the vitreous.

Differential diagnosis

Acute red eye- Acute iridocyclitis must be differentiated from other causes of red eye such as Acute congestive glaucoma and Acute conjunctivitis.

Treatment of uveitis

• Local therapy

- Cycloplegic drugs- commonly used drug is atropine sulphate eye ointment or drops instilled 2-3 times a day.
- Cortico steroids- reduce inflammation by their anti inflammatory effect, being anti allergic are of special use in allergic type of uveitis.
- Broad spectrum antibiotic drops are usually prescribed along with steroidal preparations.

• Systemic therapy

- Corticosteroids- Usually treatment is started with high doses of prednisolone.
- Non steroidal anti inflammatory drugs such as aspirin, phenylbutazone.
- Immunosuppressive drugs can be used in extremely severe cases of uveitis in which vigorous use of steroids have failed to resolve the inflammation.
- Antibiotics such as azithromycin, tetracycline or erythromycin can be helpful.

• Physical measures

- Hot fomentation diminishes pain and increases circulation as a result more antibodies are brought and toxins are drained.
- Dark goggles gives a feeling of comfort specially when used in sunlight.

STAPHYLOMA

A staphyloma is an abnormal protrusion of the uveal tissue through a weak point in the eyeball. The protrusion is generally black in colour due to the inner layers of the eye. It occurs due to weakening of outer layer (cornea or sclera) by an inflammatory or degenerative condition.

Types

Anatomically it can be divided into:

- Anterior staphyloma: As a result of total sloughing of cornea with iris plastered behind.
- Ciliary staphyloma: Due to bulging of the weak sclera lined by ciliary body. It occurs about 2- 3 mm away from the limbus.

- Intercalary staphyloma: It is localized bulge in limbal area lined by root of iris. It results due to ectasia of weak scar tissue formed at the limbus following healing of a perforating injury or a peripheral corneal ulcer.
- Equatorial staphyloma: It results due to bulge of sclera lined by the choroid in the equatorial region.
- Posterior staphyloma: It refers to bulge of weak sclera lined by the choroid behind the equator. Here again the common causes are pathological myopia, posterior scleritis and perforating injuries.

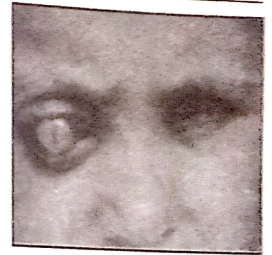

Fig. 6.4

Treatment

Intercalary staphyloma is treated by localized staphylectomy under heavy doses of oral steroids.

Review Questions

1. Classify Krishnamandala rogas based on predominance of doshas.
2. Describe sādhyā asādhya of Savṛṇashukla.
3. Write lakshana and chikitsa sutra of Kshata shukra.
4. Describe Shuddha shukra lakshana.
5. Name some Anjana yogas used in Avṛṇa shukra.
6. Write in detail about Pakātyaya shukra.
7. Explain Ajakajātha lakshana.
8. Describe types of corneal opacity.
9. Describe the layers of Cornea.
10. Describe doshas involved and lakshana of Sira shukra.

Research Updates

1. Study on the efficacy of Kukkutādyā anjana in the management of Avṛṇa shukla.
2. Effect of Shankadi rasakriyanjana in the management of Avṛṇa shukla wsr to corneal opacity. Dr. Akil Jain 2006, SDM College of Ayurveda & Hospital, Hassan. RGUHS-Karnataka.

Scope for Research

1. Study on the efficacy of Tāmra bhasmadi anjana in the management of Savṛṇa shukra.
2. Analyse the sādhyā asādhya of Savṛṇa shukra based on the features of corneal ulcer.

Chapter-7**SARVAGATA ROGA**

(DISEASES AFFECTING ALL PARTS OF EYE)

- | |
|--|
| A. Number of Sarvagata rogas, detailed knowledge of etiology, pathology, clinical features, complications, differential diagnosis and management of Abhishyanda, Adhimantha, Hathadhimantha and Shushkākshipāka. |
| B. Brief Knowledge of Amloshita, Vāta paryaya, Anyatōvāta, Sashopha & Ashophakshipāka, Pilla roga, Sirōtpāta and Sirāharsha. |
| C. Knowledge of Conjunctivitis, Glaucoma, Dry Eye Syndrome including their etiology, pathology, clinical features, differential diagnosis, complications and management. |

Chapter

7A

- Classification of Sarvagata Rogas
- Abhishyanda- Types and Management
- Adhimantha- Types and Management
- Sādhyāsadyata of Adhimantha
- Hathādhimantha
- Shushkāshipāka
- Akshipākātyāya

SARVAGATA ROGAS

The term 'Sarvagata' refers to all the parts of the eye including all mandalas and sandhis. Since drushti mandala has close proximity to krishnamandala, description of drushtigata rogas should have followed the krishnagata rogas. But Sushruta has described sarvagata rogas after krishnagata rogas. This may be because sandhi, vartha, shukla and krishnagata rogas are caused by Abhishyanda which is explained in Sarvagata rogas. Moreover Abhishyanda is not a cause for timira etc diseases explained in drushtigata rogas.

CLASSIFICATION OF SARVAGATA ROGA

स्यन्दास्तु चत्वार इहोपदिष्टास्तान् एवेह तथाऽधिमन्थाः । शोफान्वितोऽशोफयुतश्च पाकावित्येवमेते दश सम्यदिष्टाः ॥
हताधिमन्थोऽनिलपर्ययश्च शुष्काक्षिपाकोऽन्यत एव वातः । दृष्टिस्तथाऽम्लाध्युषिता सिराणामुत्पातहर्षावपि सर्वभागाः ॥
(S.U.6/3-4)

According to Sushruta : 17 According to Vāgbhata : 16

S.No.	Sushruta	Vāgbhata
1.	Vātaja abhishyanda	Vataja abhishyanda
2.	Pittaja abhishyanda	Pitaja abhishyanda
3.	Kaphaja abhishyanda	Kaphaja abhishyanda
4.	Raktaja abhishyanda	Raktaja abhishyanda
5.	Vātaja adhimantha	Vataja adhimantha

Sarvagata Roga

205

S.No.	Sushruta	Vāgbhata
6.	Pittaja adhimantha	Pittaja adhimantha
7.	Kaphaja adhimantha	Kaphaja adhimantha
8.	Raktaja adhimantha	Raktaja adhimantha
9.	Hathādhimantha	Hathādhimantha
10.	Sashopha akshipāka	Sashopha akshipāka
11.	Ashopha akshipāka	Ashopha akshipāka
12.	Shushkākshipāka	Shushkākshipāka
13.	Amladyushita	Amlashita
14.	Anyatōvāta	Anyatōvāta
15.	Vātaparyaya	Vataparyaya
16.	Sirōtpāta	Akshipākātyāya
17.	Sirāharsha	

(Vāgbhata has included Sirotpāta & Siraharsha in Shuklagata rogas and Akshipākātyāya in Sarvagata roga).

Classification based on predominance of Dosha

Vataja	Pittaja	Kaphaja	Raktaja	Sannipataja
1. Vataja Abhishyanda	1. Pittaja Abhishyanda	1. Kaphaja Abhishyanda	1. Raktaja Abhishyanda	1. Sashopha Akshipāka
2. Vataja Adhimantha	2. Pittaja Adhimantha	2. Kaphaja Adhimantha	2. Raktaja Adhimantha	2. Ashopha Akshipāka
3. Hathādhimantha	3. Amladyushita		3. Sirōtpāta	
4. Anila paryaya			4. Sirāharsha	
5. Anyatōvāta				
6. Shushkākshipāka				

Classification based on Sādyā-Asādyatha

Vyadhana sādyā	Ashastrakruta	Asādyā
a. 4 types of Abhishyanda	Amladyushita	Hathādhimantha
b. 4 types of Adhimantha	Shushkākshipāka	
c. Anyatōvāta		

d. Vāta paryaya		
e. Sirotpāta		
f. Sirāharsha		
g. Saṣopha akshipāka		
h. Asópha akshipāka		

ABHISHYANDA

Abhi- From all sides, **Syanda-** Discharge

Synonyms: Syanda, Abhisyanā, Akshikōpa

Abhishyanda is the main disease in Sarvagata rogas. It is characterized by excessive discharge from all sides of eye. It is a Sankramika roga (contagious disease) and if neglected leads to other complicated eye diseases and also spreads from one person to other.

प्रसङ्गात्तत्रसंस्पर्शात्रिंशत्सात् सहभोजनात् । सहशय्यासनाच्चापि वस्त्रमाल्यानुलेपनात् ।
कुष्ठं ज्वरश्च शोषश्च नेत्राभिव्यन्द एव च । औपसर्गिकरोगाश्च सङ्क्रान्ति नरात्ररम् ॥ (S.Ni.5/33-34)

Importance of Abhishyanda

प्रायेण सर्वे नयनामयास्तु भवन्त्यभिव्यन्दनिमित्तमूलाः ।
तस्मादभिव्यन्दमुदीर्यमाणमुपाचरेदाशु हिताय धीमान् ॥ (S.U.6/5)

Prāyena- Mostly **Sarve-** All **Nayana-** Eye **Āmaya-** Diseases

Bhavanti- Produced from **Nimittamulaha-** Root cause

Tasmat- Therefore **Udiryamanam-** Occurred **Upacharet-** Treat

Aashu- Immediately **Hitaaya-**Benefit **Dhimaan-** Intelligent.

Abhishyanda is considered as the root cause of almost all the eye diseases. Therefore Abhishyanda should be treated at the earliest by an intelligent physician.

Nidana: The Nidanas for Abhishyanda are:

1. **Nija** (internal cause)- Due to vitiation of doshas.
2. **Aganthuja-** Due to external causes.

Abhishyanda is classified in four types: Vātaja, Pittaja, Kaphaja and Raktaja.

1. Vataja Abhishyanda (Subacute catarrhal conjunctivitis/Allergic conjunctivitis)

It is a Vātaja Vyadha Sādhyā Vyādhi.

निस्तोदनं स्तम्भनरोमहर्षसङ्घर्षपारुष्यशिरोभितापाः ।
विशुष्कभावः शिशिराश्रुता च वाताभिपन्ने नयने भवन्ति ॥ (S.U.6/6)

Nistōdana- Pricking pain

Stambhana- Stiffness

Romaharsha- Horripilations

Sangharsha- Foreign body sensation

Pārushya- Roughness

Shirōbhitāpa- Headache

Vishushkabhāva- Dryness

Shishirashrūta- Cold discharge/lacrimation.

Vataja abhishyanda is a condition which is characterized by pricking pain, stiffness, horripilations, foreign body sensation, roughness, headache, dryness and cold discharge from eyes.

According to Vāgbhata

वनेन नेत्रे अभिव्यङ्गणे नासानाहो अल्पशोफता । शंख अक्षि भू ललाटस्य तोद स्फुरण भेदनम् । शुष्क अल्प दृषिका शीतं अच्छं च अश्रु चला रुजः । निमेष उन्मेषणं कृष्टात् जन्तूनामिव सर्पणं । अक्षि आध्मातमिवाभाति सूक्ष्मे शल्यैः इव आचितम् । स्निग्ध उष्णैश्च उपशमनम् सोऽभिव्यन्दः । (A.H.U.15/1-3)

Vātena- Due to vāta

Abhishyanne- (Aardribhute) oozing

Alpa shōphata- Mild swelling

Shankha- Temple

Akshi- Eyes

Bhru- Eyebrow

Lalaatasya- Forehead

Toda- Pricking pain

Sphurana- Throbbing

Bhedana- Piercing type

Shushka- Dry

Alpa- Less

Dooshika- Eye discharge

Sheeta- Cold

Accha- Clear

Ashru- Tears

Chala- Moving

Ruja- Pain

Nimesha- Closing

Unmesha- Opening of lids

Kruchraat- With difficulty

Jantoonam iva- Like insects

Sarpana- Crawling

Akshi- Eyes

Aadhmaata iva aabhaati- As if filled

Sookshmaih- Small

Shalyaihi- Foreign particles

Aachitam- Covered

Snigdha- Unctuous

Ushna- Hot

Upashamana- Alleviates.

The characteristic features of Vātaja Abhishyanda are:

- Type of pain: Pricking, throbbing and piercing.
- Site of pain: Temporal region, eyes, eyebrows and forehead.
- Discharge: Dry scanty or excessive discharge with clear cold lacrimation.
- Painful movement of eyes, difficulty in opening and closing of eyes, nasal blockage and mild swelling.
- Patient feels as though insects are moving in the eyes and are filled with small foreign bodies.
- Patient gets relief with unctuous (snigdha) and hot (ushna) measures.

2. Pittaja Abhishyanda

(Acute Catarrhal Conjunctivitis/Purulent Conjunctivitis)

It is a Pittaja Vyadhana Sādhya Vyādhi.

दाहप्रपाकौ शिशिराभिनन्दा धूमायनं बन्धसमुच्छ्रयश्च। उष्णाश्रुता पीतकनेत्रता च पित्ताभिपन्ने नयने भवन्ति। (S.U.6/7)

Dāha-Burning sensation

Prapāka- Severe inflammation

Shishiraabhinanda- Desire for cold Dhumāyana- As though smoke is coming out

Bhashpasamucchraya- Excessive lacrimation Ushna ashruta- Hot lacrimation

Peetaka netrata- Yellowish discolouration of eyes.

Pittaja abhishyanda is a severe inflammatory condition characterized by burning sensation, excessive hot lacrimation and yellowish discolouration of eyes. Patient feels as though smoke is coming out of eyes and desires for cold things.

According to Vāgbhata

दाहो धूमायनं शोफः श्यावता वर्त्मनो बहिः। अन्तः क्लेदो अश्रु पीतोष्णं रागः पीताभ दर्शनं। क्षारोक्षितकषा अक्षित्वं पित्ताभिष्यन्द लक्षणम्। (A.H.U.15/8-9)

Dāho- Burning sensation Dhoomayana- Feels like smoke is coming out

Shópha- Swelling

Shyāvata- Bluish black

Vartmano- Lids

Bahi-Outside

Antah- Inside

Kleda- Moistness

Ashru- Tears

Peeta- Yellow

Ushnam- Hot

Rāga- Lohitavam/redness

Peetabha- Like yellow

Darshana- To see

Ksharokshita- Affected or injured by kshāra

Kshata- Wound

Akshi- Eyes.

The characteristic features of Pittaja Abhishyanda are:

- Burning sensation as though smoke is coming out from the eyes.
- Swelling of eyelids externally with bluish black discoloration and moistness (kleda) within the lids.
- Redness of eyes with yellowish hot discharge.
- Yellowish appearance of objects.
- Eye appears as though it is burnt by kshāra (alkali).

3. Kaphaja Abhishyanda

(Acute Mucopurulent Conjunctivitis)

It is a Kaphaja Vyadhana Sādhya Vyādhi.

उष्णाभिनन्दा गुरुताऽक्षिशोफः कण्डूपदेहौसितताऽतिशैत्यम्।

स्त्रावोऽमुहुः पिच्छिल एवं चापि कफाभिपन्ने नयने भवन्ति। (S.U.6/8)

Ushna abhinanda- Desire for warmth Guruta- Heaviness

Akshishopa- Swelling in the eye

Kandu- Itching Upadēho-Sticky discharge

Sitata- White in colour

Atishaitya- Very cold Srāvo- Discharge

Muhuhu- Repeated

Picchila- Slimy

Kaphaja abhishyanda is characterized by repeated discharge which is cold, slimy, white and sticky in nature. It is associated with heaviness and swelling in the eyes. The patient desires for warm things.

According to Vagbhata

स्यन्दे तु कफ सम्भवे। जाड्यं शोफो महान् कण्डूनिद्रा अन्नानभिनन्दनम्।

सान्द्र सिग्ध बहुधृत पिच्छावहूषिकाश्रुता। (A.H.U.15/10)

Jaadyam- Laziness

Shopho- Swelling

Mahān- Large

Kaṇḍu- Itching

Nidra- Sleep

Anna anabhinandana- No interest to take food

Saandra- Thick

Snigdha- Unctuous

Bahu- Profuse/much Shveta- White

Piccha- Slimy

Dooshika- Netra mala

The Characteristic features of Kaphaja Abhishyanda are:

- Swelling of the eyes.
- Itching in the eyes.
- Profuse, thick, slimy, unctuous, whitish discharge.
- Patient feels lethargic and sleepy.
- Lacks interest towards food.

4. Raktaja Abhishyanda (Acute Mucopurulent Conjunctivitis)

It is a Raktaja Vyadhana Sādhya Vyādhi.

ताम्राश्रुता लोहितनेत्रता च राज्यः समन्तादतिलोहिताश्च । पित्तस्य लिङ्गानि च यानि तानि रक्ताभिपन्ने नयने भवन्ति । (S.U.6/9)

Tāmra ashruta- Coppery red coloured discharge **Lohita netrata-** Redness of eye

Cha- and **Rajya-** Striations (of blood vessels) **Samantad-** All over

Atilohita- Deep red **Pittasya lingani cha yaani-** Similar symptoms of pitta

Raktaja abhishyanda is a condition in which, the eyes become red due red coloured siras present all over the eyes. The tears are also coppery red in colour. Besides these, symptoms of pittaja abhishyanda like burning sensation, inflammation, desire for cold things etc are also seen.

According to Vāgbhata

रक्ताश्रु राजी दूषीका रक्तमण्डल दर्शनम् । रक्तस्यन्देन नयनं सपित्तस्यन्द लक्षणम् ।। (A.H.U.15/12-13)

Rakta- Red **Ashru-** Tears **Rāji-** Lines **Dooshika-** Netra mala

Raktaja abhishyanda is a disease characterized by red coloured lacrimation, exudates and blood vessels. The whole mandala becomes red in colour. The other lakshanas are similar to pittaja abhishyanda.

ADHIMANTHA (Glaucoma/Uveitis)

Adhi- Excessive **Mantha-** Churning type of pain

वृद्धैरेतैरभिध्यन्दैर्नराणामक्रियावताम् । तावन्तस्त्वधिमन्थाः स्युर्नयने तीव्रवेदनाः ।। (S.U.6/10)

Vridhdhaihi- Aggravated **Ethaihi-** These **Akriyaavatam-** When not treated **Tavantastu adhimantha-** Will lead to respective.

Syurnayane- In eyes **Teevra vedana-** Severe pain.

If Abhishyanda is not treated, the symptoms get further aggravated leading to respective Adhimantha. For eg. Vataja abhishyanda if left untreated leads to Vataja adhimantha. Similar is the case with all other types of adhimantha. 'Severe pain' in the eyes is the characteristic feature of Adhimantha.

Adhimantha samānya lakshana

उत्पाद्यत इवात्यर्थ नेत्रं निर्मथ्यते तथा । शिरसोऽर्धं च तं विद्यादधिमन्थं स्वलक्षणैः ।। (S.U.6/11)

Utpāyata eva- As though pulled out **Netram-** Eye **Atyartham-** Severe

Nirmarthate- Churning type of pain **Tatha** and **Shiraso ardham-** Half of the head

Tam vidhyaat- That is called as **Swalaxanaihi-** Along with the symptoms of respective doshas.

Adhimantha is characterized by severe pain in half part of the head.

Type of pain: It is similar to the pain experienced on pulling out the eyes from the socket or churning. Apart from these symptoms, features of the respective doshas are also seen.

Types of Adhimantha: It is of four types-Vātaja, Pittaja, Kaphaja and Raktaja.

1. Vātaja Adhimantha (Acute Congestive Glaucoma)

It is a Vātaja Vyadhana Sādhya Vyādhi.

नेत्रमुत्पाद्यत इव मथ्यतेऽरणिवच्च यत् । सङ्घर्षतोदनिर्भेदमांससंरब्धमाविलम् ।।

कुञ्चनास्फोटनाध्यानवेपथुव्यथनैर्युतम् । शिरसोऽर्धं च येन स्यादधिमन्थः स माततात् ।। (S.U. 6/12-13)

Utpātya- Pulling pain **Mathyate-** Churning **Aranivat-** With pestle

Sangharsha- Foreign body sensation **Tōda-** Pricking pain

Nirbheda- Tearing pain **Māmsa samrabdha-** Swelling of muscle

Avila- Muddy eyes **Kunchana-** Twisting **Sphōtana-** Bursting

Adhmāna- Tension **Vepathu-** Tremours

Shiraso ardham- Half part of the head

Vātaja Adhimantha is characterized by:

- **Type of pain:** Severe pain as though eye is pulled out from the socket, eye is churned with pestle, pricking, tearing, squeezing and bursting.
- **Site of pain:** Half side of the head including the eye.
- Foreign body sensation, swelling of eye muscles, muddy, tensed eyes and twitching of the eyes.

According to Vāgbhata

उपेक्षितः ।

अधिमन्यो भवेत् तत्र कर्णयोर्नदनं भ्रमः । अरण्येव च मध्यन्ते ललाट अक्षि भ्रुवादयः ॥ (A.H.U.15/3-4)

Upekshita- If neglected Bhavet tatra- Causes Karnanada- Tinnitus
 Bhrama- Giddiness Arani- Pestle Mathyate- Churning

If Vātaja abhishyanda is neglected, it leads to Vātaja adhimantha, which is characterized by tinnitus, giddiness and churning type of pain in the forehead, eyes, eyebrows etc.

2. Pittaja Adhimanta (Acute Congestive glaucoma)

It is a Vyadhana Sādhyā Vyādhi.

रक्तराजिचितं स्त्रावि वह्निनेवावदहते । यकृत्यण्डोपमं दाहिक्षारेणाक्तमिवक्षतम् ॥
 प्रपक्वोच्छूनवत्मानं सस्वेदं पीतदर्शनम् । मूर्च्छाशिरोदाहयुतं पित्तेनाक्षयधिमन्यितम् ॥ (S.U.6/14-15)

Rakta- Red Rāji- Streaks Srāva- Discharge Vahni- Fire

Avadahana- Burning Yakrit pindopama- Like piece of liver

Daahi ksharenaktamiva kshata- Burning sensation like wound applied with alkali

Pra pakava shunam- Completely suppurated swelling Vartma- Lid

Sa sweda- sweat Peeta darshana- Yellowish appearance of objects

Murcha- Unconscious, Shiro daha yutam- Burning sensation of head.

Pittaja Adhimantha is characterized by :**Signs**

- **Redness:** of eyes like capillary network or like a section of liver.
- **Swelling:** the edges of the eyelids will be inflamed and swollen.
- **Discharge:** yellow coloured.

Symptoms

- Burning sensation: as though burnt by fire or kshāra being applied over wound.
- Objects appear yellow in colour.
- The patient may faint due to severe pain and burning sensation.

According to Vāgbhata

ज्वलदङ्गारकीर्णाभं यकृत्यण्डसमप्रभम् । अधिमन्ये भवेत्त्रेत्रं..... । (A.H.U.15/9)

Jvalad angaara- Like burning coal Yakrut pinda- Liver

Vagbhata also has similar view and describes the colour of the eyes, similar to that of piece of yakrit and burning sensation similar to burning of coal.

3. Kaphaja Adhimantha (Simple Chronic Glaucoma)

It is a Kaphaja Vyadhana Sādhyā Vyādhi.

शोफवन्नातिसंरब्धं स्त्रावकण्डूसमन्वितम् । शैत्यगौरवपैच्छिल्यदूषिकाहर्षणान्वितम् ॥
 रूपं पश्यति दुःखेन पांशुपूर्णमिवाविलम् । नासाध्मानशिरोदुःखयुतं श्लेष्माधिमन्यितम् ॥ (S.U.6/16-17)

Shópha- Swelling

Na ati samrabdhām- Mild congestion

Srāva- Discharge

Kandu- Itching

Shaitya- Cold

Gourava- Heaviness

Paichilya- Sticky

Dūshika- Muddy appearance

Harsha- Horripilation

Rupam Pashyati Dukhena- Visualizes objects with difficulty

Pamshupurnamiva avilam- Eyes become hazy as if filled with sand

Nāsādhmana- Fullness/blockage in the nose

Shirodukha- Headache.

Kaphaja adhimantha is a disease characterized by swelling associated with mild congestion, discharge and itching in the eyes. There will be stickiness, heaviness and muddy appearance of eyes with cold sensation and horripilation. Patient visualizes the objects with difficulty. The visualized objects appear hazy as if filled with sand or dust. It is also associated with symptoms like headache and blockage in the nose.

According to Vāgbhata

अधिमन्ये नतं कृष्णमुन्नतं शुक्लमण्डलम् ॥ प्रसेको नासिकाध्मानं पांशुपूर्णमिवेक्षणम् । (A.H.U.-15/11)

Natam- Depressed

Krishnam- Krishna mandala

Unnatam- Raised

Shukla mandala- Sclera Praseko- Saliva Nāsikādhmaana- Nose block
Pamshu- Sand Poorna- Filled Eekshanam- Eyes.

The Characteristic features of Kaphaja Adimanthas are:

- Depressed krishna mandala and elevated shukla mandala.
- Excessive salivation and nasal blockage.
- Patient visualizes hazy as though eyes are filled with sand/dust.

4. Raktaja Adhimantha (Iridocyclitis/Secondary Glaucoma)

It is a Raktaja Vyadhana Sādhya vyadhi.

बन्धुजीवप्रतीकांशं ताम्यति स्पर्शनाक्षमम् । रक्तास्त्रावं सनिस्तोदं पश्यत्यग्निनिभा दिशः ॥
रक्तमग्नारिष्टवच्च कृष्णभागश्च लक्ष्यते । यदीपां रक्तपर्यन्तं तद्रक्तेनाधिमन्यितम् ॥ (S.U.6/18-19)

Bandhujeevaprateekasha- Eyes look like bandhujeeva flower (hibiscus)

Tamyati- Black-outs Sparshana akshamam- Intolerance to touch

Raktasrāva- Bleeding or bloody discharge Nistoda- Pricking pain

Pashyati agnini-bha disha- Visualizes fire in all directions

Raktamagna- Immersed in blood Arishta- Soapnut Krishnabhāga-In cornea

Yat deepam- Glows like Raktaparyanta- Surrounded/filled with blood.

Raktaja adhimantha is characterised by the following features:

- Eyes appear red like that of bandhujeeva (hibiscus flower)
- Experiences black-outs in front of eyes.
- Intolerance to touch, bloody discharge, pricking pain and burning sensation in the eyes.
- Patient visualizes flame and redness in all the directions.
- Krishna mandala appears as if soapnut is immersed in the blood.

According to Vāgbhata

मन्येऽक्षि ताम्रपर्यन्तमुत्पादनसमानरुक् ॥
रागेण बन्धुकिनिभं ताम्यति स्पर्शनाक्षमम् । असुङ्गिमग्नारिष्टाभं कृष्णमग्न्याभदर्शनम् ॥
अधिमन्या यथास्वं च सर्वे स्यन्दाधिकव्यथाः । शन्खदन्तकपोलेषु कपाले चातिरुक् कराः ॥ (A.H.U.15/13-15)

Taamra- Coppery red

Ruk- pain

Bandhooka- Redness like flower of hibiscus

Sparshana-ksham- Tenderness

Nimagna- Dipped

Krishnam- Krishna mandala

Yathaswam- Like

Paryanta- Throughout

Raagena- Redness

Arishta- Nimba

Agni- Fire

Sarve- all

Utpaatana- Pulled out

Taamyati- Anxious

Asruk- Rakta

Darshanam- To see

Adhika vyatha- Severe symptoms Ati rukkara- Severe pain.

The characteristic features of Raktaja Adhimantha are:

- Pain: as though eye is pulled out, severe pain in temporal region, teeth, orbit and scalp.
- Appearance: eye appears red like that of bandhuka pushpa or arishta phala dipped in blood. Krishna mandala looks like fire.
- Patient will be intolerant to touch and experiences blackouts.
- Raktaja adhimantha will have same features like that of raktaja abhishyanda but in severe form.

SĀDHYĀSADHYATA OF ADHIMANTHA

हन्यादृष्टिं सप्तरात्रात् कफोत्थोऽधीमन्थोऽसुखसम्भवः पञ्चरात्रात् ।
षड्रात्राद्वा मारुतोत्थो निहान्यान्मिथ्याचारात् पैत्तिकः सद्य एव ॥ (S.U.6/20)

If a person suffering from Adhimantha follows faulty regimen he is sure to lose his vision.

- In Kaphaja adhimantha - within 7 nights
- In Raktaja adhimantha - within 5 nights
- In Vataja adhimantha - within 6 nights
- In Pittaja adhimantha - sadya eva (immediately/within a day)

SĀMĀNYA CHIKITSA

The chikitsa for Abhishyanda and Adhimantha are same

1) Nidana parivarjana (Abhishyanda is the nidana in case of adhimantha)

2) During stage of Amāvasta: Any of these procedures mentioned below are done for 4 days or till Amapachana lakshanas are observed.

- Langhana
- Swédana
- Pralépa (Bidalā)
- Tiktānna bhojana
- Dhūma

3) Depending on the avastha and dosha, Snehana, Swedana, Sirāvyadha, Viréchanā, Basti, Aschotana, Pariséka, Pralépa, Abhyanga, Siróbasti, Nasya, Tarpana, Putapaka and Anjana are indicated in all kinds of Abhishyanda.

Bahirgundana is a special treatment procedure indicated in the purvaroopavastha of Abhishyanda where in churnas are sprinkled over closed eyes.

Eg: Powders of devadaru, ativisha, lodhra and saindhava.

Contraindications

Anjana, Ghrita, Kashaya rasa, Guru bhojana and Snāna are contraindicated in the amavasta of Abhishyanda.

Vataja Abhishyanda/Adhimantha Chikitsa

पुराणसर्पिषा स्निग्धौ स्यन्दाधीमन्थ पीडितौ ।
स्वेदयित्वा यथान्यायं सिरामोक्षेण योजयेत् । सम्पादयेद्वस्तिभिस्तु सम्यक् स्नेहविवेचितौ ॥
तर्पणैः पुटपाकैश्च धूमैराश्चयोतनेस्तथा । नस्यस्नेहपरीषेकैः शिरोवस्तिभिरेव च ॥ (S.U.9/3-4)

- Snehapana: Ghritapāna with purāna ghrita.
- Swedana.
- Sirāvyadha in upanasika or kapālastha sira.
- Snehā virechana with tilwaka ghrita.
- Basti : Anuvāsana (in dhātukshayajanya) and Nirūha.
- Tarpana: with any Vātahara ghrita.
- Putapāka: with Snaihika dravya.
- Snaihika Dhoomapana
- Aschótana (Sheetala prayoga):

- i. Ksheera prepared from usheera, yashtimadhu and pippali.
- ii. Hribera, tagara, manjista and udumbara boiled in goat's milk.
- Snehana Nasya: Shālaparni, dugdha and madhura dravya siddha taila.
- Seka (sukhoshana): Pallava, mula and twacha of eranda, ajapaya, sita-ksheerapaka kankari mula siddha ksheera.
- Sirobasti
- Anjana yogas
 - i. Paste prepared out of yashtimadhu, haridra, haritaki, devadaru triturated with ajadugdha.
 - ii. Gutikānjana: Swarna gairika, saindhava, pippali, shunthi triturated with ajadugdha.
- Pathya: Milk processed with vatahara drugs, triphala ghrita or purāna ghrita to be taken internally after meals.

Pittaja Abhishyandha/Adhimantha Chikitsa

पित्तस्यन्दे पैक्तिके चाधिमन्थे रक्तास्त्रावः संसर्गं चापि कार्यम् ।
अक्ष्णोः सेकालेपनस्याङ्गनानि पैत्ते च स्याद्यद्विषये विधानम् ॥ (S.U.10/3)

- Snehapana, swedana
- Sirā Mokshana.
- Viréchanā.
- Sthānika chikitsa: Séka.

Tarpana

Aalepa

Nasya

Anjana

- Pitta visarpa chikitsa

Ghrita for Tarpana and Nasya: Ghee prepared out of sheetala dravyas like shāli, dūrva, pāshāna bheda, rakta chandana, haridra, dāru haridra, nilotpala, lódhra, sariva, musta, anantamula, yashti madhu.

Séka : With ksheera pāka prepared out of the above drugs.

Aschótana: With gritha prepared with yashtimadhu and lodra.

Anjana yogas

- Rasakriya prepared out of sharkara, kshoudra, shyāma trivrit, yashti madhu.
- Rasakriya prepared out of musta, samudraphēna, utpala, vidanga, ela, amalaki, bijaka.
- Paste prepared out of taleesa patra, ela, swarnagairika, ushira and shaṅka bhasma in breast milk.
- Rasakriya prepared out of dhātaki and chaṇḍana with breast milk.

Kaphaja Abhishyanda/Adhimantha Chikitsa

स्यन्दाधिमन्थौ कफजौ प्रवृद्धौ जयेत् सिराणामथ मोक्षणेन । स्वेदावपीडाञ्जन धूमसेकप्रलेपयोगैः कवलग्रहैश्च ॥
रुक्षेस्तथाऽऽश्वोतनसंविधानैस्तथैव रुक्षैः पुटपाकयोगैः । त्र्यहात्यहाच्चाप्यतर्पणान्ते प्रातस्तयोस्तिक्रपृतं प्रशस्तम् ॥
तदन्नपानं च समाचरेद्धि यच्छलेष्मणेनैव करोति वृद्धिम् । (S.U.11/3-5)

- Apatarpana : Fasting for three days.
- Snehapana : With tiktaka gritha.
- Swedana : With leaves of tagara, pattura, peelu, arka, kapitta, phaninjya, nirgundi.
- Sirā mokshana
- Avapida nasya
- Anjana:-
- i. Varti prepared out of Saindhava, hingu, triphala, madhūka, prapoundarika, tuttha, triturated with water.
- ii. Varti prepared out of Trikatu, triphala, haridra, vidanga sāra.
- iii. Varti prepared out of Haritaki, haridra, yashtimadhu.
- iv. Hriversa, kushta, devadaru, shankha, patha, chitramula, trikatu and manashila.
- v. Kshārānjana.
- Dhoomapāna with kapha hara dravyas.
- Séka: Nimba patra, lodhra, mandara patra, ghrita and ksheera. (yoga ratnakara).

• **Pralépa**: Paste prepared with Hriversa, agaru, devadaru, kuṣhta.

• **Kavalagraha** with kaphahara dravyas.

• **Aschotana** with decoction prepared out of gomutra, tilwaka, brihati, nidagdhika, lódra, aragvadha mula tvak.

• **Tarpana**: Ghrita prepared with agaru, priyangu, nalada, devadaru and goat's liver.

• **Putapāka** with ruksha dravya: Goat's liver should be cooked with kushta, tagara, dārvi along with honey and ghee.

• **Pathya Apathya**: Annapāna which doesn't aggravate kapha.

Raktaja Abhishyadna/Adhimantha Chikitsa

मन्थं स्यन्दं सिरौत्पातं सिराहर्षं च रक्तजम् । एकेनैव विधानेन चिकित्सेच्चतुरोगदान् ॥
व्याध्यातश्चतुरोऽप्येतान् स्निग्धान्कौम्भेन सर्पिषा । रसेरुदारैरथवा सिरामोक्षेण योजयेत् ।
विरिक्तानां प्रकामं च शिरांस्येषां विशोधयेत् । वैरेचनिकसिन्धेन सितायुक्तेन सर्पिषा ॥
(मज्जा वा तद्विमिश्रेण मेदसा तच्छुतेन वा) । ततः प्रदेहाः परिषेचनानि नस्यानि धूमाश्च यथास्वमेव ।
आश्वोतनाभ्यञ्जनतर्पणानि स्निग्धाश्च कार्याः पुटपाकयोगाः ॥ (S.U.12/3-6)

Line of treatment indicated for Raktaja Adhimantha, Raktaja Abhishyandha, Sirotpāta and Sirāharsha are one and the same.

- Snēha pana: With kaumbha sarpi (10 year old ghee) or mamsa rasa.
- Raktamokshana is done thereafter.
- Virechana: Using trivritadi kalka siddha ghrita with sharkara.
- Shirovirechana : With ghrita and sharkara.
- Pradēha: Powders of pittaghna dravyas like nilotpala, ushira, dāru haridra, agaru, yashti madhu, lodhra, musta mixed with shatadhouta ghrita.
- Pariseka: Lodhra, triphala, yashtimadu, sharkara, bhadramustha with cold water.
- Nasya: Powders of sugar, madhuka and nilotpala, breast milk processed with ghritamanda.
- Dhūma
- **Aschotana and Séka**: Prepare a pottali with fine powders of kashēru and yashti madhu and keep this in a bowl of rain water. This water should be used for aschotana and seka.

- **Anjana** : Prepared using patala, arjuna, gambhari, dhataki pushapa, amalaki, bilwa twak, brihati, kantakari, bimbi, lodhra, manjishta with ikshu rasa.
- **Tarpana** with snigdha dravyas
- **Snehana Putapāka**
- **Internally**: Shadanga guggulu (Kashaya of triphala, patola patra, nimba twak and vasa kwatha mixed with guggulu).

HATHĀDHIMANTHA (Atrophic bulbi or Phtisis bulbi)

It is an Asādhya Vyādhī.

उपेक्षणादक्षि यदाऽधिमन्थो वातात्मकः सादयति प्रसह्य ।

रुजाभिरुयाभिरसाध्य एष हताधिमन्थः खलु नाम रोगः ॥ (S.U.6/23)

Upekshanat akshi yada adhimantho vatatmaka- If vataja adhimantha is neglected

Sadayati prasahya- Shrinking of eyes

Rujabhir ugra- Severe pain

Asadhya- Incurable.

If vataja adhimantha is neglected, it gives rise to severe pain and shrinking of eyes. This condition is called Hathādhimantha and is said to be incurable.

According to Vāgbhata

हताधिमन्थः सोऽपि स्यात् प्रमादात्तेन वेदनाः । अनेकरूपा जायन्ते व्रणो दृष्टौ च दुष्टिहा ॥

(A.H.U.15/16-17)

Pramaadaat- Carelessness/negligence

Vedana- pain

Aneka roopa jayante- Different type of pain

Vrano drishtou- Ulcer in drishti

Drishtiha- Loss of vision

Adhimantha if neglected leads to hathādhimantha which is characterized by different types of pain, ulcer in drushti and loss of vision.

SHUSHKĀKSHIPĀKA (Xerophthalmia/Ophthalmoplegia)

It is a Vātaja Sādhya Vyādhī.

यत् कृणतं दारुणरूक्षघर्त्तं विलोकेने चाविलदर्शनं यत् । सुदारुणं यत् प्रतिबोधने च शुष्काक्षिपाकोपहतं तदक्षि ॥

(S.U.6/24)

Koonitam- Constricted

Dārūna- Rough

Rūksha- Dry

Vartma- Eyelids

Vilokane- Visualize

Avila- Hazy

Sudarunam yat pratibodhane- Difficulty in opening of eye.

Shushkākshipāka is a disease condition in which the eyelids become dry, constricted, hard and rough. The patient visualizes objects as hazy and finds difficulty in opening the eyes.

According to Vāgbhata

वातपित्ततुरं घर्षतोदभेदोपदेहवत् । रूक्षदारुणवर्त्माक्षि कृच्छ्रोन्मीलनिमीलनम् ॥

विकृणनविशुष्कत्वशीतेच्छाशूलपाकवत् । उक्तः शुष्काक्षिपाकोऽयं ॥ (A.H.U.15/16-17)

Gharsha- Foreign body sensation

Toda- Pain

Bhēda- Cutting type of pain

Upadeha- Coating

Rooksha- Rough

Daruna- Hard

Vartma- Lids

Krichronmeelana- Opening lids

Nimeelana- Closing lids

Vikoonana- Akshi sankochana/constriction of eyes

Vishushka- Dry

Sheeta- Cold

Iccha- Desire

Shoola- Pain

Paaka- Suppuration

Features of Shushkākshipāka are :

- It is caused due to vitiation of vata and pitta.
- Characterized by foreign body sensation, pricking and cutting type of pain.
- The eyelid and eyes become dry, rough and coated.
- Difficulty in opening and closing of eyelids.
- Eye appears constricted and dry, associated with pain and inflammation.
- Patient desires for cold things.

Chikitsa

• **Anjana**

a. Saindhava, dāruharidra, shunti trichurated in matulunga swarasa, ghrita and stri dugdha.

b. Shunti trituated with sarpi and stanya.

• **Sarpi pāna** and tarpana: Jeevaneeya dravya sidda ghrita.

- Snehana putapāka
- Nasya: Anutaila or ghrita prepared from jeevaneeya dravyas.
- Parisēka
 - a) Kashāya prepared with ksheera and saindhava.
 - b) Kashāya prepared with haridra, daruharidra and saindhava.

AKSHIPĀKĀTYĀYA (Pan Ophthalmitis)

It is an Asādhya Vyādhi

Akshipākātyāya is described as Sarvakshi roga by Achārya Vagbhata and Achārya Sushruta has described it under krishnagata roga.

अक्षिपाकात्यये शोफः संरम्भः कलुषाश्रुता । कफोपदिग्धमसितं सितं प्रक्लेदरागवत् ॥
दाहो दर्शनसंरोधो वेदनाश्चऽनवस्थिताः । (A.H.U.15/20, 21)

Shopha- Swelling **Samrambha-** Severe pain **Kalusha ashru-** Dirty discharge
Kaphopadigdha- Kaphena lipta/covered **Asita-** Cornea **Sita-** White
Prakleda- Moist **Rāga-** Redness **Dāho-** Burning sensation
Darshana samrodha- Obstruction of vision **Vedana-** Pain
Anavasthitha- Intermittent

Akshipakātyāya means the whole eye is inflamed. It is characterized by the following features :

- Swelling, severe pain and dirty discharge from eyes.
- Coating of krishna mandala by kapha (whitish).
- Moistness and redness in shukla mandala.
- Burning sensation in the eyes.
- Obstruction of vision.
- Intermittent pain.

Chapter

7B

- | | |
|----------------|----------------------------|
| • Amladyushita | • Vāta Paryaya |
| • Anyatōvāta | • Akshipāka |
| • Pilla Roga | • Sirōtpata and Sirāharsha |

AMLADYUSHITA (Allergic conjunctivitis)

It is a Pittaja Sādhya Vyādhi.

अम्लेन भुक्तेन विदाहिना च सञ्छाद्यते सर्वत एव नेत्रम् । शोफान्वितं लोहितकैः सनीलेरेतादृग्गन्धुषितं वदन्ति ॥
(S.U.6/28)

Amlena bhuktena vidāhina- Due to intake of sour and vidāhi food

Samchadyate- Covered

Sarvata eva netram- Whole eyes

Shopha- Swelling

Lohitakaihi sa Neelaihi- Bluish red

Amladyushita is a condition occurring due to the intake of āmla and vidāhi āhara, wherein the whole eyes become swollen and gets covered with bluish red blood vessels, due to the vitiation of pitta.

AMLÓSHITA

Achārya Vāgbhata names Amladyushita as Amloshita

अन्नसारोऽप्लतां नीतः पित्तरक्तोल्बणैर्मलैः ॥ शिराभिर्नेत्रमारूढः करोति श्यावलोहितम् ।
सशोफदाहपाकाश्रु भृशं चाविलदर्शनम् ॥ अम्लोषितोऽयम् । (A.H.U. 15/21-22)

Annasaara- Saarabhaga of anna (end product of digestion) **Ulbanaih-** Excess

Aarudhah- Gains/attacks

Shyāva- Bluish black

Lóhita- Red

Shopha- Swelling

Dāha- Burning

Pāka- Suppuration

Ashru- Lacrimation

Avila darshna- Blurred vision

Amloshita is a condition in which the annasāra i.e. the end product of digestion undergoes amlata by mixing with malas formed due to the vitiation of pitta and

rakta. This further reaches the eyes to produce greyish or reddish discolouration. The other features produced in the eye are swelling, burning sensation, inflammation, severe lacrimation and blurred vision.

Chikitsa

एषोऽप्लाख्येऽनुक्रमश्चापि शुक्लौ कार्यः सर्वः स्यात्सिरामोक्षवर्ज्यः ॥ (S.U.10/13)

Treatment of Amladushita is similar to the treatment of pittaja abhishyanda. Even though raktamokshana is indicated in pittaja abhishyanda, it is contraindicated in amladushita, because it is an Ashastrakrutha vyadhi (surgeries are contraindicated).

VĀTA PARYAYA

(As per Sushruta: Ocular pain due to trigeminal neuralgia, glaucoma.

As per Vāgbhata: Atrophy of eyes/microphthalmos).

It is a Vātaja Sādhya Vyādhi

Synonyms: Vāta viparyaya, Syānda mārutha

पक्ष्मद्वयाक्षिभ्रुवमाश्रितस्तु यत्रानिलः सञ्चरति प्रदुष्टः । पर्यायशश्चापि रुजः करोति तं वातपर्यायमुदाहरन्ति ॥ (S.U.6/25)

Pakshmadvaya akshi bhru- Both eye lashes/lids, eye and eyebrows

Ashrita- Localized Yātra- Where Anila-Vāta Sancharati- Circulates

Pradushtaha- Vitiated Paryaya- Alternate Ruja- Pain Karoti- Does

Vataparyaya is a condition in which the vitiated vāta circulates and gets localized to produce pain in the eyes, eyebrows and eyelids alternatively (the pain shifts from eyes to eyebrows, to lids hence the name Vāta Paryāya).

According to Vāgbhata

तद्विजिह्वं भवेत्त्रेप्रमृत्तं वा वातपर्यये ॥ (A.H.U.15/7)

Tadvat- Like anyatovata Jihma- Deformity of eyes- Squint

Netram- Eyes Oonam- Small

Like in Anyatovata, the vitiated vāta produces deformity of the eyes. The eyes become small and appearance of the eye gets changed.

Chikitsa

Treatment for Vāta paryaya and Anyatovāta are similar to that of Vātaja Abhishyanda.

- Snehana, Swedana, Raktamokshana, Basti, Snehavirechana, Tarpana, Putapāka and Ghritapāna as in Vātaja Abhishyanda.
- Pariseka with Haridra, Dāruharidra and Saindhava siddha ksheera.

ANYATÓVĀTA (Referred pain in the Eye)

It is a Vātaja Vyadhana Sādhya Vyādhi.

Anyatovata means pain manifests in the eyes due to vitiated vata present in various other parts of the body.

यस्यावटूकणशिररोहनुस्थो मन्यागतो वाऽप्यनिलोऽन्यतो वा ।

कुर्याद्भुजोऽति ध्रुवि लोचने वा तमन्यतोवातमुदाहरन्ति ॥ (S.U.6/27)

Avatu- Back of neck Karna- Ear Shira- Head Manya- Nape of the neck
Hanu- Chin Ruja- Pain Bhru- Eyebrow Lochana- Eyes

The condition in which the vitiated vāta situated in other regions such as the back or nape of the neck, ear, head and chin produces pain either in the eyebrows or eyes is known as Anyatovāta.

According to Vāgbhata

मन्याक्षिशङ्कतो वायुरन्यतो वा प्रवर्तयन् । व्यथां तीव्रामपैच्छिल्यरागशोफं विलोचनम् ॥
सङ्कोचयति पर्यश्रु सोऽन्यतोवातसंज्ञितः । (A.H.U.15/6)

Manya- Nape of neck Akshi- Eyes Shankha- Temple

Anyato- Different direction Pravartayan- Proceeding Vyathaam- Pain

Teevra- Intense, Apicchilya- No Stickiness Raaga shopha- Redness and swelling

Shoppha- Redness and swelling Vilochanam- Eyes Sankochayati- Shrink

The vitiated vāta moves from different regions to cause severe pain in the nape of neck, eyes and temporal region. In this there will be no stickiness, swelling or redness. The eye becomes shrunken and there will be lacrimation. Such a condition is called Anyatovata.

Chikitsa

Treatment for Anyatovāta is similar to that of Vātaja Abhisandha

- Snehana, Swedana, Raktamokshana, Basti, Snehavirechana, Tarpana, Putapaka as in Vātaja Abhisandha.
- Sarpi and ksheera before food (S.U 9/18-20).
 - a) Vrikshadani, kapittha, panchamūla, karkata rasa, ksheera siddha ghrita.
 - b) Meshashringi, ksheera siddha ghrita.
 - c) Arjuna siddha ghrita.

AKSHIPĀKA (Cellulitis of Eyeball)

Akshi- Eyes Paka- Suppuration

Akshipaka means suppuration of the eyes.

Sashopha Akshipāka

If akshipāka is associated with oedema it is called "Sashopha Akshipaka" and if it is not associated with oedema, it is called 'Ashopha Akshipāka'.

It is a Tridoshaja Vyadhana Sādya Vyādhi.

कण्डूपदेहाश्रुयुतः पक्वोदुम्बरसन्निभः । दाहसहर्षताम्रत्वशोफनिस्तोदगौरवैः ।।

जुष्टो मुहुः सवेच्चासमुष्णशीताम्बु पिच्छिलम् । संरम्भी पच्यते यश्च नेत्रपाकः सशोफजः ।। (S.U.6/21-22)

Kandu- Itching	Upadeha- Sticky	Ashru- Lacrimation
Pakvodumbara sannibha- Resembles ripe fig.	Dāha- Burning sensation	
Samharsha- Horripilation	Tāmra- Copper	Shopha- Swelling.
Nistoda- Pricking pain	Gourava- Heaviness	Muhuhu- Repeated/frequent
Sravet cha ushna sheetambu- Cold and hot discharge	Picchila- Sticky	
Samrambha- Congestion		

Sashopha akshi paka is an inflammatory disease caused due to vitiation of tridoshas. The swelling resembles pakva udumbara (ripe fig.) and is coppery in colour with frequent cold or hot, sticky discharge. Symptoms such as burning sensation, horripilations, pricking pain and heaviness are also seen.

According to Vagbhata

सशोफः स्यात्त्रिभिर्मलैः ।

सरक्तैस्तत्र शोफोऽतिरुग्दाहष्ठीवनादिमान् । पक्वोदुम्बरसङ्काशं जायते शुक्लमण्डलम् ।।
अश्रूणाशीतविशदपिच्छिलाच्छयनं मुहुः । (A.H.U.15/17,18)

Tribhi malaih- Tridosha	Saraktha- Along with raktha	Ati ruk- Intense pain
Dāha- Burning sensation	Shteevanaadimaan- Spitting	
Pakva udumbara- Ripened fig.		
Sankaasham- Similar	Ashru- Tears/discharge	Shuklamandala- Sclera
Sheeta- Cold	Vishada- Clear	Ushna- Hot
Accha- Thin	Ghana- Thick	Picchila- Unctuous
		Muhu- Frequent

Sashopha akshipaka is caused due to the vitiation of tridoshas and rakta. It is characterized by swelling, severe pain, burning sensation and spitting. Shukla mandala appears red like that of a ripe 'fig fruit'. There will be frequent discharge, which is either hot or cold, clear or unctuous, thin or thick.

Ashopha Akshipāka

It is a Tridoshaja Vyadhana Sādya Vyādhi.

शोफहीनानि लिङ्गानि नेत्रपाके त्वशोफजे । (S.U.6/23)

Shopha heenani- Absence of shopha Lingani- Symptoms

Ashopha akshi paka is a disease caused due to tridoshas. It is characterized by all the symptoms of sashopha akshipāka, but there will be absence of shopha (swelling).

Alpa shopha (According to Vagbhata)

अल्पशोफोऽल्पशोफस्तु पाकोऽन्यैर्लक्षणैस्तथा ।। (A.H.U.15/19)

Alpa shophe- Mild Swelling.

Pako anya lakshana- Other symptoms of sashopha akshi paka.

Mild swelling along with all the other features of Sashopha akshipāka is known as Alpa shopha.

Chikitsa of Sashopha and Ashopha Akshipaka

Treatment of both Sashopha and Ashopha Akshipāka is similar to Raktaja Abhisandha Chikitsa.

27 S.T.-I

According to Vagbhata (A.H. U.16/31,32.)

- Snehana, swedana followed with Sirāvyadha.
- Then Snehana followed by Virechana with trivrit ghrita, draksha and haritaki kashāya.
- Seka: Shweta lodhra fried in ghrita is powdered and tied in cloth. It is then triturated with warm water and used for seka (Shulahara).
- Aschotana: Kashāya of dāruharidra, prapaundarika or stridugdha.
- Sandhava kalpanas : indicated when there is foreign body sensation, redness, excessive lacrimation and pain.
- a) Tāmra triturated in loha patra with gomutra is used for dhoopana along with ghrita (Vedanāhara).
- b) Pippali and saindhava triturated with dadhi sara in tāmra patra is used for lepa.
- c) Shanka bhasma and stri dugdha triturated in tāmra patra is used for dhoopana along with shami patra applied with ghrita (very soon reduces pain & foreign body sensation).

PILLA ROGA

उत्कलिष्टः कफपित्तान्नचयोत्याः कुक्कुणकः । पक्ष्मोपरोधः शुष्काक्षिपाकः पूयालसो बिसः ।
पोथकी अम्लोषितो अल्पाख्यः स्यन्दमन्या विना अनिलात् । एते अष्टादश पिल्लाख्या दीर्घकालानुबन्धिनः ।
(A.H.U.16/44-45)

Following 18 diseases are considered as Pilla rogas as they are dirghanukala bandha (persist for long time).

- 1-4. Utklishta (kaphaja, pittaja, raktaja and sannipataja)
5. Kukūnaka
6. Pakshmóparodha
7. Shuṣhkākshipāka
8. Puyālasa
9. Bisāvartma
10. Póthaki
11. Amlóshita
12. Alpākhyā (Alpa shophā)
- 13-15. Abhishyanda (pittaja, kaphaja and raktaja)
- 16-18. Adhimantha (pittaja, kaphaja and raktaja)

Chikitsa

चिकित्सा पृथक् एतेषां स्वस्वमुक्ता अथ वक्ष्यते ॥

पिल्ली भूतेषु सामान्यात् अथ पिल्लाख्य रोगिणः । सिग्धस्य छर्दितवतः सिराव्यथहतासृजः ॥
विरक्तस्य च वर्तमानि निर्लिखेत् अविशुद्धितः । (A.H.U.16/46-47)

The chikitsa for above mentioned 18 diseases are already described. When they attain chronicity and become pillakhyā rogas, the general line of treatment to be adopted are as follows:

1. Snehana, swedana.
2. Followed by Vamana, Sirāvyadha and Virechana.
3. After the above Shodhana karmas, patient is subjected to Lekhana karma to remove the doshas.
4. Seka is done with the extract obtained by tricturating 1 pala tuttha, 20 seeds of maricha and 30 palā kanji and stored in copper vessel.
5. Anjana with Rasakriya prepared by boiling the kashāya of karanjabeeja, tulasi and buds of jasmine is helpful in pilla roga.
6. Application of paste of tagara triturated with kashāya of abhaya is pilla nāshaka.
7. In pillaroga, patient has to repeatedly undergo lekhanā, raktamokshana and virechana. And should daily follow aschotana, anjana, nāvana nasya and dhūmapāna.

SIRÓTPATA

(Allergic Conjunctivitis/Episcleritis)

It is a Raktaja Vyadhana Sādhya Vyādhi.

अवेदना वाऽपि सवेदना वा यस्याक्षिराज्यो हि भवन्ति ताम्राः ।

मुहुर्विरज्यन्ति च ताः समन्ताद् व्याधिः सिरोत्पात इति प्रदिष्टः ॥ (S.U.7/29)

Avedana- Without pain Sa vedana- With pain

Akshi rajyo hi bhavanti tamraha- Appearance of coppery red streaks in eyes

Muhu- Again Virājyanti- Turns to normalcy Samntat- From all sides.

Sirotpāta is a condition wherein the siras of netra becomes coppery red in colour and after sometime the coppery red colour of siras disappears and attains normalcy. This occurs repeatedly and may or may not be associated with pain.

Chikitsa

Sirotpāta should be treated similar to Raktaja Abhishyanda

Specific Anjanas in Sirótpāta

- Ghrita with madhu
- Saindava, kaseesa with stanya
- Shankha, manashila, tuttha, daruharidra, saindava with honey
- Shirisha pushpa swarasa, sura, maricha with honey
- Gairika with honey

SIRĀHARSHA/SIRAPRAHARSHA
(Advanced stage of Episcleritis/Acute orbital cellulitis)

It is a Raktaja Vyadhana Sādhyā Vyādhi.

मोहात् सिरोत्पात उपेक्षितस्तु जायेत रोगस्तु सिराप्रहर्षः ।

ताम्राच्छमस्रं स्रवति प्रगाढं तथा न शक्नोत्यभिवीक्षितुं च ॥ (S.U.7/30)

Mohat sirotpata upekshitastu- If sirotpata is neglected Jayato- Produces

Roga- Disease Tāmra- Copper

Accha- Clear

Asra sravati pragadham- Thick bloody discharge

Na shaknoti abhi bhikshitum- Unable to see anything.

If sirotpāta is neglected, it leads to a more severe condition called sirapraharsha. In this, there will be coppery or clear, thick, bloody discharge and loss of vision.

Chikitsa

Sira harsha should be treated similar to Raktaja Abhishyanda.

Specific Anjanas in Sirāharsha

- Phānita with madhu
- Rasanjana with honey
- Kaseesa, saindava with honey
- Vaitraamla (Amlavetasa), Stanya, phanita with saindava

Chapter**7C**

- Anatomy of Conjunctiva
- Conjunctivitis- Its Classification
- Ophthalmia Neonatorum
- Glaucoma
- Diagnostic tests for Glaucoma
- Medical and Surgical treatment of Glaucoma
- Tear film
- Dry Eye

ANATOMY OF CONJUNCTIVA

The conjunctiva is a transparent, mucous membrane which covers the inner surface of the eyelids and the anterior surface of the eyeball as far as the limbus. It is richly vascular, supplied by anterior ciliary and palpebral arteries comprised of many small blood vessels. The tiny secretory glands in the conjunctiva produce tear film that lubricates and protects the eye.

Parts of Conjunctiva

Conjunctiva can be divided into following parts

1) **Palpebral Conjunctiva:** It lines the under-surface of the eyelids and can be subdivided into-

- a) Marginal conjunctiva- It is a transitional zone between skin and conjunctiva proper.
- b) Tarsal conjunctiva- It is adherent to the tarsal plate in the upper and lower lid.
- c) Orbital part- It lies loose between the tarsal plate and fornix.

2) **Bulbar Conjunctiva**

It is thin, transparent which covers the anterior sclera and is continuous with corneal epithelium at limbus.

3) **Conjunctival Fornix:** It forms the junction between the eyelid and eyeball i.e. bulbar conjunctiva joins the palpebral conjunctiva. It can be subdivided into superior, inferior, lateral and medial fornices.

Glands of Conjunctiva

- 1) **Mucin secretory glands-** Globlet cells, glands of Manz, crypts of Henle.
- 2) **Accessory lacrimal glands-** Glands of Krause and glands of Wolfring.

Nerve Supply

It is supplied by branches from long ciliary, lacrimal, infratrochlear, supratrochlear, supraorbital and frontal nerves.

CONJUNCTIVITIS

Conjunctivitis is an inflammation of the conjunctiva. It is commonly due to an infection or an allergic reaction.

Conjunctivitis may be caused due to the following factors:

1. **Exogenous:** In this, the causative agents are introduced in the conjunctival sac from outside. These agents may be microorganisms, foreign bodies or chemicals.
2. **Endogenous:** In this method, there may be blood-borne infection or there may be allergic response or there may be conjunctival affection as a result of general metabolic disturbance as in gout.
3. **By local spread of lesion from the surrounding structures** like skin, lacrimal apparatus, cornea, sclera, uveal tract or orbit.

Classification of Conjunctivitis

1. Infective conjunctivitis:

- a. **Bacterial conjunctivitis:** Acute bacterial conjunctivitis, chronic bacterial conjunctivitis, angular conjunctivitis.
- b. **Viral conjunctivitis:** Adeno virus conjunctivitis, entero virus conjunctivitis, molluscum contagiosum conjunctivitis, herpes simplex conjunctivitis.
- c. **Chlamydial conjunctivitis:** Trachoma, adult inclusion conjunctivitis, neonatal chlamydial conjunctivitis.
- d. **Ophthalmia neonatorum**
- e. **Granulomatous conjunctivitis :** Parinaud's conjunctivitis.

2. Allergic conjunctivitis

- a. **Simple allergic conjunctivitis-** Hay fever conjunctivitis, seasonal allergic conjunctivitis, perennial allergic conjunctivitis.
- b. **Vernal-kerato conjunctivitis**
- c. **Atopic kerato conjunctivitis**
- d. **Giant papillary conjunctivitis**
- e. **Phlyctenular conjunctivitis**
- f. **Contact dermo conjunctivitis**

3. Cicatricial conjunctivitis

4. Toxic conjunctivitis

Infective Conjunctivitis

In spite of the natural protective mechanism of the conjunctiva in the form of low temperature due to exposure to the air, presence of enzyme in the tears called lysozyme which has a definite anti-bacterial property and the mechanical action of blinking and flushing action of the lacrimal secretion, the conjunctival sac may be infected with pathogenic organism causing infective conjunctivitis.

Acute bacterial conjunctivitis

It is common and usually self limiting condition caused by direct eye contact with infected secretions. It is also called as acute mucopurulent conjunctivitis as it is characterized by mucopurulent discharge. The most common causative organisms are staphylococcus aureus, streptococcus pneumonia, haemophilus influenza and moraxella catarrhalis.

Symptoms

Redness, foreign body and burning sensation, discharge, mild photophobia, slight blurring of vision and sticking of the lid margins.

Signs

- Flakes of mucus seen in the fornices, canthi and lid margins is an important sign.
- Conjunctival congestion
- Chemosis

- Petechial haemorrhages.
- Cilia usually matted together with yellow crusts.

Differential diagnosis

- From other causes of acute red eye.
- From other types of conjunctivitis.

Treatment

- About 60% of cases resolve within five days without treatment.
- Topical and systemic antibiotics.
- Anti inflammatory and analgesic drugs.
- Irrigation of conjunctival sac.
- Wearing of dark glasses.

Viral conjunctivitis

Several viruses can cause conjunctivitis. The conjunctival reactions to the virus infection may be variable. Chiefly they are as follows:

- Inflammation with follicle formation in the conjunctiva is follicular conjunctivitis. This is the commonest reaction.
- Conjunctivitis with oedema of the conjunctiva and minimal conjunctival discharge but copious lacrimation and big patches of sub-conjunctival haemorrhages are seen in epidemic varieties.
- Hyperemia of the conjunctiva.
- Formation of conjunctival ulcers or membrane.

In case of viral conjunctivitis, there is always a tendency for cornea to be affected. The typical viral lesion is kerato-conjunctivitis.

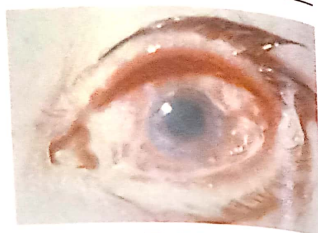

Fig. 7.1

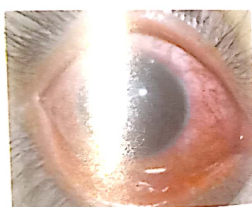

Fig. 7.2

Clinical presentations

Acute Viral conjunctivitis may present in two forms:

- Acute follicular conjunctivitis:** It is an acute catarrhal conjunctivitis associated with marked follicular hyperplasia especially of the lower fornix and lower palpebral conjunctiva.
- Acute haemorrhagic conjunctivitis:** It is an acute inflammation of conjunctiva characterized by multiple conjunctival haemorrhages, conjunctival hyperaemia and mild follicular hyperplasia.

Treatment

- Supportive treatment is usually given.
- Antiviral drugs are ineffective.
- Promising results are reported with adenine arabinoside (Ara-A).
- Corticosteroids should not be used in active stage.

Ophthalmia Neonatorum

Definition: It is bilateral conjunctival inflammation of the newborn within the first month of life.

Causative organisms: Gonococcus, streptococcus haemolyticus, staphylococcus aureus, streptococcus pneumonia.

Mode of infection

Eye may be infected in three ways:

- Before birth-** Through infected liquor amnii.
- During birth-** This is the commonest due to infected birth canal and if child is born with face presentation.
- After birth-** From soiled clothes, first bath of new born or fingers with infected lochia.

Signs and symptoms

- Pain and tenderness in the eye ball
- Conjunctival discharge: Purulent in gonococcal ophthalmia neonatorum and mucoid or mucopurulent in other bacterial and neonatal inclusion conjunctivitis.

- c. Lids are usually swollen.
- d. Conjunctival may show hyperemia and chemosis.
- e. Corneal involvement, though rare may occur in herpes simplex.

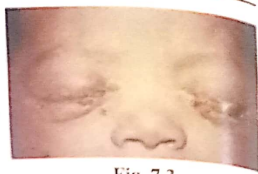

Fig. 7.3

Diagnostic criteria

- a. Purulent conjunctivitis in the newborn
- b. Conjunctival smear shows gonococcus

Treatment

1. **Prophylaxis**- Needs antenatal, natal and postnatal care.
 - a. **Antenatal measures**- Thorough care of mother and treatment of genital infection when suspected.
 - b. **Natal measures**-
 - Deliveries should be conducted under hygienic condition taking all aseptic measures.
 - The new born baby's closed lids should be thoroughly cleansed.
 - c. **Postnatal measures**- Use of either 1% tetracycline ointment or 0.5% erythromycin ointment or 1% silver nitrate solution into the eyes of the babies immediately after birth.
2. Antibiotics are given to infants born to mothers with untreated gonococcal infection.

ALLERGIC CONJUNCTIVITIS

It is inflammation of the conjunctiva due to allergic reactions.

Simple allergic conjunctivitis

It is a mild, non-specific allergic conjunctivitis.

Etiology

- Exogenous allergens: Pollens, vegetables, animal dusts and drugs like penicillin, atropine and pilocarpine.

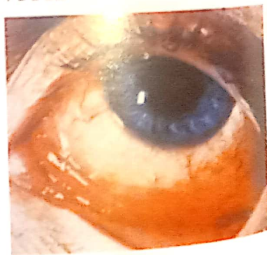

Fig. 7.4

- Endogenous allergens: Bacterial products from a septic focus particularly due to staphylococcus.

Symptoms

- Itching and burning sensation of the eyes.
- Photophobia and watering.

Signs

- Marked hyperaemia of conjunctiva.
- Chemosis of conjunctiva.
- Conjunctival discharge is scanty and watery but not muco-purulent.
- Eosinophils in conjunctival smear is noted.
- Oedema of the lids.

Treatment

- Elimination of allergens if possible.
- Local palliative measures which provide immediate relief include:
 - a) Vasoconstrictors like adrenaline, ephedrine and naphazoline.
 - b) Sodium chromoglycate drops in preventing recurrent atopic cases.
 - c) Avoid steroid eye drops.
- Systemic anti histamine drugs are useful in acute cases with marked itching.
- Desensitization has been tried without much rewarding results.

Vernal Keratoconjunctivitis (VKC) Or Spring Catarrh

It is a recurrent, bilateral, self limiting disorder in which both IgE and cell mediated immune mechanisms play important roles.

Etiology

- Age: 4-20 yrs; More common in boys than girls.
- Season: More common in summer.
- Exiting factor: Dust

Symptoms

- Marked itching and burning sensation.
- Mild photophobia, lacrimation, ropy discharge and heaviness of the lids.

Signs

- **Palpebral form-** Upper tarsal conjunctiva of both eye is involved. Lesion is characterized by the presence of hard, flat topped papillae arranged in a cobble stone fashion.
- **Bulbar form** is characterized by dusky, red triangular congestion of bulbar conjunctiva in palpebral area. Gelatinous, thickened accumulation of tissues around the limbus and presence of tranta's spots (whitish raised dots) along the limbus.
- **Mixed form** shows the combined features of the above.

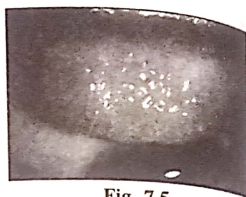

Fig. 7.5

Treatment**General measures**

- Allergen avoidance
- Cool compresses
- Lid hygiene
- Dark goggles to prevent photophobia

Local treatment

- Mast cell stabilizers
- Antihistamines and antibiotics
- Mucolytic agent- Acetyl cysteine (0.5%)
- Steroids

Systemic treatment

- Oral anti histamines and antibiotics
- Immunosuppressive agents

Surgical treatment

Superficial keratectomy is indicated in case of large vernal plaque.

Atopic kerato conjunctivitis

It is a rare bilateral disease that typically develops in adulthood following a long history of eczema. Asthma is also extremely common in these patients. Symptoms are similar to those in vernal keratoconjunctivitis but are frequently more severe and unremitting.




Fig. 7.6

Treatment

Similar to vernal keratoconjunctivitis.

Giant papillary Conjunctivitis

It is the inflammation of conjunctiva with formation of very large sized papillae seen more frequently in contact lens wearers.

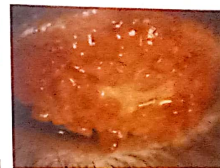

Fig. 7.7

Symptoms

Foreign body sensation, redness, itching, increased mucous production, blurring and contact lens intolerance.

Signs

Mucous discharge, papillary hypertrophy of the upper tarsal conjunctiva associated with hyperemia.

Treatment

- Remove the stimulus such as wearing of contact lens.
- Anti-histamines, non steroidal anti-inflammatory drugs.
- Disodium cromoglycate relieves the symptoms.

Phlyctenular Conjunctivitis

It is an allergic inflammatory reaction of the conjunctiva to some endogenous toxin which is bacterial in origin.

Etiology

- Age : usually 3 to 15 years of age.
- Unhygienic conditions
- Undernourished children.
- Exciting factor: Usually tubercular toxin, but toxins from other organisms like staphylococcus may also be responsible for the disease.

Symptoms

- Discomfort in the eye.
- Irritation and reflex watering
- Photophobia

Signs

- The phlycten which means a bleb appears as a pinkish white nodule varying from 1 to 3 mm in size usually at the limbus.
- It may be one or many in number.
- Phlycten may also appear on the bulbar conjunctiva.
- In case of secondary infection, the whole of the conjunctiva becomes congested and mucopurulent discharge develops.

Treatment:

- Local therapy- Topical steroids, antibiotic drops, atropine 1% eye ointment.
- Specific therapy-Eradicate the causative conditions like tubercular infection etc.
- General measures- High protein diet supplemented with vitamin A, C and D.

Toxic conjunctivitis

It is an irritative, follicular response which occurs after prolonged administration of topical medication.

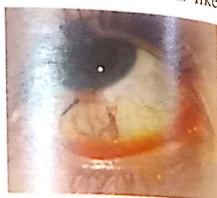

Fig. 7.8

GLAUCOMA

Aqueous outflow

Aqueous flows from the posterior chamber via the pupil into the anterior chamber, from where it exits the eye by two different routes.

1. **Trabecular (conventional) route** : It accounts for approximately 90% of aqueous out flow. The aqueous flows through the trabeculum into the schlemm's canal and is then drained by the episcleral veins.
2. **Uveoscleral (unconventional) route** : It accounts for the remaining 10% in which aqueous passes across the face of the ciliary body into the suprachoroidal space and is drained by the venous circulation in the ciliary body, choroid and sclera.

Factors which cause rise in Intra ocular pressure are :

1. An increase in the volume of the intra-ocular contents-

- a. Increase in quantity of the aqueous humour due to an increase in the rate of aqueous production or due to a decrease in the rate of outflow of the fluid as a result of obstruction in its drainage.
- b. Increase in the blood volume due to an increased arterial and capillary volume or due to a decrease in venous outflow
- c. Increase in the volume of the lens and the vitreous.

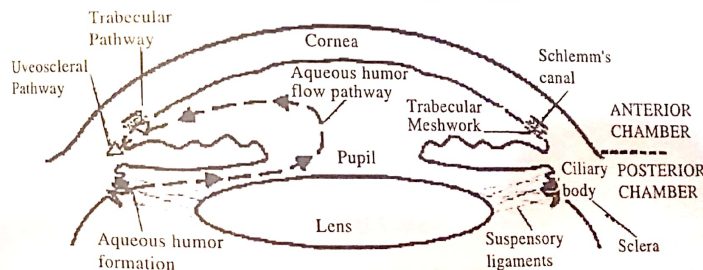


Fig. 7.9

2. External pressure upon the globe.

Definition of Glaucoma: It is a condition in which a group of ocular disorders characterized by progressive optic neuropathy resulting in a characteristic appearance of the optic disc and a specific pattern of irreversible visual field defects. It is associated frequently, but not invariably with raised intra-ocular pressure. (normal IOP is 11 to 21 mm of Hg by Schiotz tonometer).

Development of Glaucoma

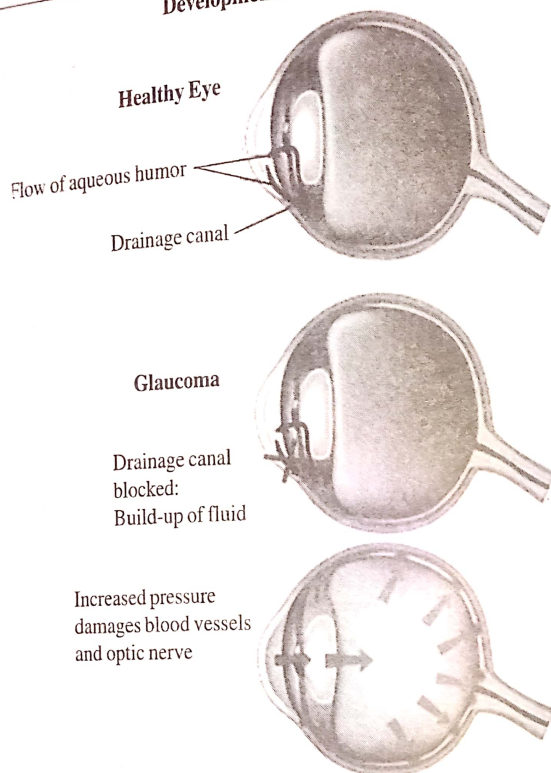
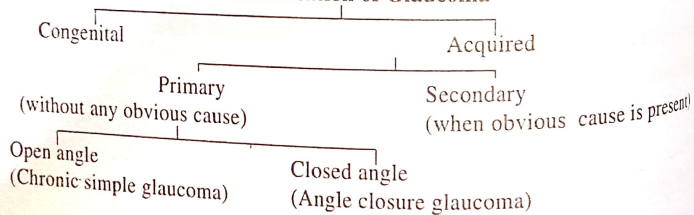


Fig. 7.10

Classification of Glaucoma



Congenital glaucoma

It refers to abnormally high IOP which results due to developmental anomaly of the angle of the anterior chamber.

Primary Open Angle Glaucoma (Chronic simple glaucoma)

It is a type of primary glaucoma, where there is no obvious cause for the rise of intraocular pressure and angle of the anterior chamber remains wide. It is characterized by-

- Slowly progressive, raised intraocular pressure.
- An open anterior chamber angle.
- Characteristic optic disc cupping.
- Specific visual field defects.

Symptoms

1. Onset is very insidious and usually asymptomatic.
2. Mild headache and eye ache may occur.
3. Presbyopic glasses may require frequent changes due to accommodative weakness.
4. Defect in field of vision.
5. Gradual dimness of central vision is noted at central stage.
6. In later stages there may be night blindness due to peripheral field defect and loss of function of peripheral parts of retina.

Signs

1. **Anterior segment:** At later stage pupil, reflex becomes slightly sluggish and cornea becomes slightly hazy.
2. **Rise in intraocular pressure:** There will be an exaggeration of normal diurnal variation. In most patients IOP (Intra ocular pressure) falls during evening. A variation in IOP over 8 mm Hg (schiotz) is diagnostic of glaucoma.
3. **Ophthalmoscopic examination reveals**
 - a. Pale optic disc

b. Cupping of the optic disc (Cupping means excavation of the disc).

c. Pulsation of the retinal arteries at the margin of the disc.

4. Defects in the field of vision

It is known that in chronic simple glaucoma, there is damage of nerve fibre and so the field defects are clinically manifested according to the nerve fibre bundles affected. In advanced stage of glaucoma, the peripheral field defect gradually extends all around the periphery, until only a central tubular field remains. Finally in absolute stage, the central field is also abolished and the eye becomes blind.

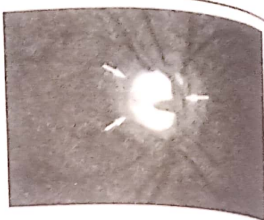


Fig. 7.11

Diagnostic tests for chronic simple Glaucoma

1. **Tonometry** : Schiottz or applanation tonometry is used to measure IOP
2. **Central corneal thickness measurement (CCT)**: To know the corneal thickness
3. **Diurnal variation test** : Repeated observation of IOP for 24 hours.
4. **Gonioscopy**: A method of evaluating the anterior chamber angle to provide information regarding the type of glaucoma.
5. **Documentation of optic disc changes**
6. **Slit lamp examination of anterior segment**: To rule out causes of secondary open angle glaucoma.
7. **Perimetry**: To detect visual field defects.
8. **Nerve fibre layer analyser (NFLA)**: To detect the glaucomatous damage to the retinal nerve fibres.
9. **Water drinking test** : It is a provocative test required in border line cases. In it, after an 8 hours fast, baseline IOP is noted and the patient is asked to drink 1 litre of water, following which IOP is noted every 15 minutes for 1 hour. The maximum rise in IOP occurs in 15- 30 minutes and returns to baseline level after 60 minutes in both normal and glaucomatous eye. A rise in IOP by 8mm Hg or more is diagnostic of POAG (Primary Open Angle Glaucoma).

Diagnostic criteria of chronic simple glaucoma

1. Elderly person complaining of gradual dimness of vision.
2. Raised intraocular pressure.
3. Field defects.
4. Cupping of optic disc.
5. External appearance of the eye will be normal.

Differential diagnosis :

1. **Immature cataract**: IOP will be normal and no cupping of the disc.
2. **Optic atrophy**: Though optic disc is pale, there will be no glaucomatous cupping and IOP will be normal.

Treatment

As soon as diagnosis of glaucoma is made, the treatment should be started. The aim of the treatment is to lower intraocular pressure to a level where further visual loss does not occur. This can be achieved by:

1. Medical therapy

- Topical beta blockers lower the IOP by reducing aqueous production. Eg. Timolol maleate (0.25, 0.5%; 1 to 2times/day), Betaxolol (0.25%; 2 times/day).
- Prostaglandin analogues decrease the IOP by increasing the outflow of aqueous. Eg. latanoprost (0.005%), travoprost (0.004%).
- Adrenergic drugs like epinephrine hydrochloride (0.5% to 2%; 1-2 times/day) and brimonidine (0.2%; 2 times a day) lowers IOP by increasing aqueous outflow and decreasing aqueous production respectively.
- Pilocarpine (1, 2, 4%; 3- 4 times/day) dilates blood vessels and in this way helps absorption of aqueous humor and lowers intraocular pressure.

2. **Laser trabeculoplasty**: This can be done by using argon laser or diode laser. It should be considered in patients where IOP is uncontrolled despite medical therapy.

3. **Surgical therapy**: Trabeculectomy is the most frequently performed surgery. It is a filtration surgery which provides a new channel for aqueous outflow and successively controls the IOP (below 21 mm Hg).

Pseudo glaucoma or low tension glaucoma- It is a condition which is not glaucoma in the true sense. There will be cupping of the disc and visual field changes similar those in chronic simple glaucoma, the angle of anterior chamber is also wide. But the intraocular pressure remains normal or subnormal.

Primary Angle Closure Glaucoma (PACG)

This is a condition in which the intraocular pressure is raised as a result of obstruction to the outflow of the aqueous due to extreme narrowness or closure of the angle of the anterior chamber consequent upon the close proximity of iris to the cornea in the absence of any other ocular or systemic disease.

Etiology

- It is common in women than in men and affects frequently at 6th and 7th decades of life.
- Type of individual- Highly nervous individual with unstable vasomotor system.
- Type of eye affected.
- a. Usually hypermetropic eye (small eye) with shallow anterior chamber.
- b. Eyes in which iris- lens diaphragm is placed anteriorly.
- c. Eyes with a narrow angle.
- d. Heredity.
- e. Seasonal incidence: More in rainy season due to diminished light.

Mechanism of closure of narrow angle

It varies and is commonly due to the following factors.

1. **Dilatation of the pupil:** On dilatation of pupil, the iris collects at the angle and so closes the already narrow angle. Thus it is dangerous to put atropine in the eye of an elderly person with a shallow anterior chamber.
2. **A swelling or anterior displacement of the ciliary body** due to congestion and oedema of the ciliary body.
3. **Relative pupillary block-** Any cause that dilates the pupil like darkness, anxiety or mydriatic drugs leads to build up of aqueous in posterior chamber. This is called as physiological 'iris bombe'. This ballooning of the peripheral iris closes the already narrow angle.

Classification and clinical presentation of PACG

PACG can be understood and managed in three stages-

- i. Latent primary angle closure glaucoma.
- ii. Subacute or intermittent and acute primary angle closure glaucoma.
- iii. Chronic primary angle closure glaucoma.

1. Latent primary angle closure glaucoma (Primary angle closure suspect).

- Symptoms are absent in this stage.
- **Eclipse sign-** To elicit decreased axial anterior chamber depth. This can be done by throwing light across the anterior chamber through a pen light from the temporal side and noting the shadow on the nasal side.
- Slit lamp examination reveals decreased anterior axial and anterior chamber depth, convex shaped iris, lens, diaphragm and close proximity of iris to the cornea in the periphery.

Treatment: Prophylactic laser iridotomy

2. Subacute or intermittent & acute primary angle closure glaucoma.

- **Symptoms**
In subacute cases- Unilateral transient blurring of vision, coloured haloes, headache, brow ache and eye ache.
In acute cases- Pain, nausea, vomiting, progressive impairment of vision, redness, photophobia and lacrimation.
- **Signs**
 - a. Lids- Oedematous.
 - b. Conjunctiva- Chemosed and congested.
 - c. Cornea- Oedematous and insensitive.
 - d. Anterior chamber- Very shallow.
 - e. Angle of anterior chamber completely closed.
 - f. Iris- discoloured.
 - g. Pupil- Semi-dilated, non-reactive to both light and accommodation.
 - h. IOP- Elevated (between 40 and 70mmHg).
 - i. Optic disc- Oedematous and hyperaemic.

Management : It is a serious ocular emergency condition and needs to be managed as below.

1. Immediate medical therapy to lower IOP.
 2. Definitive treatment like laser peripheral iridotomy (PI), laser iridotomy or filtration surgery.
 3. Prophylaxis of the fellow eye- prophylactic laser iridotomy or surgical peripheral iridectomy should be performed on asymptomatic eye.
3. Chronic primary angle closure glaucoma

Clinical features

- IOP- Constantly raised
- Eyeball- Painless without congestion
- Optic disc- Glaucomatous cupping
- Visual field defects- Similar to POAG
- Gonioscopy reveals more than 270° of angle closure along with peripheral anterior synechiae.

Treatment

1. Medical therapy similar to POAG
2. Laser iridotomy
3. Trabeculectomy
4. Prophylactic laser iridotomy in the fellow eye.

TEAR FILM

Tear film consists of three layers, which from posterior to anterior are:

- I. **Mucus layer-** It consists of mucin, secreted by conjunctival goblet cells and glands of Manz. It helps in lubrication and in converting hydrophobic corneal epithelium into hydrophilic one.
- II. **Aqueous layer-** It is secreted by main and accessory lacrimal glands. The tears mainly comprise of water, electrolytes, dissolved mucins and proteins. It also contains antibacterial substances like lysozyme and lactoferrin.
- III. **Lipid layer-** It is the outermost layer of the tear film, formed from the secretions

of meibomian, zeis and moll glands. It prevents evaporation of the aqueous layer, maintains tear film thickness and lubricates the eye lids as they slide over the surface of the globe.

DRY EYE

Definition

A disorder of the tear film due to tear deficiency or excessive evaporation, which causes damage to the interpalpebral ocular surface and is associated with symptoms of ocular discomfort.

Clinical features

Symptoms

Dryness, foreign body sensation, itching and burning sensation that characteristically worsens during the day.

Signs

- Posterior blepharitis and meibomian gland dysfunction may be present.
- Conjunctiva shows mild keratinization and redness.
- Tear film- May show stringy mucous and particulate matter. Marginal tear strip is reduced or absent (normal height is 1mm).
- Cornea-Punctate epithelium erosions, filaments and mucous plaques. Cornea may lose luster.
- Signs of the causative disease such as Trachoma, Stevens Johnson syndrome, Lagophthalmos etc.

Investigations

The aim of the investigation is to quantify the diagnosis of dry eye.

The tests measure the following parameters.

- T-BUT (Tear Break Up Time)- For testing stability of tear.
- Schirmer, fluorescein clearance and tear osmolality- For knowing tear production.
- Rose Bengal staining- For detecting even mild cases of KCS (Kerato Conjunctivitis Sicca).

Treatment

Dry eye is not curable. The following treatment modalities is being advised.

- Patient should be educated against exposure to causative factors such as dry environment or toxic drugs etc.
- Tear substitutes- Cellulose derivatives, carbomers, polyvinyl alcohol, petrolatum mineral oil in the form of drops, gels and ointments.
- Mucolytics- Such as acetylcysteine 5% drops.
- Punctual occlusion-To reduce drainage and preserve natural tears.
- Treatment of causative disease such as lagophthalmos, posterior blepharitis etc.

Review Questions

1. What is Adhimantha? Describe its types and management.
2. Classify Sarvākshi rogas as per Sushruta and Vagbhata.
3. Write about the importance of Abhishyanda.
4. Write the Sādhyā asādhyā of Adhimantha.
5. Write Sāmānya chikitsa of Abhishyanda and Adhimantha.
6. Explain lakshana of Amladhyushita with its treatment?
7. Describe Ashopha and Sashopha Akshipaka with its treatment.
8. Describe Hathādimantha and its prognosis.
9. Mention the diseases mentioned under Pilla roga.
10. Differentiate Vātaparyaya and Anyatōvata.
11. What is Shushkākshipāka? How do you manage it?
12. Name some Anjana yogas used in the management of Sirōtpāta and sirāharsha.
13. Write a note on "tear film"
14. Classify Glaucoma
15. Describe the mechanism of aqueous outflow.

Research updates

1. Role of Triphala grita tarpana in the management of Shushkākshipāka with special reference to Dry eye syndrome. Dr. Gangadhar. GAMC. RGHS Bangalore. 2007.
2. A Comparative study on the efficacy of Shadanga Guggulu Kwatha and Jaloukavacharana in the management of Adhimantha."Dr. Sukumar. GAMC. RGHS Bangalore. 2014.

Scope for research

1. Critically analyse the different types of Abhishyanda with types of Conjunctivitis.
2. Effect of Jeevaneeya dravya siddha gritha- Pana and tarpana in the management of Shushkākshipāka.

Chapter-8

DRUSHTIGATA ROGA

(VISION DISORDERS)

- A. Number of Drushtigata rogas detailed knowledge of-etiology, pathology, clinical features, differential diagnosis and management of Timira, Kācha and Linga nāsha.
- B. Brief Knowledge of Abhighataja lingnasha, sanimittaja & Animittaja Linganaśha, Doshandhya/Kaphavidagdha drushti, Naktandhya, Ushna vidagdha drushti, Pittavidagdha drushti, Dhūmadarshi, Hriswajādyā, Gambhirika, Nakulandhya, Nayanabhighāta.
- C. Knowledge of Refractive errors, Cataract including their etiology, pathology, clinical features, differential diagnosis, complications and their management.
- D. Study of Eale's disease, Hypertensive & Diabetic Retinopathies, Age related Macular degeneration, Strabismus, Retinitis pigmentosa, Night blindness, Amblyopia, Central serous retinopathy, Optic Neuritis and Optic atrophy.

Chapter

8A

- Features of Drushti
- Classification of Drushtigata Roga
- Timira/Kācha and Linganaśha- Lakshana and Chikitsa
- Prathama, Dwitīya, Triteeya and Chaturtha Patala gatha dosha, lakshana
- Samānya and Sannipātaja Timira, Kācha, Linganaśha
- Parimlāyi
- Sādhyaśadyata of Drushtigata Roga
- Samānya chikitsa for Timira
- Shastrakarma for Kaphaja Linganaśha

DRUSHTIGATA ROGAS

'Drushti' is the functional unit which does the actual perception of vision.

Panchabhutas and doshas of Drushti mandala

Drushti is panchabhoutika in nature with predominance of tejo mahabhuta and has presence of all the tridoshas.

Features of drushti

- मसूरदल मात्रां तु पञ्चभूत प्रसादजाम् । खद्योत विस्फुलिङ्गाभामिच्छां तेजोभिरव्ययैः ॥
आवृतां पटलेनाक्षयोः बाह्येन विवराकृतिम् । शीत सात्व्यां नृणां दृष्टिमाहुः नयनचिन्तकाः ॥ (S.U.7/3-4)
- Masura dala- Split of lentils Mātra- Size Panchabhuta- 5 bhutas
- Prasādajām- Essence Khadyota- Glow worm Visphu linga- Sparks of fire
- Aabham- Gleaming Idam- Like Tejohhir avyayaihi- Endless of teja
- Avratam- Covered by Patalena aksho- Layers of eye
- Bāhyena- Externally Vivarākritim- Porous appearance
- Sita-cold Sātmya- Beneficial

Nrunam- In human beings **Drushtimāhuhu-** Told as drishti

Nayanachintaka- Eye specialist

- Drushti is made up of prasādhāga of pancha mahabhuta with the predominance of tejomahābhuta.
- Size of drushti is similar to that of masura dala (split of lentil).
- Drushti is compared to light emitted by glow worm (sparks of light).
- Drushti is covered by the bāhya patala.
- For the transmission of light rays, there is an aperture (vivara) which can be correlated to pupil.
- Drushti is considered as sheeta sātmya though it is predominant with tejo mahābhuta.

Different opinions regarding Drushti

Based on the description of different Acharyas, there is controversy regarding the meaning of Drushti. It can be considered as **Pupil, Lens, Patala or Vision**.

a. Points to consider Drushti as 'Pupil'

- Drushti is the last and inner most part of the five mandalas. (S.U.1/15).
- The size of drushti mandala is mentioned as **masuradala** (split of lentil) **matra**. (S.U.7/3).
- Drushti mandala constricts in bright light and dilates in dim light. (S.U.7/31).
- Drushti mandala is $1/7^{\text{th}}$ or $1/9^{\text{th}}$ of the krishnamandala and is situated in its centre.

b. Points to consider Drushti as 'Lens'

- Diseases like timira, kācha and lingānāsha occurs in drushti mandala. These are caused due to the opacification of lens.

c. Points to consider Drushti as 'Patala'

- The four abhyantara patalas (tejojalāshrita to asthyāshrita) can be considered as 'Drushti' because while describing different stages of timira, kācha and lingānāsha, it is being mentioned that symptoms manifest depending on the involvement of different patalas. (S.U.7/5-17).

d. Points to consider Drushti as 'Vision'

Literally the meaning of 'Drushti' can be taken as 'Vision'.

CLASSIFICATION OF DRUSHTIGATA ROGA

इह लिङ्गनाशाः षड्विधे च रोगा दृष्ट्याख्याः षट् च षडेव च स्युः ।
तथा नरः पित्तविदग्धदृष्टिः कफेन चान्यस्त्वय धूमदग्धौ ॥
यो हृस्वमाड्यो (त्यो) नकुलान्धता च गम्भीरसंज्ञा च तथैव दृष्टिः ॥ (S.U.7/34-35)

Sushruta-12	Vāgbhata-27
1. Vātaja timira	1-6. Six types of timira
2. Pittaja timira	7-12. Six types of kācha
3. Kaphaja timira	13-18. Six types of lingānāsha
4. Raktaja timira	(vāta, pitta, kapha, rakta, dwandwa and sannipāta)
5. Sannipātaja timira	19. Pitta vidagdha drushti
6. Parimlāyi timira	20. Āmla vidagdha drushti
7. Pitta vidagdha drushti	21. Ushna vidagdha drushti
8. Kapha vidagdha drushti	22. Dōshāndhya
9. Dhooma darshi	23. Dhooma darshi
10. Hṛswajādhyā	24. Hṛswa jadhyā
11. Nakulāndhya	25. Nakulāndhya
12. Gambheerika	26. Gambheerika
	27. Aupasargika lingānāsha

In addition to these, Acharya Sushruta has mentioned Animittaja and Sanimittaja lingānāsha.

TIMIRA, KĀCHA AND LINGĀNĀSHA

'Timira' literally means *darkness*.

Timira, kācha and lingānāsha can be considered as progressive stages of a disease where there will be distorted vision which eventually ends up in complete loss of vision.

Stages	Sushruta	Vāgbhata	Modern
1. Timira	Vitiation of doshas in I, II and III patala (no rāgata).	Vitiation of doshas in I and II patalas.	Partial obstruction of vision
2. Kācha	Vitiation of doshas and pigmentation (rāgatha) in III patala	Vitiation of doshas and pigmentation (rāgatha) in III patala	Moderate obstruction of Vision
3. Līnganāsha	Vitiation of dosha in IV patala	Vitiation of dosha in IV patala	Complete obstruction of Vision

The clinical features of timira are dependent upon the site of lodging of vitiated doshas in the patala. (for eg. Vitiation of doshas in second patala means first patala and second patala are involved similarly involvement of fourth patala indicates vitiation of all the four patalas).

Prathama patalagata dosha lakshana

सिराभिरभिसम्प्राप्य विगुणोऽभ्यन्तरेभूषम् । प्रथमे पटले दोषो यस्य दृष्टौ व्यवस्थितः ॥
अव्यक्तानि स रूपाणि सर्वाण्येव प्रपश्यति ॥ (S.U.7/6-7)

Sirābhihi- Through the siras Abhi samprāpya- Spreads Viguno- Vitiated
Abhyantare- Within Bhrusham- Severe Dosha- Any dosha
Drushti's vyavasthitaha- Confined to drushti Avyaktani roopani- Blurred vision
Sarvanyeva- All the Prapashyati- Sees

In this condition, the vitiated doshas spreads within the siras and get confined to the prathama patala of the drushti causing blurriness of vision.

According to Vāgbhata

सिरानुसारिणि मले प्रथमं पटलं श्रिते । अव्यक्तमीक्षते रूपं व्यक्तमप्यनिमित्ततः ॥ (A.H.U.12/1)

Siraanusāri- Through blood vessels Male- Vātadi dosha
Prathamam- Bāhyam (tejojalashrita patala) Shrite- Localized
Avyaktam- Not visible Eekshate- Viewing Roopam- Objects
Vyaktam- Clearly Animittataha- Without any reason

The vitiated vatadi doshas gets localized in the first patala of the eye through their respective siras. In this condition the person will not be able to see the objects clearly but sometimes without any reason he starts viewing objects clearly.

Probable correlation: First stage of cataract/refractive errors like myopia.
Dwitiya patala gata dosha lakshana

दृष्टिर्भूषं विह्वलति द्वितीयं पटलं गते ॥
मक्षिका मशकान् केशाङ्गालकानि च पश्यति । मण्डलानि पताकांश्च मरीचीः कुण्डलानि च ॥
परिप्लावांश्च विविधान् वर्षमप्यत्र तमांसि च । दूरस्थान्यपि रूपाणि मन्यते च समीपतः ॥
समीपस्थानि दूरे च दृष्टेर्गोचरविभ्रमात् । यत्नवानपि चात्यर्थं सूचीपाशं न पश्यति ॥ (S.U.7/7-10)

Vihvalati- Distorted Makshika- Flies Mashaka- Mosquitoes
Késa- Hair Jālakani- web Pashyati- Visualizes
Mandalāni- Round objects Pataaka- Flags Marichi- Rays
Kundalāni- Ear rings Pariplava- Moving objects like star or meteors
Varsha- Rain Abhra- Clouds Tamamsi- Darkness
Doorasthaanyapi roopani- Far objects Sameepataha- Near
Drushti gochara vibhramat- Confusion in seeing the objects
Yatnavaanapi- On effort Suchi pasha- Hole of the needle.

When doshas gets localized in the second patala, the vision gets distorted and patient starts visualizing objects which are not present such as mosquitoes, hair, webs, rounded objects, flags, different types of rays, ear rings, moving objects like meteors or stars, rain, clouds and darkness. The real objects look unreal, far off objects appear nearer and near objects appear far. Like this there will be confusion in seeing the objects and one is unable to see the hole of a needle even after much effort.

According to Vāgbhata

प्राप्ते द्वितीयं पटलमभूतमपि पश्यति । भूतं तु यत्नादासन्नं दूरे सूक्ष्मं च नेक्षते ॥
दूरान्तिकस्थं रूपं च विपर्यसेन मन्यते । दोषे मण्डल संस्थाने मण्डलानीव पश्यति ॥
द्विधैकं दृष्टिमभ्यस्ये बहुधा बहुधा स्थिते । दृष्टेरभ्यन्तरगते ह्रस्ववृद्धविपर्ययम् ॥
गान्तिकस्थमद्यः संस्थे दूरमं नोपरि स्थिते । पार्श्वे पश्येन्नपार्श्वस्थे तिमिराख्योऽयमामयः ॥ (A.H.U.12/2-5)

Abhūtam- Non existant Pashyati- Sees Bhootam- Existing
Yatnad- With difficulty Aasannam- Near Doore- Far
Sookshmam- Small objects Nekshate- Cannot see
Doorantikastham roopam cha viparyasena manyate- Near objects appear far and vice versa.

Mandalaniva pashyati- Sees circular

Dvidhaikam drishti madhyasthe- If dosha is in centre of drushti, then one object is seen as double (diplopia).

Bahudha bahudhasthite- If dosha is in multiple areas of drushti, then one object is seen as many (polyopia).

Drushter abhyantara gate- When dosha is present inside drushti.

Hrisva vriddha viparyaym- Small is seen as large and vice versa.

Nantikastham adhah samsthe- When dosha is present in lower part, near objects cannot be seen.

Dooragam noparoi sthite- When dosha is present in upper part, distant objects cannot be seen.

Parshve pashyen na parshvasthe- When dosha is in the sides, peripheral objects cannot be seen.

If the doshas get localized in the second patala, existant and non existant objects are seen. Objects present near are seen only with effort and distant small objects cannot be seen. Distant objects are seen as near and vice versa.

Visual defects are also based on the localization of doshas-

- If the doshas localized in circular manner in the drushti- Objects appear circular.
- If the doshas are localized in the middle of the drushti-Single object is seen as double.
- If the doshas are localized in multiple areas of the drushti-Single object appear as many.
- If the doshas are localized inside the drushti- Small objects appear big and vice versa.
- If the doshas are localized in the lower part of the drushti- Near objects cannot be seen.
- If the doshas are localized in the upper part of drushti- Distant objects cannot be seen.
- If the doshas are localized in the sides of the drushti- Objects in the periphery cannot be seen.

The disease with above symptoms is called Timira.

Note : Dwithiya patalagata dosha lakshanas mentioned by Vagbhata is similar to Triteeya patalagata dosha lakshanas mentioned by Sushruta.

Probable correlation: Cataract/ Refractive errors/Vitreous Opacity

Triteeya patala gata dosha lakshana

ऊर्ध्वं पश्यति नाधस्तात्तृतीयं पटलं गते । महान्यपि च रूपाणि च्छादितानीव वाससा ॥
कर्णनासाक्षियुक्तानि विपरीतानि वीक्षते । यथादोषं च रज्येत दृष्टिर्दोषे बलीयसि ॥
अधःस्थिते समीपस्थं दूरस्थं चोपरिस्थिते । पार्श्वस्थिते तथा दोषे पार्श्वस्थानि न पश्यति ॥
समन्ततः स्थिते दोषे सङ्कुलानीव पश्यति । दृष्टिमध्यगते दोषे स एकं मन्यते द्विधा ॥
द्विधास्थिते त्रिधा पश्येद्बहुधा चानवस्थिते । तिमिराख्यः..... ॥ (S.U.7/11-14)

Urdhwam- Above **Pashyati Na adhaha-** Cannot see objects placed below

Triteyam patale gate- Localized in third patala

Mahaantyapi cha roopani- Also the big objects seen as

Chaaditaaniva vaasasa- Covered with cloth

Karna nasa akshi yuktani vipareetani veekshyate- Visualizes person without ear nose and eye **Yatha dosham-** As per dosha **Rajyeta-** Colour

Baliyasi- Aggrevate **Adhah sthite-** Situated in lower **Sameepastam-** Near

Dūrastam- Far **Cha uparisthite-** Situated upper

Parshwasthite- Situated in sides **Parshwasthani-** Side objects

Na pashyati- Not able to see **Samantatah sthithie-** Situated all around

Sankulaaneeva- Mixed **Pashyati-** Vision

Drushti madhyagathe- Doshas in centre of drushti

Ekamanyate dvidha- One object is seen as double

Dwidha sthite tridha- Two objects as triple vision

Cha anavasthite- If dosha is unstable **Pashyed-** Sees

Bahudha- Many objects **Timirakhyaha-** Called as Timira.

If the doshas get localized in the third patala,

- Objects placed above can be seen but, cannot see the objects placed below.

- Big objects are seen as though covered with cloth.
- Visualizes a person without ear, nose or eyes.
- The doshas gets aggravated and the colour of the drushti changes depending on the involved dosha.

Based on the localization of doshas the following features of drushti is seen-

- If the doshas are localized in the lower part of drushti- Near objects cannot be seen.
- If the doshas are localized in the upper part of drushti- Distant objects cannot be seen.
- If the doshas are localized in the sides of the drushti- Objects in the periphery cannot be seen.
- If the doshas are localized in all the sides of drushti- Mixed visualization (overlapping).
- If the doshas are localized in the centre of drushti- Single object is seen as double.
- If the doshas are localized in two places of drushti- Single object is seen as three.
- If the doshas are unstable- Many objects are seen.

The disease with the above symptoms is called as **Timira**.

According to Vāgbhata

प्राप्नोति काचतां दोषे तृतीयपटलाश्रिते । तेनोर्ध्वमीक्षते नाद्यस्तनुचैलावृतोपमम् ॥
यथा वर्णं च रज्येत दृष्टिर्हीयते च क्रमात् ॥ (A.H.U.12/6-7)

Prapnoti- Attains **Tena urdhwam ekshate na adhaha-** Visualizes above but not below

Tanu- Thin **Chaila-** Cloth **Avrutopama-** As if covered

Yatha varnam cha rajyeta- Drushti is coloured according to the dosha involved

Drishti heeyate- Visual capacity reduces

When doshas reach the third patala, drushti attains colour and this condition is called **Kācha**.

- The person cannot visualize the objects placed below and hence looks upwards.
- Objects are visualized as though covered by a thin cloth.
- The drushti attains its colour depending on the involved dosha.
- The visual capacity reduces depending on the intensity of vitiated doshas.

Probable correlation : This stage can be correlated to immature cataract.

Chaturtha patala gata dosha lakshana (Linganāsha)

'Linga' means Chakṣhuréndriya shakti-Visual capacity.

Linganāsha is loss of vision.

स वै दोषः चतुर्थं पटलं गतः ॥

रुणादि सर्वतो दृष्टिं लिङ्गनाशः स उच्यते । तस्मिन्नपि तमोभूते नातिरूढे महामदे ॥

चन्द्रादित्यौ सनक्षत्रावन्तरीक्षे च विद्युतः । निर्मलानि च तेजांसि भ्राजिष्णूनि च पश्यति ॥
स एव लिङ्गनाशस्तु नीलिकाकाचसंज्ञितः । (S.U.7/15-18)

Chaturtam patala gataha- Confines to fourth patala **Runaddhi-** Diminished

Sarvata drishtim- Complete vision loss **Sa uchayate-** Called as

Tasminnapi- When this **Tamobhute-** Darkness

Naatirudhe- If not so aggravated **Mahāgade-** Grave

Chandradityo- Moon and sun **Sanakshatra-** Star also

Vidyutah nirmalani cha tejamsi bhrajishnuni- Lightening, burning and glowing objects **Antarikshe-** Sky

Pashyati- See **Sa eva-** This is

When the doshas enter the fourth patala and obstructs the vision completely, it is called as 'Linganasha'. In this stage, one perceives only darkness. But if the condition is not so aggravated or grave, the patient can visualize moon, sun, star, sky, lightening, burning and glowing objects. Linganaasha is also called as **Nilika** or **Kācha**.

According to Vāgbhata (Linganāsha)

तथाऽप्युपेक्षमाणस्य चतुर्थं पटलं गतः । लिङ्गनाशं मलः कुर्वन् छादयेदृष्टिमण्डलम् ॥ (A.H.U. 12/7)

Tatha api- Even in this stage i.e. kacha **Upekshamaanasya-** If ignored

Linganaasham- Aandhyam/blindness **Malaha-** Dosha **Chaadayed-** Covers

If this stage of third patala(kacha) is ignored, the vitiated doshas enters and gets localized in the fourth patala causing complete covering of the drishti mandala leading to linganaasha (blindness).

Probable correlation : Mature cataract

Vataja Timira, Kācha and Līganāsha

- In Vātaja timira patient sees the objects as curved/distorted, moving, dirty, slightly reddish, and visualizes webs, hairs, mosquitoes and rays of light but intermittently gets clear vision.
- Vātaja Kācha: If the above stage is neglected, it leads to condition called kācha. In this the drushti will be red in colour and visualizes the face without nose. The patient also sees scattered light of moon and lamp etc. (coloured hallos). The curved objects look straight and vice versa.
- Vātaja Līganāsha: The stage of kācha further advances and leads to drushti being covered with smoke and dust. Drushti appears bright red in colour and may be either big or small. This further leads to complete loss of vision and this condition is known as līganāsha.

Pittaja Timira, Kācha and Līganāsha

In Pittaja timira, patient falsely visualizes flashes of sunlight, lightening, glow of worm and spark of fire. The objects appear deep blue in colour like the feather of the peacock or tittira (partridge).

In Pittaja kacha, the drushti appears light blue and hence, visualizes objects also in the same colour. Sun, moon, fire, mirage, and rainbow is viewed as surrounded by haloes.

In Pittaja līganāsha, the drushti is unctuous, blue in colour similar to the colour of honey bee or yellowish like bell metal. In this there will be loss of vision.

Kaphaja Timira, Kācha and Līganāsha

In Kaphaja timira the objects are viewed as white and unctuous, like a conch shell, moon, flower of kunda or petals of kumuda. Even if the sky is clear (cloudless), patient sees as though the clouds are moving.

In Kaphaja kacha the objects appear lusterless like covered moon, sun etc. Drushti appears white in colour.

In Kaphaja līganāsha

- The drushti is solid, unctuous and appears white like conch shell, flower of kunda, moon, kumuda (lilly) or alum.
- The drushti is not stable like a drop of water placed on lotus leaf.

- Drushti constricts in bright light and dilates in dim light.
- There will be loss of vision.

Raktaja Timira, Kācha and Līganāsha

Raktaja timira- A patient of raktaja timira views all objects as red, green, dark or as though covered with black smoke.

Raktaja kacha- Drishti appears red or black and the person views all the objects as red or black.

Raktaja līganāsha- In this, the colour of the drishti further changes to the colour of coral, petals of red lotus or black. It is lustreless and the patient is unable to see anything.

Samsargaja and Sannipataja Timira, Kācha, Līganāsha

When there is vitiation of doshas in combination of two or three, then the lakshans of combined doshas are seen in timira, kacha and līganāsha.

A patient of sannipataja timira views objects,

- In different colours
- one object as many
- Views objects more or less than the normal
- Vision sometimes becomes clear and sometimes hazy without any reason.
- As though spread all around
- Double vision all around
- Flashes of light.

In kacha and līganāsha, various kinds of colours appear in the drushti due to the vitiation of tridoshas.

PARIMLĀYI (Eale's disease/Cataract)

It is a Pittaja Yāpya Vyādhi

पित्तं कुर्यात् परिम्लायि मूर्च्छितं रक्ततेजसा । पीता दिशस्तथोद्यन्तमादित्वमिव पश्यति ॥
विकीर्यमाणान् खद्योतैर्वृक्षांस्तेजोभिरिव च । रक्तजं मण्डलं दृष्टौ स्थूलकाचानलप्रभम् ॥
परिम्लायिनि रोगे स्यान्म्लाय्यानीलं च मण्डलम् । दोषक्षयात् कदाचित् स्यात्स्वयं तत्र च दर्शनम् ॥ (S.U.7/25-29)

Pittam kuryāt- Pitta causes Murchitam- Pervade Rakta tejasa- Teja of rakta
Peeta- Yellow Disha- Direction Tatho- Similarly
Aadityam iva udyantam- Like rising sun Pashyati- Sees

Vikeerya maanan- Spreading rays	Khadyótaihi- Flames of glittering lights
Vruksham- In the trees	Tejobhīreva- Like other shining objects
Cha- and Raktajam- Due to rakta	Mandalam- Drushti mandalam
Drushtau- Pupillary region	Sthūla- Thick Anala prabham- Like fire
Syāt- Does	MLāyā ānilam- Light blue
Cha-and/Mandalam- Circular	Dosha kshayāt- Due to decreased dosha
Kadāchit- Occasionally	Syāt- Does Swayam- Spontaneously
Tatra- That	Darshanam- Vision

- Parimlāyi is caused when vitiated Pitta combines with Rakta tejas.
- The patient visualizes yellow colour in all direction like the rising sun and flashes of light similar to fire fly or other shining objects glittering in tree
- Further, drushti appears thick and fire like. It may also appear as light blue circular band. When the doshas subside, the patient visualizes clearly

SĀDHYĀSĀDHYĀTHA OF DRISHTIGATA ROGA

	Sushruta	Vagbhata
Sādhya	<ul style="list-style-type: none"> • 6 types of timira • Kaphaja lingānāsha • Dhoomadarshi • Pitta vidagdha drushti • Kapha vidagdha drushti 	<ul style="list-style-type: none"> • 6 types of timira • Kaphaja lingānāsha • Dhoomara • Pitta vidagdha drushti • Ushna vidagdha drushti • Amlavidagdha • Doshāndhya
Yāpya	<ul style="list-style-type: none"> • 6 types of kācha 	<ul style="list-style-type: none"> • 6 types of kācha • Nakulāndhya
Asādhya	<ul style="list-style-type: none"> • 5 types of lingānāsha • Gambheerika • Hriswajādyā • Nakulāndya 	<ul style="list-style-type: none"> • 5 types of lingānāsha • Gambheera • Hriswajādyā • Aupasargika lingānāsha

Rogas in the first and second patala is Sādhya.

Third patalagata is Yāpya.

Fourth patalagata is Asādhya except Kaphaja lingānāsha.

SĀMANYA CHIKITSA FOR TIMIRA

Based on the predominance of dosha, the following chikitsa can be adopted.

Vāgbhata	Sushruta
Snehapana	Samshodhana
Raktamókshana	Raktamókshana
Viréhana	Viréhana
Nasya	Samshamana Nasya
Anjana	Putapāka
Shiróbasti	Anjana
Bastikriya	Dhooma
Tarpana	Tarpana
Lépa	
Séka	

- For pāna- Purāna ghrīta or triphala ghrīta
- Raktamókshana should be done in prathama and dwitīya patalagata timira. (S.U.17/28).
- Viréhana- Ghrīta prepared out of dashamoolayukta triphala kalka, triphala panchamoola kwātha, dugdha and eranda taila (A.H.U.13/49-50).
- In Timira-Nasya, tarpana etc kriyakalpas should be done depending on the predominant dosha as in Abhishyanda.
- Nirooha and Anuvāsāna basti as mentioned in Vātaja peenasa roga.

Triphala prayoga in Timira

- | | |
|------------------------------|------------------|
| • Triphala churna+Tila taila | - Vātaja timira |
| • Triphala churna+Ghrita | - Pittaja timira |
| • Triphala churna+Madhu | - Kaphaja timira |

Vātaja Timira Chikitsa

- **Shodhana:** Eranda taila with milk is given for Virechana.
- **Nasya :** Jeevantiyadi taila (Vagbhata).
- **Putapāka:** Saindhava, ghrita, honey mixed with flesh of vulture, deer etc.
- **Anjana:** Vasādhyanjana (vasa of vulture, snake, cock mixed with madhuyashti)

Vātaja Kācha Chikitsa

- **Anjana:** Srotōnjana is kept in the mouth of krishnasarpa, tied with kushā grass and kept for 1 month. Then the srotōnjana is removed and mixed with equal quantity of saindhava and jāti kusuma.
- **Tarpana:** Shatāhvādi ghrita (Shatāhva, kushta, jatamāmsī, kākoli dwaya, yashti, prapoundarika, sarala, pippali and devadāru along with ghritha and ksheera).
- **Putapaka:** Prasādana and snehana putapaka.

Pittaja Timira Chikitsa

- **Shodhana:** Virechana with triphala ghrita
- **Nasya:** Nasya with kakōlyādi ghrita (madhuroushadhi siddha ghrita).
- **Tarpana:** Tarpana with madhuroushadhi siddha ghrita (kakolyādi ghrita).
- **Putapaka:** The above ghrita along with māmsa.
- **Sirāvyadha:** To be done after snēhapāna.
- **Virēchana:** With sharkara, ela, trivrit churna and honey.
- **Sēka and lepa:** With Sheetala dravyas is done on netra, mukha and shiras.
- **Anjana:** Prepared out of sāriva, padmaka, ushīra, mukta, lōdhra and chandana.
- **Rasakriyānjana:** Rasānjana, kshoudra, sitā, manashila and yashti.
- **Pratyanjana:** Rasanjana/souveeranjana with equal quantity of tuttha.

Pittaja Kācha Chikitsa

Anjana: Méshashṛunga and souveeranjana to be mixed with srotōanjana or rasānjana in equal quantity.

Rasakriyānjana: Swarasa of Palāsha pushpa, rohita, madhuka pushpa is mixed with supernatant part of madira and madhu.

Kaphaja Timira Chikitsa

- **Snehapana:** With ghrita prepared from gudūchi, triphala and pippali
- **Sirāvyadha**
- **Virēchana :** With pooga, abhaya, shunti, krishna, nishótha and dantibeeja kashāya
- **Nasya :** Goshakrut siddha taila.
- Taila prepared from ushira, lodhra, triphala and priyangu.
- **Dhoomapāna:** With vidanga, pāta, apamārga and ingudi.
- **Tarpana:** With ghrita prepared out of ksheerivruksha kashaya, haridra and nalada kalka.
- **Putapāka:** With Jāngala māmsa, pippali, madhu, saindhava lavana.
- **Anjana**
 - a. Kokilavarti anjana : krishna louha bhasma, trikatu, triphala, saindhava, rasānjana.
 - b. Vimalavarti anjana: shankha, priyangu, manashila, triphala, trikatu.
 - c. Rasakriyānjana.
- Manahshila, trikatu, shanka bhasma, madhu, saindhava, kāseesa and rasānjana.
- Kāseesa, rasānjana, shunti, guda.

Sannipataja Timira Chikitsa

Depending on the predominance of dosha

- Tarpana
- Putapaka

- Nasya
- Anjana should be performed

Anjana yogas in Sannipātāja timira-

- Anjana prepared out of bone marrow of nocturnal animals, flowers of mēsha shringi, sroto anjana, yashtimadhu.
- Anjana with ushira, pippali, saindhava, ghrita and madhu.

Raktaja and Parimlayi Timira Chikitsa (S.U.17/46)

Pittaja timira nāshaka nasya, tarpana, putapāka etc is indicated.

Sira mokshana is contraindicated in Kācha.

Linagāsha Chikitsa

Vataja linganāsha : Asādhya

Pittaja linganāsha : Asādhya

Kaphaja linganāsha: Shastra sādhyā

Shastra karma for kaphaja linganāsha

Indications for Shastra Karma: (S.U.17/55-56)

In Kaphaja linganāsha, Shastrakarma can be done if :

- The drushti is not semilunar, sweat drop or pearl shaped.
- The drushti is instable, irregular, thin at the centre, striated or shining excessively.
- Drushti is not painful or red in colour.
- Vagbhata has advised surgery- when linganāsha is completely formed (ghani bhūta) or when there is complete loss of vision and not associated with any complications.

Contra indications for shastra karma (A.S.Su. 36/8)

The patients not suitable for Sirāvyadha are contraindicated for shastrakarma.

Pūrvakarma

- Shastrakarma is carried out on a auspicious day in a room devoid of heat or cold.
- Patient should undergo snehana and swedana procedures.

Pradhāna karma

- The patient is made to sit comfortably on chair and an attender should hold his head firmly.
- The surgeon should open the eyes of the patient wide and ask the patient to look towards his nose and confidently hold Yavākriti Shalāka with thumb, middle and index finger of his right hand.
- Incision and Puncturing should be made near the outer canthus leaving two-third part of sclera from the cornea in a place devoid of blood vessels (daivikruta chidra).
- The proper puncturing (vyadha) is characterized by production of a typical sound and outflow of drop of a liquid (vāri bindu).
- Once the proper puncturing is done, eye should be irrigated with human milk.
- Swedana with vataghna leaves should be given from outside the eye by firmly holding the Shalaka in position.
- Then drushti mandala is properly scrapped (lekhana) with the tip of the Shalāka.
- Even after scrapping if the dosha (kapha) remains, patient is asked to blow closing the opposite nostril to expel the accumulated kapha.

Paschat karma

- Then ghrita is applied to the eyes and bandaged.
- Later the patient is made to lie in supine position in a room devoid of dust, smoke, wind, sunlight.
- Patient is advised not to belch, cough, sneeze, spit or shiver.
- Regimens like āhāra, vihāra as explained in snehapāna vidhi should be followed.
- Every third day eyewash (prakshālana) should be done with kashāya prepared from vātaghna dravyas to avoid aggravation of vāta.
- After three days, mrudu swedana should be done externally.
- All the above regimens should be followed for ten days.
- Later on nasya, tarpana, laghu anna, shirobasti etc should be followed for improving drushti.

Samyak siddhi lakshana

- The drushti becomes clear similar to the Sun in a cloudless sky.
- Pain and discomfort gets relieved.

Complications of surgery

Redness, swelling, pain, blood mixed discharge, adhimantha and loss of vision.

Pathya in Timira

Jeevanti shāka, tandulīyaka, vara vāstuka, kshétra vāstuka, bāla mūlaka, pakshi māmsa, jāngala māmsa, patōla, karkotaka, kāravella, vārtaka, arani (agnimantha), shigru, nīla, sahachara along with ghee.

Special Measures For Preventing Timira

- Daily, early morning sprinkle the eyes by filling the mouth with water.
- Rub the palms and place it over the eyes immediately after having meals.

Chapter**8B**

- Bāhya (Sanimittaja and Animittaja) Linganāsha
- Doshāndya (Raatrandhya)
- Kapha Vidagdha Drushti
- Naktāndhya
- Ushnavidagdha Drushti
- Pitta Vidagdha Drushti
- Amla Vidagdha Drushti
- Dhoomadarshi
- Hriswajādyā
- Gambheerika
- Nakulāndhya

BAHYA LINGANĀSHA

Drushtigata rogas are 12 in number. Apart from these, two more drushti gata rogas are being mentioned.

बाह्यौ पुनर्द्विविह सम्प्रदिष्टौ निमित्ततश्चाप्यनिमित्ततश्च ॥ (S.U.7/42)

They are called 'Bahya Liganāsha' because they are caused due to external factors & not due to vitiation of the dosha.

Based on the known & unknown etiology they are classified into 2 types as :

- (1) Sanimittaja (2) Animittaja

Both are said to be Asādhya

1. Sanimittaja Liganāsha (With known etiology)

निमित्ततस्तत्र शिरोभितापाज्ज्ञेयस्त्वभिष्यन्दनिदर्शनेश्च ॥ (S.U.7/43)

Nimitta- Etiology

Shirobhitap- From headache

Jneyaha- Considered as

Abhishyanda nidarshanaihi- Symptoms of conjunctivitis is found.

In this the cause of vision loss is well known. Various types of head injuries, ocular trauma, polluted air etc (Dalhana) cause signs and symptoms as seen in Abhishyanda and finally leads to complete loss of vision.

2. Animittaja Linganaśha (Without specific cause)

सुरर्षिगन्धर्वमहोरगाणां सन्दर्शनापि च भास्वराणाम् । हन्येत दृष्टिर्मनुजस्य यस्य स लिङ्गनाशस्त्वनिमित्तसङ्गः ॥
तत्राक्षि विस्मयमिवावभाति वेदूर्यवर्णा विमला च दृष्टिः ॥ (S.U.7/43-44)

Surā, rishi, gandharva, mahōruga-	God, sages, celestial musicians, large snake
Sandarshane-	On seeing
Cha- and	Api- Also
Hanyet- Lost	Bhaswaranam- Glittering objects
Yasya- In the person	Drushti- Vision
Tatra- Here	Sa- That
Avabhati- Appears	Vispashtam eva- Very clear
Vimala- Transparent	Vaidurya varna- Colour like cat's eye
	Cha-and

Since there is no specific cause, loss of vision is attributed to.

- Gods, sages, gandharva, large snakes
- Glittering objects/solar or lunar eclipse.

In this condition, inspite of the drushti being clear and transparent like the colour of Vaidurya (as there will be no accumulation of malas) there will be loss of vision.

Probable correlation: Amaurosis- In this condition there will be loss of vision but no signs will be seen on examination.

Aupasargika Linganaśha

Aupasargika linganaśha is considered as Bāhya linganaśha by Vagbhata and is said to be Asādhya.

सहस्रैवालपसत्वस्य पश्यतो रूपमद्भुतम् । भास्वरं भास्करादि वा वातादया नयनाश्रिताः ॥
कुर्वन्ति तेजः संशोष्य दृष्टिं मुषितदर्शनाम् । वेदूर्यवर्णा स्तिमितां प्रकृतिस्थामिवाव्यथाम् ॥
औपसर्गिक इत्येष लिङ्गनाशो ॥ (A.H.U.12/30-31)

When weak minded individuals are exposed to bright, luminous objects or bright sunlight, vātadi doshas get localized in the eye and dries up the pitta resulting in complete loss of vision. But, the drushti mandala appears clear (like vaidurya), stable and painless.

DOSHĀNDYA (Raatrāndhya)

अक्षे अस्त मस्तक न्यस्त गन्धस्तौ स्तम्भं आगताः । स्युर्यन्ति दृशं दोषा दोषान्यः स गतो अपरः ॥
दिवाकर करस्पृष्टा भ्रष्टा दृष्टिपयान्मलाः । विलीनलीना यच्छन्ति व्यक्तमत्र अद्वि दर्शनम् ॥ (A.H.U.12/24-25)

Arke- Sun	Mastaka- Top	Nyasta- Scattered
Gabhasta- Sun rays	Stambha- Obstruction	Sthagayanti- Covers
Drisham- Sight	Dosha- Ratri	Divakara- Sun
Prushta- Touch	Bhrashta- Destroyed	Vileena- Liquifies
Ahni- Day time.		

Doshāndya is a condition in which the doshas scatters and covers the drushti during night causing obstruction of vision. But during daytime, the rays of sunlight liquifies the accumulated doshas in the drushti, enabling the person to see clearly.

Chikitsa

- Karanjādi varti- Varti prepared out of karanja, utpala, swarna gairika, ambhōja.
- Varti prepared out of trikatu, triphala, ela, manashila, samudraphena trituated with goats milk.
- Yakrit Pippali Anjana
 - *Pippali is placed in liver of goat and cooked in putapaka method.
 - *Then it is dried and powdered. This powder is trituated with madhu and used as anjana.
 - *It is considered as the best anjana for naktāndhya.

Probable correlation: Night blindness as in vitamin A deficiency, Cortical Cataract, Retinitis pigmentosa etc.

KAPHA VIDAGDHA DRUSHTI

It is a Kaphaja Sādhya Vyādhī.

तथा नरः श्लेष्मविदग्धदृष्टिस्तान्येव शुक्लानि हि मन्यते तु ।
त्रिषुस्थितोऽल्पः पटलेषु दोषो नक्तान्यमापादयति प्रसह्य । दिवा स सूर्यानुगृहीतचक्षुरीक्षेत रुपाणि कफाल्पभावात् ॥

(S.U.7/37-38)

Shukla- White	Manyate tu- Views the objects	Trishu- Third
Suitho- Situated	Alpaha- Mild	Apadayati- Created
Prasahya- Immediately		Divya- In day
Suryanugruhita- Due to effect of sun		Eekshate- Able to see
Rupani- Objects	Kaphaalpabhavat- Decreased kapha dosha	

Kapha vidagdha drusti is a condition in which the vitiated kapha gets localized in drushti and makes it appear white. The patient perceives all objects in white colour.

When dosha invades all the three patalas- the patient is unable to view objects at night. But during day, due to the sunlight the kapha depletes and restores some amount of vision.

Chikitsa

- Kaphaja abhishyandahara chikitsa like nasya, séka, anjana, putapāka, and tarpana. Vamana, virechana is also advised.
- Internally trivrit ghrita, tilvaka ghrita or purāna ghrita.

Anjana yogas

- Anjana prepared out of sróto anjana, saindhava, pippali, renuka and ajā mutra.
- Manashila, abhaya, trikatu, bala, tagara, samudraphéna with goat's milk.
- Spleen and liver of goat cooked using ghee and taila is used internally. The same is mixed with sarshapa taila & used as anjana.

Probable correlation: Night blindness/Retinitis pigmentosa

NAKTĀNDHYA

Acharya Dalhana has quoted that sage Videha has mentioned Naktāndhya as a condition causing loss of vision at night in diseases like Hrusvajādyā, Nakulāndhya, Kaphavidagdha drushti etc. Among these Hrusvajādyā and Nakulāndhya are said to be Asādhya.

USHNAVIDAGDHA DRISHTI

According to Vagbhata

उष्ण तपस्य सहसा शीतवारिनिमज्जनात् । त्रिदोष रक्त संपृक्तो यात्युष्मोर्ध्वं ततो अक्षिणि ॥
दाहोपे मलिनं शुक्लं अहनि आविलदर्शनम् । रात्रावाग्न्यं च जायेत विदग्ध उष्णेन सा स्मृता ॥ (A.H.U.12/26-27)

Sahasa- Suddenly	Sheeta vari- Cold water	Nimajjana- Immersion
Samprukto- Together	Dahoshe- Burning sensation	Shuklam- Sclera
Malina- Dirty	Ahni- Day	Avila- Not clear
Ratrou- Night	Aandhyam- Blindness	

If a person gets immersed in cold water immediately after exposure to sunlight, all the three doshas along with rakta gets vitiated and produces ushma. The ushma thus generated moves upwards and gets localized in netra causing symptoms such as:

- Severe burning sensation
- Muddy discolouration of sclera (shuklabhaga)
- Patient is unable to view objects clearly during day
- Night blindness

PITTA VIDAGDHA DRUSHTI

It is Pittaja Sādhya Vyādhi

चित्तेन दृष्टेन गतेन दृष्टिं पीता भवेद्यस्य नरस्य दृष्टिः । पीतानि रूपाणि च मन्यते यः स मानवः पित्तविदग्धदृष्टिः ॥
प्राप्ते तृतीयं पटलं तु दोषे दिवा न पश्येन्नृशि वीक्षते च । रात्रौ स शीतानुगृहीतदृष्टिः पित्ताल्पभावादपि तानि पश्येत् ॥
(S.U.7/35-36)

Dushtena- Vitiated	Pīta- Yellow	Narasya- Human
Tritiya patala- Third patala	Divya- Day	Veekshate- Sees
Ratraou- Night	Sheetānugruhita- Due to effect of cold	
Pittalpa bhavat- Pitta decreases		

Pitta vidagdha drushti is a condition in which the vitiated pitta gets localized in drushti and makes it yellow. The patient perceives all objects yellow in colour.

- If dosha localizes in the third patala- No vision during day but can see objects at night. This is because pitta decreases at night due to the effect of sheeta guna.

According to Vāgbhata

भवेत्पित्तविदग्धाख्या पीता पीताभदर्शना । (A.H.U.12/16)

Peeta- yellow (both drushti and darshana becomes yellow)

The features of Pittavidagdha drushti are:

- The patient perceives all objects as yellow.
- The drushti appears yellow.

Chikitsa

- Pitta abhishyandahara chikitsa like nasya, seka, anjana, putapaka, and tarpana.
- Internally triphala ghrita, tilvaka ghrita and purāna ghrita.

Anjana yogas

- * Anjana prepared out of rasānjana, jāti patra rasa, kshoudra, tālisa, swarna gairika and go shakrit. (S.U.17/12).
- * Anjana prepared out of kashmari, gambhāri pushpa, yashti madhu, dāru haridra, lódhra, rasānjana and honey. (S.U.17/15).
- * Anjana prepared out of saindhava, muḍga, trikatu, souveeranjana, manashila, haridra, daru haridra and rakta chandana.

Probable correlation: Day blindness (Hamaralopia)/Central cataract

Siravyadha is contraindicated in pitta and kapha vidagdha drushti (S.U.17/4-6)

AMLAVIDAGDHA DRUSHTI

It is an Aushadha Sādhya Vyādhi.

भृशम् अम्ल अशनाद् दोषैः सारैर्या दृष्टिराचिता। सकलेद कण्डु कलुषा विदग्धा अम्लेन सा स्मृता॥ (A.H.U.12/28)

Bhr̥sham amla ashanaat- Excessive intake of sour foods **Drushti-** Vision

Aachita- Covering of drushti (blurriness of vision)

Klédā- Moistness

Kaṇḍu- Itching

Kalusha- Dirty

The disease in which excess intake of sour substances, vitiates tridoshas and rakta leading to dirty discharge, itching in the eyes and blurriness of vision is known as Amlavidagdha drushti.

Chikitsa

Similar to Pitta vidagdha drushti.

DHOOMADARSHI

It is Pittaja Sādhya Vyādhi.

शोकज्वरायासशिरोगितापैरभ्याहता यस्य नरस्य दृष्टिः । सधूमकान् पश्यति सर्वभावांस्तधूमदर्शीति वदन्ति रोगम् ॥ (S.U.7/39)

Shōka- Grief

Jwara- Fever

Aayasa- Exhaustion

Shiroabhitāpa- Headache

Abyahata- Suffering from

Sadhumakaan pashyati- Smoky vision.

In Dhoomadarshi, the drushti gets vitiated due to grief, fever, excessive exhaustion or headache leading to smoky vision i.e. all objects are seen as though covered with smoke.

According to Vagbhata it is called 'Dhoomara'

शोक ज्वर शिरोग सन्तप्तस्य अनिलादयः । धूमाविलां धूमदृशं दृशं कुरुः स धूमरः ॥ (A.H.U.12/29)

Shirorōga- Diseases of shiras

Santapta- Suffering

Dhooma aavila- Covered by smoke

Vātadi doshas gets vitiated in person suffering from grief, fever or diseases of head. Due to this, vision will be blurred as though covered with smoke. This condition is called as Dhoomara.

Chikitsa

युज्यात् सर्पिर्धूमदर्शी नरस्तु शेषं कुर्याद्रक्तपित्ते विधानम् ।

यच्चैवान्यत् पित्तहृच्चापि सर्वं यद्वीसर्पे पैत्तिके वै विधानम् ॥ (S.U.10/16)

- Since it is a Pittaja roga, it should be treated similar to Pittaja/Raktaja Abhishyanda, Pittaja visarpa and Pittavidagdha drushti.
- Purāna ghrita pāna.
- Snigdha Viréchanā.
- Ālepa with paste of sheeta veerya dravya.
- Anjana with:
 1. Go shakrit rasa, ksheera and ghrita.
 2. Rasakriya prepared with swarna gairika and tāleesa churna.
- Nasya using ghrita prepared with méda, shabaraka, ananta, manjishta, dārvi, yashti, go ksheera and tila taila.
- Tarpana using the above ghee or goghritha.
- If there is no response to the above treatment Sirāvyadha is advised.

Probable correlation: Smoky vision is a symptom seen in conditions like refractive errors, glaucoma or early cataract.

HRISWAJĀDYA

It is Pittaja Asādhya Vyādhi

सहस्रगाड्यो दिवसेषु कृच्छ्रादहस्वानि रूपाणि च येन पश्येत् । (S.U.7/40)

Hrisva- Small **Jādyā-** Disease **Diva-** Day
Kruchraat- Difficulty **Rupa-** Objects

It is a condition in which-

- There will be difficulty in day vision
- Objects appear smaller in size.

According to Vāgbhata

दृष्टिः पित्तेन ह्रस्वाख्या सा ह्रस्वादर्शिनी ॥ (A.H.U.12/15)

Hrisva- Small **Hrisvadarshini-** Sees things as small

In this condition the eye becomes small due to the vitiation of pitta and hence all the objects appears smaller.

Probable correlation: Refractive errors, Choroiditis

GAMBHEERIKA

"Gambheera" denotes deep. In this the eyeball is pulled inwards.

It is Vātaja Asādhya Vyādhi.

दृष्टिर्विरूपा श्वसनोपसृष्टा सङ्कुच्यतेऽभ्यन्तरतश्च याति ।

रूपावगाढा च तमक्षिरोगं गम्भीरिकेति प्रवदन्ति तज्ज्ञाः ॥ (S.U.7/41)

Drushti virūpa- Disfigured **Shwasana-** Vata dosha **Upasrushta-** Afflicted

Sankuchite- Shrunk **Abhyantaratascha yati-** Pulled inwards

Ruja- Painful **Cha- And Tam-** That **Akshi roga-** Eye disease

Pravadanti- Told as **Tajnya-** Experts.

The disease in which the eyes get shrunken, disfigured, pulled inwards and associated with severe pain due to the vitiation of vata is called Gambheerika.

Achārya Vagbhata, names it as 'Gambheera'

.....वाते तु सङ्कोचयति दृक् सिराः । दृग्मण्डलं विशति अन्तः गम्भीराद्गसौ स्मृता ॥ (A.H.U.12/12)

Sankochayati- Constricts **Vishati antaha-** Pulled inwards

The vitiated vata dosha constricts the siras of drushti & pulls the drushti mandala inwards. This condition is called Gambheera.

Probable correlation: Phthisis bulbi/Endophthalmitis.

Phthisis bulbi is a small, shrunken, non-functional eye.

NAKULĀNDHYA

It is a Sannipatāja Asādhya Vyādhi.

The word 'Nakula' is indicative of shining and glowing appearance of the eyes of mongoose.

विद्योतते येन नरस्य दृष्टिर्दोषाभिपन्ना नकुलस्ययद्वत् ।

चित्राणि रूपाणि दिवा स पश्येत् स वै विकारो नकुलान्धसङ्गः । (S.U.7/40)

Vidhyotate- Glitters

Doshabhipanna- Vitiated with dosha

Drushti- Vision

Narasya- In human being

Nakulasya yawat- Like mongoose

Chitrani- Objects

Diva- In day time

Pashyet- See

Vikāro- Disease

Sangnya- Called as

Nakulāndhya is a condition in which tridoshas get vitiated in drushti mandala causing glittering of eyes like that of mongoose. Here objects are perceived in various colours during day time.

According to Vāgbhata

द्योत्यते नकुलस्येव यस्य दृङ् निचिता मलैः । नकुलान्यः स तत्राह्नि चित्रं पश्यति नो निशि ॥ (A.H.U.12/23)

Dyotyate- Shines **Nakulasya-** Mongoose

Nichita- Covered

Malaihi- Dosha

Ahni- Day

Chitram- Different colors

Nishi- Night

The condition in which vitiated doshas make the drushti to shine like that of a

mongoose is called as Nakulāndhya. Due to the vitiation of tridoshas in the drushti, the patient perceives various colours during day and cannot see anything at night.

Acharya Charaka has named it as Kapótāndhya.

Chikitsa

Though Sushruta considered Nakulāndhya as Asādhya vyādhi, Vagbhata has included it under Yāpya vyādhi.

Vāgbhata has advised to follow Tridoshaja timira chikitsa.

Anjana yogas

- Rasakriya anjana prepared using ghrita, kshoudra, gomaya swarasa, tarkshya, gairika and talisapatra.
- Anjana prepared by triturating maricha and dadhi.

Probable correlation: Night blindness/Colour blindness

Ocular Diseases Disturbing Vision

These are the ocular diseases disturbing vision.

Sushruta	Vāgbhata
1. Pitta vidagdha drishti	1. Pitta vidagdha
2. Shleshma vidagdha drishti	2. Ushna vidagdha
3. Dhūmadarshi	3. Amlavidagdha
4. Hṛiswajādyā	4. Dhūmara
5. Nakulāndhya	5. Hṛiswaja
6. Gambhīrika	6. Nakulāndya
	7. Gambhīra
	8. Doshāndhya

NAYANĀBHIGHĀTA

(Ocular injuries and their management in Ayurveda)

The eye is a sensitive organ exposed to the external environment and is more prone to injuries. It is well protected by a hard bony cavity called the orbit. The eyelids, eyelashes and eyebrows protect it from external factors like dust and sunlight. The soft tissues in the eyeball acts like a cushion and protects it from injuries.

Effect of ocular injury

अभ्याहते तु नयने बहुधा नराणां संरम्भ राग तुमुलासु रुजासु धीमात् ॥ (S.U.19/3)

Abhyahate- Injury

Nayana- Eyes

Narānaam- Human beings

Samrambha- Swelling

Bahudha- Various means

Tumulasu rujasu- Severe pain

Dhiman- Intelligent physician

Rāga- Redness

Injury to the eye occurs by various means and this results in severe pain, swelling and redness of the eyes.

Causes of ocular injury

The causes of ocular injuries mentioned by Achārya Videha are as follows:

- Application of teekshna anjana on already strained eyes.
- Exposure to wind, heat, smoke, dust etc.
- Insect bite.
- Eye getting injured due to water sports (swimming against water flow, diving etc).
- Keeping awake at night.
- Excessive fasting, straining, tiredness, fearfulness.
- Weak eyes visualizing sun, fire, lunar eclipse, stars and moving objects continuously.

All the above factors produce redness, burning, pricking sensation, swelling, inflammation, foreign body sensation and other different types of pain in the eyes.

Traumatic wounds

Sushruta mentions 6 types of Vrana or traumatic wounds. They are- 1. Chinna 2. Bhinna 3. Viddha 4. Kshata 5. Picchita and 6. Ghrishta. In these conditions Sadyovranahara chikitsa is indicated.

Displacement of the eye ball

Injury or a hard blow can either push the eyes outwards (vilambita netra) or inwards (ati pravishta netra).

Chikitsa (Sushruta)

Treatment of Ati pravishta netra (pushed inwards) is done by:

- Holding the breath (Praanoparodha).
- By sneezing (Kshuta).
- Inducing vomit (Vamana).
- Throttling (Kantha rodha).

Treatment of Vilambita Netra (protruded) is done by :

- Placing the eyes in original position (Purasthat).
- Deep inspiration (Uchinganam).
- Pouring of cold water over the head (Shirase vaari avasechanam).

33 S.T.-I

General line of treatment in ocular injuries

नस्य आस्यलेप नेत्र परिषेचन तर्पणादिमुक्तं पुनः क्षतज पित्तज शूल पथ्यम् ।
दृष्टिप्रसादनं विधिमाशु कुर्यात् स्निग्धैर्हिमैश्च मधुरक्षतया प्रयोगैः ॥
स्वेदाग्नि धूमभय शोक रुज अभिघातैरभ्याहतामपि तथैव भिषक् चिकित्सेत् ॥ (S.U.19/3-4)

In ocular injuries the treatment to be adopted are:

- Nasya and Tarpana- with ghrita prepared from aja ghrita, goghrita, madhuka, utpala, jeevaka and rishabhaka (S.Chi. 2/44-45).
- Mukha lepa with madhura, sheetala dravyas.
- Netra parisheka- lodhra, yashtimadhu, ajaksheera.
- Snigdha, sheeta and madhura aushadis as indicated in kshataja and pittaja shoola (abhisheandha).
- The injuries caused by sweda, agni, dhuma, bhaya, shoka, ruja and abhighata are treated accordingly on similar lines.

Foreign Body Removal in Ayurveda

Foreign bodies in the eye causes watering, redness and difficulty in blinking. The eyelid should be everted and foreign body can be removed by adopting any of the following method alone or in combination.

- **Pariséchana:** Pouring stream of water or kashāya.
- **Adhmāpana:** Blowing of air.
- **Parimarjana:** Cleaning or removing the foreign body with piece of cotton/cloth, hair or tip of tongue.
- **Lékhana:** Scrapping is done in case of small embedded foreign particles.

Sādhyaśādhya of Nayanābhighāta

The ocular injuries are said to be sādhya if :

- The eye ball is situated in its proper position (yatha sthitha).
- The vision is clear (anavila darshana).

The conditions which are said to be Yāpya are :

- Crushed eyes (picchita nayana).
- Deeply seated eyes (ati avasanna).
- Laxed eyes (srasta).
- Dislocated eyes (chyuta).
- Loss of vision (hata druk).
- Dilated pupil (Visteerna dhrishti).
- Mild congestion (tanu rāga).
- Blurred vision (asat pradarshi).

Based on involvement of Patalas: (S.U.19/6)

- **Sādhya-** If one patala is injured
- **Kṛchrasādhya-** If two patalas are injured
- **Asādhya-** If three patalas are injured.

Chapter

8C

Errors of Refraction

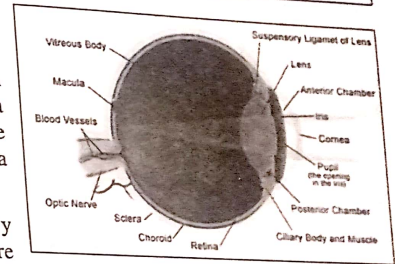
- a. Myopia
- b. Hyperopia (Hypermetropia)
- c. Astigmatism
- d. Presbyopia
- Cataract- Classification of Cataract.
- Senile Cataract and its stages of development
- Cortical, Posterior Subcapsular and nuclear cataract
- Surgical Management of Cataract

ERRORS OF REFRACTION

Emmetropia

When parallel rays of light from infinity come to focus on the retina with accommodation at rest, the condition is called emmetropia (normal refraction).

In the emmetropic (normally refracted) eye, entering light rays are focused on the retina by the cornea and the lens. During accommodation, the ciliary muscles adjust the shape of the lens so as to properly focus images onto the retina.



Accommodation: The process by which the ciliary muscles change the focal length of an eye lens to focus distant or near objects on the retina is called accommodation.

Ametropia

When parallel rays of light from infinity do not come to a focus upon the retina with the accommodation at rest, is known as ametropia.

Causes of Ametropia

1. **Abnormal length of the eye ball-** Change in the axial length of the eye ball is the most important cause of ametropia. Too long or too short lengths of the globe result in myopia or hyperopia respectively.
2. **Abnormal curvature of cornea and the lens-** Too much or too less curvature of cornea or lens cause myopia and hyperopia respectively.

3. **Abnormal refractive indices of the media-** Increase in the indices of the refractive media (cornea, aqueous and lens) result in myopia, while the opposite condition leads to hyperopia.
4. **Abnormal position of the lens-** Forward displacement of the lens leads to myopia and backward displacement leads to hyperopia.

Types of errors of refraction

1. Myopia or short sightedness
2. Hyperopia or long sightedness and
3. Astigmatism

Myopia

Myopia is a type of refractive error in which parallel rays of light from infinity come to a focus in front of the retina when accommodation is at rest.

Etiology

1. Increased antero-posterior length of the eye ball (Axial myopia).
2. Increased curvature of cornea or lens or both (Curvature myopia).
3. Anterior displacement of crystalline lens (Positional myopia).
4. Increased refractive index of crystalline lens due to senile nuclear sclerosis (Index myopia).

Types of Myopia

1. **Developmental myopia:** It is rare and is characterized by an abnormally long eyeball at birth.
2. **Simple myopia:** It is the most common type of myopia which progresses during childhood and adolescence. It generally stops to progress by the age of 21 years.
3. **Pathological myopia:** It is essentially a progressive or degenerative condition which manifests in early childhood. The refractive error rapidly increases during period of active growth and may reach 20 to 30 (Diopters) by the age of 25.

Clinical features

- Inability to see distant objects clearly.

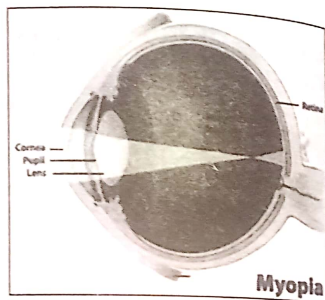


Fig. 8.1

- Eye strain, headache
- Occasionally floaters and flashes of light seen.
- Eyes are prominent with slightly dilated pupils in pathological myopia.
- Deep anterior chamber.
- Ophthalmoscopy reveals vitreous degeneration and opacities, a big optic disc with myopic crescent.
- A highly myopic eye is prone to develop retinal hemorrhage due to vitreous detachment and lattice degeneration leading to detachment of retina.

Treatment

- **Optical treatment:** Prescription of appropriate concave lenses.

Surgical correction

- **Radial Keratotomy (RK)-** In this technique, a central corneal optical zone (3-4mm) is spared and 8 or 16 radial corneal incisions are placed.
- **Photo Refractive Keratectomy (PRK)-** Ablates the central anterior corneal stroma with the help of excimer laser to reduce the corneal curvature.
- **Laser-in-situ keratomileusis (LASIK)-** It is an effective technique for the correction of myopia between 1 and 9 D. A laser refractive keratectomy (within the corneal stroma) is performed using an excimer laser.
- **Phakic lens implantation-** Involves placement of an anterior chamber lens.
- **Removal of crystalline lens-** Corrects high axial myopia of about 21D.

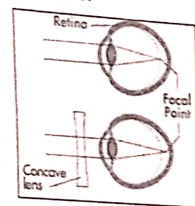


Fig. 8.2

Hyperopia (Hypermetropia)

Hyperopia is an error of refraction wherein parallel rays of light from infinity come to a focus behind the retina when accommodation is at rest.

Etiology

1. **Axial hyperopia:** In this the antero-posterior length of the globe is shorter than normal.
2. **Curvature hyperopia:** In this the curvature of the cornea or lens is flatter than normal.

3. **Index hyperopia:** A decrease in the refractive index of the lens.
4. **Posterior dislocation of the lens:** Backward dislocation of the lens.
5. **Aphakia** (absence of lens) is an example of high degree hyperopia.

Types

1. **Simple hypermetropia:** It includes axial and curvatural hypermetropia. It occurs due to the normal biological variations in the development of eye ball.
2. **Pathological hypermetropia:** It includes index hypermetropia (due to acquired cortical sclerosis), positional hypermetropia (due to posterior subluxation of lens), aphakia (absence of lens) and consecutive hypermetropia (due to surgically over corrected myopia).
3. **Functional hypermetropia:** Occurs due to paralysis of accommodation as seen in third nerve paralysis.

Clinical features

- Blurring of vision for distance as well as for near.
- Asthenopic symptoms such as eye strain and headache.
- The axial length of the eye ball is usually smaller than normal.
- The diameter of the cornea is reduced and the anterior chamber is often more shallow than usual.

Treatment

- **Optical treatment :** Hyperopia with asthenopia is corrected by prescribing convex lenses.

Surgical correction

- **Laser thermal keratoplasty (LTK)-** In this holmium laser is used to reshape the cornea.
- **LASIK-** It steepens the central cornea and is used to correct hyperopia upto 4D.
- **Refractive lensectomy**

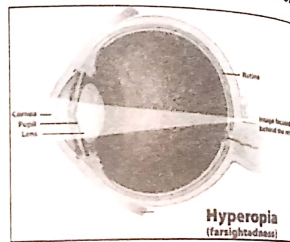


Fig. 8.3

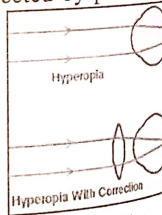


Fig. 8.4

- **Conductive keratoplasty:** It is a non laser procedure that flattens the peripheral cornea and steepens the central cornea. It is recommended for treatment of mild to moderate hyperopia between +0.75 and +3D.

Astigmatism

Astigmatism is that condition in which the refraction varies in different meridians of the eye. Hence a point of focus cannot be formed upon the retina.

Etiology

1. **Curvature astigmatism:** It is the most common and is caused by abnormalities in the curvature of the cornea.
2. **Index astigmatism:** A small amount of astigmatism occurs due to inequalities in the refractive index of different sectors of the lens.

Types

Astigmatism is divided into two categories-

1. Regular and 2. Irregular

1. Regular Astigmatism

Astigmatism is said to be regular when the refractive power changes uniformly from one meridian to another (i.e. there are two principal meridians). They are classified into the following types:

1. **Simple astigmatism:** Where one of the principal meridians is emmetropic and the other is either hyperopic or myopic.
2. **Compound astigmatism:** Where both the principal meridians are either hyperopic or myopic.
3. **Mixed astigmatism:** Where one of the principal meridians is hyperopic and the other is myopic.

Clinical features

- Higher degrees of astigmatism often cause poor visual acuity but vision is not much impaired in mixed astigmatism.

Astigmatism

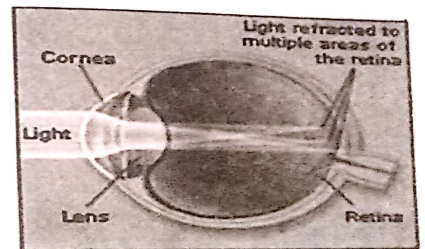


Fig. 8.5

- Symptoms of asthenopia are present.
- The optic disc appears oval or blurred.

2. Irregular Astigmatism

When the curvature and the refractive power of the refractive media are markedly irregular leading to multiple focal points, that produce completely blurred images on the retina, such a condition is called irregular astigmatism.

The irregular astigmatism is caused by corneal scars, penetrating injuries of the eye, keratoconus, lenticonus and immature cataract. The patient with irregular astigmatism often suffers from distorted vision and headache.

Treatment

- **Optical treatment:** Regular astigmatism can be corrected by appropriate cylindrical lens or sphero-cylindrical combination in the form of spectacles.
Irregular astigmatism cannot be corrected by spectacle lenses due to irregularity in the curvature of meridians and hence soft or rigid gas permeable toric lenses are prescribed.
- **Surgical correction**
 1. **Photo astigmatic keratectomy**-Using excimer laser to flatten the steeper meridian.
 2. **LASIK**- Toric LASIK ablations may correct refractive error upto 7D sphere and 3D cylinder.
 3. **Conductive keratoplasty:** The spots are applied to flatten meridian to induce steepening.
 4. **Corneal transplantation** is indicated in case of corneal scarring and ectasia.

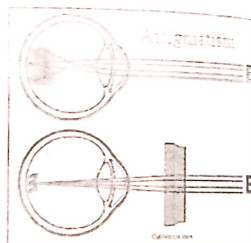


Fig. 8.6

PRESBYOPIA

Presbyopia is not a refractive error but a physiological condition of gradual loss of accommodative power due to age related decrease in the elasticity of lens capsule and lens substance. Typically, presbyopia becomes noticeable by the time a person reaches the early or mid 40's. Besides lenticular changes, loss of ciliary muscle function is also implicated in the development of presbyopia.

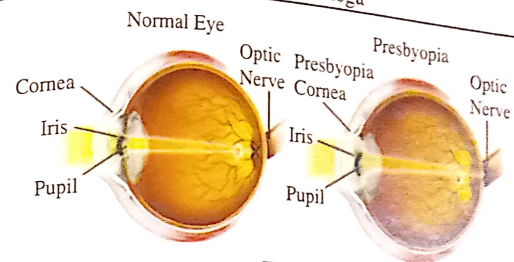


Fig. 8.7

Clinical features

- The onset may be noticed by development of asthenopic symptoms like headache, heaviness or tiring of eyes on prolonged near work.
- Blurring of near vision especially in dim light.
- The patient prefers to keep news papers and books at a greater distance than usual because less accommodative effort is needed.

Treatment

- The goal of correction of presbyopia is to strengthen amplitude of accommodation by prescribing the convex lenses for near vision.
- Presbyopic spectacles can either be single vision reading glass (convex), or bifocals (distant and near vision) or progressive or multifocal lenses.
- **Surgical correction** include conductive keratoplasty, photo-refractive keratectomy, LASIK.
Laser based refractive surgery has been the main line of the treatment in recent years.

CATARACT

Opacity of the lens or its capsule is known as cataract. The lens being an avascular structure cannot develop an inflammatory disease. However degenerative changes in the lens often result in partial or complete loss of vision.

Anatomy of Lens

Lens is a transparent avascular biconvex structure placed between the iris and vitreous. It is suspended by the zonules which connect the lens with the ciliary body. It is covered by an elastic capsule which is a semipermeable membrane. The centres of anterior and posterior surfaces of lens are called as anterior and posterior pole.

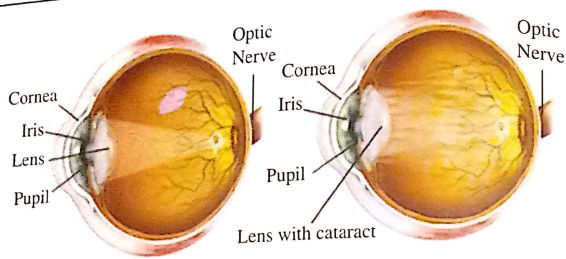


Fig. 8.8

respectively. The superficial part of the lens is called the cortex and the central part is known as the nucleus. The refractive index of lens is 1.39 and the dioptric power is approximately 17.75. The lens continues to grow throughout life and the relative thickness of the cortex increases with age.

The lens has three parts:

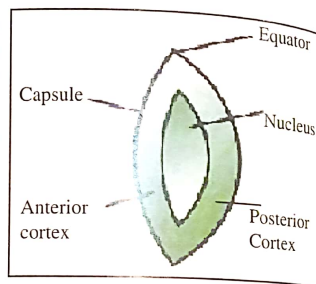


Fig. 8.9

1. **Lens capsule:** It is a transparent homogeneous and highly elastic collagenous membrane.
2. **Lens epithelium:** It is a layer of cuboidal cells that form the anterior subcapsular epithelium. The cells of the epithelium are metabolically active to meet the energy demand of the lens. The cells show high mitotic activity and form new cells which migrate towards the equator.
3. **Lens fibres:** The lens epithelial cells continue to divide and develop into lens fibres. They are mainly composed of soluble proteins. The fibres formed earlier lie in the deeper plane (nucleus of the lens), the newer ones occupy a more superficial plane.

As age advances, the lens also shows changes. In infants it is transparent, spherical and soft. In adults, the lens is firm, transparent and avascular. In old age it is of amber colour, firmer and flatter on both sides.

Classification of Cataract

Morphological classification

Based on the density and site of opacity cataract may be classified as:

1. Capsular (anterior, posterior)
2. Subcapsular (anterior, posterior)
3. Cortical
4. Nuclear
5. Lamellar (zonular)
6. Sutural
7. Coralliform

Etiological classification

1. **Congenital or developmental cataract:** Congenital cataract is present at the birth. Developmental cataract is that cataract, which develops during the development of the lens.

2. **Senile cataract:** Age related cataract.

3. **Complicated cataract:** It is secondary to inflammatory or degenerative diseases like uveitis, high myopia, retinal detachment, glaucoma, retinitis pigmentosa etc.

4. **Metabolic:** Caused by endocrine disorders like diabetic mellitus.

5. **Traumatic:** Caused due to mechanical injuries such as concussion and penetrating injuries.

6. **Radiational:** X-rays, gamma rays, ultraviolet rays, laser radiations.

7. **Dermatogenic:** Atopic dermatitis, Werner's syndrome.

8. **Toxic:** Long term administration of corticosteroids, miotics, chlorpromazine etc.

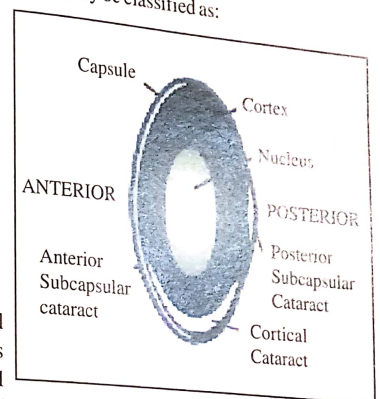


Fig. 8.10

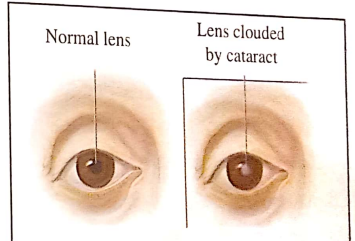


Fig. 8.11

SENILE CATARACT

It is also called as age related cataract. It is the commonest type of acquired cataract. Morphologically, senile cataract occurs in two forms:

1. Cortical senile cataract (soft)
2. Nuclear cataract (hard)

Etiology

- **Age:** Usually above 50 years.
- **Sex:** Is equal in either sex.
- **Bilaterality:** Usually bilateral but almost always one eye is affected earlier than the other.
- **Heredity:** It plays an important role in the incidence of cataract.
- **Dietary factors:** Deficiency of proteins, amino acids and vitamins.
- Other factors include exposure to ultraviolet irradiations, smoking and dehydration.

1. Cortical senile cataract

Pathology: The lens fibres of the cortex are mainly affected. There is hydration due to accumulation of water droplets in between the fibres, and replacement of soluble by insoluble proteins. The proteins are first denatured and then are coagulated forming opacity. Ultimately the whole of the lens becomes opaque and assumes a pearly white appearance.

Symptoms

- Gradual impairment of vision
- Polyopia i.e. one object appears multiple
- Rainbow haloes around the light

Clinical Signs

The development of senile cortical cataract can be divided into the following stages-

a. Stage of lamellar Separation :

- It is a presenile stage characterized by collection of fluid between the lens fibres resulting in lamellar separation.
- Usually this stage is asymptomatic, except that the patient becomes slightly hyperopic.

b. Incipient stage :

- White radial wedge shaped spokes of opacity, with clear areas in between are visible is the periphery of the lens.
- On fundal examination: The opacities appear as dark lines against red fundal glow.
- Visual disturbance such as polyopia (many images of an object) is the common symptom in this stage.

c. Intumescent stage:

- The lens become swollen due to imbibition of the fluid and hence the anterior chamber becomes shallow.
- The progressive hydration causes swelling and opacification of the lens.
- Upto this stage, the lens is not completely opaque. There remains a clear zone of lens fibres between the pupillary margin of the iris and the lens opacity (immature cataract).
- On fundal examination: Very little red fundal glow can be seen.
- Test: If an oblique beam of light is thrown upon the eye, the iris casts a shadow upon grey opacity.

d. Mature stage :

- The entire cortex and the lens becomes opaque white.
- The vision becomes reduced to perception of hand movement or light only.
- On examination : No fundal glow
- Test : If an oblique beam of light is thrown upon the eye, the iris doesn't cast any shadow. This is because when the lens is completely opaque the pupillary margin lies almost in contact with the opaque lens.

e. Hyper mature stage: There are two types of hypermature cataract.

1. **Hypermature morgagnian:** If the stage of mature cataract is neglected, then hypermature stage sets it. In this the whole of the soft cortical matter liquifies to form milky fluid so that the lens is now converted into a bag of milky fluid with the hard nucleus settled at the bottom of the bag.
2. **Hypermature sclerotic:-** The loss of fluid from the mature cataractous lens makes the lens shrunken. The shrinkage of the lens leads to deepening of the anterior chamber and tremulousness of the iris. The lens becomes flatter, the capsule becomes thick and the cataract appears brownish.

2. Nuclear Senile Cataract

Pathology: The nuclear fibres undergo a process of sclerosis. When this process becomes more intensified, the nuclear cataract starts. The nucleus becomes diffusely cloudy and obstructs the light rays. The progress of the cataract is slow and this type of cataract never becomes hypermature.

Symptoms

- Progressive dimness of vision but no polyopia.
- No complaint about seeing haloes around the light.

Signs

- The lens appears brown, dark brown or black.
- Iris shadow is usually present.
- Depending on the advancement of the cataract the vision is reduced to counting fingers or perception of hand movements.
- On examination: There is a central dark area against the red fundal glow.

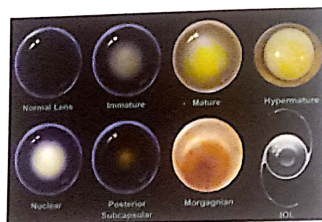

Fig. 8.12

MANAGEMENT OF CATARACT

Nonsurgical measures

1. Treat the cause of cataract
2. Measures to delay progression like intake of iodine, calcium and potassium
3. Measures to improve vision like prescription of suitable glasses, low vision aids and use of dark goggles.

Surgical measures

1. Intracapsular cataract extraction (ICCE)
2. Extracapsular cataract extraction (ECCE)

Surgical Techniques

1. **Intracapsular cataract extraction (ICCE):** In this technique, the entire cataractous lens along with the intact capsule is removed. Therefore, weak and degenerated zonules are a pre-requisite for adopting this method.

Now it has been almost replaced by planned extra capsular techniques and is indicated only in subluxated and dislocated lens.

2. **Extracapsular cataract extraction (ECCE):** In this major portion of the anterior capsule with epithelium, nucleus and cortex are removed leaving behind intact posterior capsule. The technique is safe and most suited for posterior chamber intra ocular lens (IOL) implantation. Phacoemulsification is the most popular method of extracapsular cataract extraction.

Currently ECCE with IOL implantation is the most preferred surgery.

(a) Small incision cataract surgery

It is a type of extracapsular cataract extraction. It is a safe and sutureless surgery. The steps of surgery are similar to ECCE with some modifications in the external scleral incision and delivery of the nucleus.

(b) Phacoemulsification

It is an extracapsular lens extraction performed with the help of a phacoemulsification machine. The phacoemulsifier provides controlled irrigation and aspiration. The phacoemulsification is performed by a phaco hand piece, the tip of which vibrates 28,000 to 60,000 times per second. The emulsified lens is removed by aspiration-infusion.

- Eale's disease
- Hypertensive Retinopathy
- Diabetic Retinopathy
- Age related Macular Degeneration
- Strabismus
- Retinitis Pigmentosa
- Night blindness
- Amblyopia
- Central Serous Chorio-Retinopathy
- Optic Neuritis
- Optic Atrophy

EALE'S DISEASE

The eponym 'Eale's disease' is used to describe patients with nonspecific inflammation of the peripheral retinal veins. It is also known as periphlebitis and is characterized by recurrent vitreous hemorrhage.

Etiology : Not exactly known, but may be allergic or toxic in origin.

Clinical signs

- There is phlebitis of peripheral retinal veins, which appear thickened, tortuous and congested.
- There is sheathing of the affected veins.
- Retinal haemorrhages appear near the affected veins, if the haemorrhage is massive, it enters into the vitreous.

Symptoms

- Sudden appearance of floaters (black spots) in front of the eye.
- Painless loss of vision due to vitreous haemorrhage.

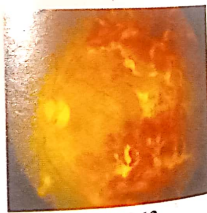


Fig. 8.13

Treatment

Absence of proper aetiology makes treatment of Eale's disease unsatisfactory. But still the following treatments are usually given.

- Medical- 1. Local and systemic corticosteroids 2. Anti-tubercular therapy
- Laser photocoagulation in the stage of neovascularisation
- Vitreo-retinal surgery

HYPERTENSIVE RETINOPATHY

Hypertension affects almost all the organs in the body directly or indirectly. In the eye, hypertension can affect the retinal and choroidal vessels directly. Hypertensive retinopathy may cause loss of vision due to macular haemorrhage, retinal oedema and hard exudates.

Pathogenesis

Vasoconstriction, arteriosclerosis and increased vascular permeability are the three main factors which play a major role in the pathogenesis of hypertensive retinopathies.

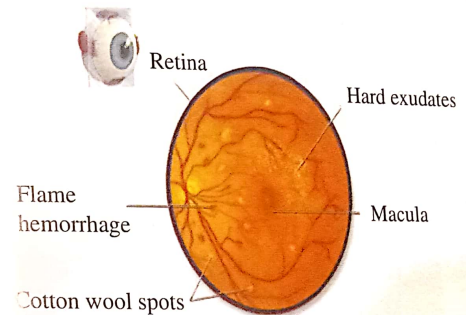


Fig. 8.14

Signs

- Arterial narrowing : may be focal or generalized.
- Cotton wool spots : in severe hypertension.
- Flame shaped retinal haemorrhages and retinal oedema.
- Swelling of the optic nerve head.
- Arteriosclerosis involves thickening of the vessel wall.

Treatment and management

Major aim is to prevent, limit or reverse target organ damage by lowering the patient's high blood pressure.

DIABETIC RETINOPATHY

Diabetic retinopathy remains the most common retinal condition that an ophthalmologist is likely to come across. The prevalence of diabetic retinopathy has been reported in several population based studies. It usually occurs 8-10 yrs after the onset of diabetes mellitus, controlled or uncontrolled.

Classification

Broadly diabetic retinopathy is divided into :

1. Non-proliferative diabetic retinopathy (NPDR)
2. Proliferative diabetic retinopathy (PDR)
3. Diabetic maculopathy
4. Advanced diabetic eye disease (ADED)

Non proliferative diabetic retinopathy (NPDR)

Ophthalmoscopic features of NPDR

1. Micro aneurysms in the macular area.
2. Retinal haemorrhages- both dot and blot haemorrhages, superficial haemorrhages (flame shaped).
3. Oedema characterized by retinal thickening.
4. Whitish yellow waxy looking hard exudates.
5. Cotton wool spots.

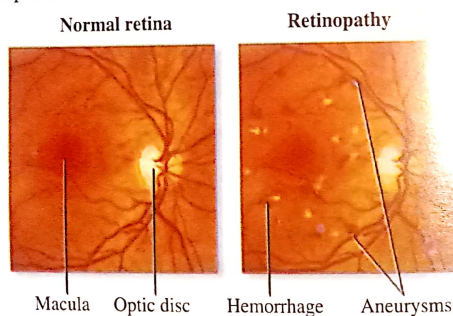


Fig. 8.15

Proliferative diabetic retinopathy (PDR)

- The hallmark of PDR is occurrence of neovascularization characterized by proliferation of new vessels from the capillaries at the optic disc or elsewhere in the fundus.
- Vitreous detachment and vitreous haemorrhage.



Fig. 8.16

Management

- Regular screening for diabetic retinopathy and controlling the systemic risk factors.
- Medical treatment such as:
 1. Anti Vascular Endothelial Growth Factors (Anti VEGF) drugs
 2. Protein kinase C (PKC) inhibitors
 3. Antioxidants such as vitamin E
 4. Intravitreal steroids to reduce macular oedema
- Photocoagulation (Laser)
- Surgical treatment in advanced cases of PDR.

AGE RELATED MACULAR DEGENERATION

Macula

Macula is an oval shaped highly pigmented yellow spot near the centre of retina. Histologically it has two or more layers of ganglion cells. Near its centre is the fovea having the largest concentration of cone cells which is responsible for central high resolution vision.

Age related macular degeneration (ARMD) is a degenerative disorder affecting the macula. It occurs in persons over 50 years of age. It is a bilateral disease and is a leading cause of blindness in developed countries.

Etiopathogenesis

Risk factors which may affect the age of onset and progression of the disease include age, race, heredity, hypertension, smoking, dietary factors such as high fat intake and other factors including cataract surgery, high exposure to sunlight, blue iris colour etc.

Clinical types

1. Dry (non exudative) ARMD
2. Wet (Exudative) ARMD

Dry (Non Exudative) Armd

It is responsible for 90% cases of ARMD.

Symptoms

- Mild to moderate gradual loss of vision.
- Distorted vision and difficulty in reading due to central shadowing.
- Vision is often better in bright light.

Signs

Ophthalmoscopically, occurrence of macular drusens, focal hyper pigmentation and pale areas of retinal pigment atrophy is noticed depending on their stages.

Wet (Exudative or Neovascular) ARMD

It is responsible for only 10% cases of ARMD but is associated with comparatively rapidly progressive marked loss of vision.

Signs

Lesions of exudative ARMD seen in the chronological disorder

- Drusens with retinal pigment epithelial detachment.
- Choroidal neovascularization.
- Hemorrhagic pigment epithelial detachment.
- Hemorrhagic detachment of neuro sensory retina.
- Disciform sub retinal scarring in the macular region.

Diagnosis is by

- Slit lamp examination

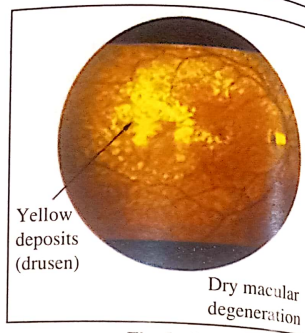


Fig. 8.17

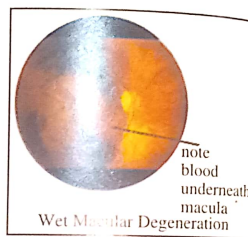


Fig. 8.18

- Fundus fluorescein angiography (FFA)
- Optical coherence tomography (OCT)

Management of Dry ARMD

- Prophylaxis: Antioxidant supplement, ocular sun protection measures, avoiding smoking etc.
- An amsler grid should be provided for self test on regular basis.
- Provision of low vision aids.
- Experimental surgeries such as miniature intra ocular telescope implantation and retinal translocation.
- Laser photocoagulation.

Management of Wet ARMD

- Intra vitreal anti VEGF (Vascular Endothelial Growth Factor) therapy.
- Photodynamic therapy (PDT).
- Trans pupillary thermotherapy (TTT).
- Photocoagulation.
- Surgical treatment- sub macular surgery and macular translocation surgery.

STRABISMUS

When both the eyes moves together keeping their visual axes parallel, the movements are known as conjugate movements. For each of these movements, two muscles take part-one muscle from each eye. These pair of muscles which work together are known as synergic muscles.

Type of conjugate movements		Synergic muscles involved
1. Dextro-version	Horizontally to right	Right lateral rectus and left medial rectus
2. Laevo-version	Horizontally to left	Left lateral rectus and right medial rectus
3. Dextro-elevation	Upwards and to right	Right superior rectus and left inferior oblique
4. Laevo-elevation	Upwards and to left	Left superior rectus and right inferior oblique
5. Dextro-depression	Downward and to right	Right inferior rectus and left superior oblique
6. Laevo-depression	Downward and to left	Left inferior rectus and right superior oblique

Strabismus is a condition in which the eyes are not properly aligned with each other. It typically involves a lack of coordination between the extra ocular muscles, which prevents bringing the gaze of each eye to the same point, thus hampering the proper binocular vision. In other words misalignment of the visual axes of the two eyes is called strabismus or squint.

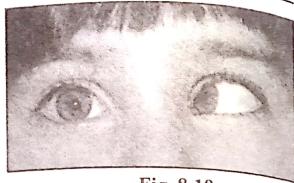


Fig. 8.19

Classification

1. Apparent squint or pseudo strabismus.
2. Heterophoria (Latent squint).
3. Heterotropia (Manifest squint).

Pseudo strabismus

In pseudo strabismus, the visual axes are in fact parallel, but the eyes seem to have a squint as in prominent epicanthal fold, where in normally visible nasal aspect of globe is covered giving a false impression of squint.

Heterophoria (Latent Squint)

It is a condition in which there is a tendency of non alignment of visual axes which is corrected or compensated by fusional reflex.

Symptoms

Headache or aching of eyes, blurring of print or jumbling together of words while reading and intermittent diplopia.

Diagnosis

By cover test: One eye is covered and other eye is made to fix on an object. If there is heterophoria, the eye under cover deviates. As soon as cover is removed the covered eye corrects the deviation, and regains its normal position quickly.

By Maddox rod test: By placing Maddox rod in different meridians heterophoria can be detected.

Other diagnostic tests: Include Maddox wing test, synoptophore, krimsky corneal reflex.

Treatment for Heterophoria

- a. Refractive error correction.
- b. Orthoptic treatment to increase fusional range and muscle power is done with synoptophore. (Synoptophore is an apparatus for diagnosis and treatment of strabismus).
- c. Surgical treatment- By this method, the weak muscle is strengthened or its antagonist is made weaker.

Heterotropia (Manifest Squint)

It is condition in which deviation of the eye remains constant (visual axes retain their abnormal relation to each other) in all directions of gaze.

They are of two types.

1. Concomitant strabismus
2. Incomitant strabismus

Concomitant Strabismus

It is a type of manifest squint in which the amount of deviation in the squinting eye remains constant (unaltered) in all the directions of gaze and there is no associated limitation of ocular movements.

Symptoms

Usually there is no symptom. The main feature of concomitant squint is the failure of binocular vision.

Investigations

- a. Cover test.
- b. Testing the movements of the eyeball.
- c. Recording visual acuity.
- d. Grading of binocular vision and measuring the angle of squint by synoptophore.

Treatment

- Correction of refractive error.

- Occlusion to cure amblyopia- The normal eye must be kept constantly occluded by a suitable occluder for 3 months.
- Surgical measures- By this the squinting eye is made straight.
- Fusion exercises- Indicated after surgery.

Incomitant strabismus

It is a type of heterotropia, in which deviation is caused by paralysis of extraocular muscles and is a condition in which the deviation of eye varies in different directions of gaze.

Symptoms

Diplopia, vertigo and nausea.

Investigation

- Ocular posture and head posture to know the deviation of eyeball.
- Cover test.
- Ocular movements test- To know the involved muscles.
- Diplopia test.
- Other methods include synoptophore examination, Hess screen test, Forced Duction Test (FDT) etc.

Treatment

- Treatment of the underlying cause.
- Occlusion of the affected eye to avoid diplopia.
- Injection of vitamin B₁, B₆, B₁₂.
- Surgical measure consist mainly of tackling the contracture of the direct antagonist and over action of the contra lateral synergist.

RETINITIS PIGMENTOSA

Bilateral progressive loss of vision beginning with night blindness and associated with bone corpuscular pigment deposits, narrowed arteries and optic atrophy characterize primary pigmentary retinal degeneration is referred to as retinitis pigmentosa (RP).

Etiology

The condition is inherited as a recessive trait with a 20% incidence of consanguinity of the parents. The severity of the disease varies with the site of mutation in the rhodopsin gene. Rhodopsin, a visual pigment found in the rods is responsible for night blindness.

There may be a large number of patients of RP with no family history of the disease. The exact etiology of RP is therefore unknown. It primarily affects rods and cones, particularly the former and the retinal pigment epithelium. The degeneration starts in the equatorial zone and slowly spreads both anteriorly and posteriorly.

Fundus picture

- Black pigment spots like bone corpuscles, along the blood vessels, mainly in the equatorial region.
- Yellow waxy appearance of the optic disc.
- Retinal arteries markedly narrow.



Fig. 8.20

Symptoms

- Night blindness.
- Later on dimness of vision.
- Tubular vision occurs in advanced cases.

Investigations

- Electro-retinogram (ERG).
- Electro-oculogram (EOG).
- Perimetry.

Treatment: Till date there is no effective treatment for the disease.

- Measures like vasodilators, placental extracts, transplantation of rectus muscles into supra choroidal space, ultrasonic therapy etc have been tried to stop the progression of the disease.
- Correction of refractive errors.
- Low vision aids such as magnifying glasses and night vision device.

4. Rehabilitation of the patient.
5. Counselling to be done to affected individuals not to undergo consanguineous marriage or produce children.

NIGHT BLINDNESS

It means poor vision in feeble illumination. It is mainly either due to the damage to the rods or deficient regeneration of visual purple. It can be detected by an instrument known as adaptometer.

Causes

- a. Congenital and hereditary conditions like high myopia, familial congenital night blindness and Oguchi's disease.
- b. Diseases of the eye like retinitis pigmentosa, peripheral chorio-retinitis, myopic degenerative changes in the periphery of the retina, chronic simple glaucoma, retinal detachment.
- c. Systemic diseases like vitamin-A deficiency, cirrhosis of liver.
- d. Conditions of the ocular media like paracentral lenticular and corneal opacities interfering with the light rays in dim light.

AMBLYOPIA

Amblyopia also called as "lazy eye" is a condition in which partial loss of vision occur in one or both the eyes. It involves decreased vision in an eye that otherwise appears normal. It may be either congenital or acquired. Acquired amblyopia may be organic (toxic) or functional.

In amblyopia, visual stimulation either fails to be or is poorly transmitted through the optic nerve to the brain for a continuous period of time.

Types

Depending upon the cause, amblyopia is of the following types:

- a. Strabismic amblyopia- Resulting from unilateral constant squint.
- b. Stimulus deprivation amblyopia- As in congenital or traumatic cataract, ptosis and central corneal opacity.
- c. Anisometropic amblyopia- Occurs in an eye having higher degree of refractive error than the fellow eye.

- d. Isometropic amblyopia- Is bilateral amblyopia occurring in children with uncorrected high refractive error.
- e. Meridional amblyopia- Occurs in children with uncorrected astigmatic refractive error.
- f. Toxic amblyopia: Due to the effect of exogenous or endogenous poisons such as tobacco, ethyl alcohol, methyl alcohol etc.

Clinical characteristics of an Amblyopic eye

- Visual acuity is reduced.
- Crowding phenomenon i.e. visual acuity is less when tested with multiple letter charts (Snellen's chart) than when tested with single charts (optotype).
- Fixation pattern may be central or eccentric.
- Color vision is usually normal, may be affected in deep amblyopia with vision below 6/36.

Treatment: (should be started as early as possible).

- Refractive error if any should be corrected.
- Occlusion therapy- Occlusion of the healthy eye allows the weaker eye to get stronger.
- Penalization: In this vision in the normal eye is blurred with atropine. It is best in the treatment of relatively mild amblyopia.

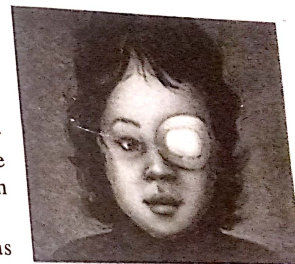


Fig. 8.21 (Occluding)

CENTRAL SEROUS CHORIO RETINOPATHY

It is an idiopathic disorder characterized by spontaneous serous detachment of neurosensory retina at the macula, with or without retinal pigment epithelium detachment.

Etiology

- Age and sex: Affects typically young adult (20-50 yrs), males more than females.
- Psychological stress.
- Steroid administration.

- Hypertension.
- Pregnancy (usually 3rd trimester).
- Systemic lupus erythematosus.

Symptoms

- Sudden painless loss of vision.
- Associated with relative positive scotoma.
- Micropsia and meta-morphopsia.

Signs : Ophthalmoscopic examination reveals:

- A round or oval detachment of sensory retina present at the macula.
- Foveal reflex is absent or distorted.
- Multi-focal pigmentary changes suggest chronicity.

Investigations

- Amsler grid.
- Fundus fluorescein angiography (FFA).
- Optical coherence tomography (OCT).

Treatment

- Observation and Reassurance.
- Laser photocoagulation.
- Photodynamic therapy (PDT).
- Intra vitreal anti VEGF agents (Vascular Endothelial Growth Factor).

OPTIC NEURITIS (Inflammation of the Optic nerve)

Optic neuritis is an inflammatory, infective or demyelinating process affecting the optic nerve.

This can be divided into :

1. Papillitis: When the optic nerve head is inflamed.
2. Retrobulbar neuritis: When the nerve behind the eyeball is affected.
3. Neuroretinitis: Combined involvement of optic disc and surrounding retina in the macular area.

Symptoms

- Visual loss: sudden, progressive and profound.
- Dark adaptation is reduced.
- Visual obscuration in bright light.
- Impairment of color vision.
- Episodic transient obscuration of vision on exertion and exposure to heat.
- Pain (marked in patients with retrobulbar neuritis).

Signs:

- Visual acuity: Reduced.
- Color vision : Severly impaired.
- Pupil shows ill-sustained constriction to light.
- Papillitis: Hyperaemia and oedema of the disc, blurring of margins, retinal veins are congested and tortuous.
- Retrobulbar neuritis: Fundus appears normal, occasionally temporal pallor of the disc may be seen.
- Visual field: Relative central or centrocaecal scotoma.
- Visually evoked response (VER): Shows reduced amplitude and delay in transmission time.

Treatment

- Treatment of the cause.
- Corticosteroid therapy.
- There is no effective treatment for idiopathic and hereditary optic neuritis associated with demyelinating disorders.

OPTIC ATROPHY

Optic atrophy refers to degeneration of the optic nerve. It occurs due to the damage caused to the axons at any point between their origin in the ganglion cells of the retina to their termination in lateral geniculate body.

Classification and Causes

- **Primary optic atrophy:** It is simple degeneration of nerve fibers without any complicating process within the eye. eg. Syphilitic optic atrophy.

Causes: Trauma to the optic nerve or chiasma or compression of these structures by tumor, demyelinating diseases, toxic conditions (toxic amblyopia) and malnutrititions (B₁ deficiency).

- **Secondary optic atrophy:** It occurs following any pathologic process which produces optic neuritis or papilloedema.
- **Consecutive atrophy:** It is sequel to the certain diseases of the retina. eg retinitis pigmentosa, occlusion of central retinal artery and glaucoma.

Symptoms

- Loss of vision may be sudden or gradual.
- Loss of visual field will vary depending on the damaged fibres.

Signs

- Pupil is semi dilated and direct light reflex is very sluggish or absent.
- Ophthalmoscopic features of optic atrophy in general are pallor of the disc and decrease in the number of small blood vessels.

Treatment

- Treat the underlying cause to preserve the remaining vision. However when complete atrophy sets in vision cannot be recovered.

Review Questions

1. Describe the signs and symptoms of Nakulāndhya?
2. Explain refractive errors and prescribe their optical corrections.
3. Describe Timira, Kācha and Lingānāsha in detail.
4. Describe Dhoomadarshi.
5. Write sādhyā asādhyā of Drishtigata rogas.
6. What is ARMD? Classify it and Write its clinical features.
7. Write the Patalagatha dosha lakshanas.
8. Write samānya chikitsa of Timira.
9. Write about optic neuritis and optic atrophy.
10. Shastra karma in Kaphaja Lingānāsha.
11. Yakrut pippali anjana yoga.
12. Write differential diagnosis of Pitta vidagdha, Amla vidagdha and Dhoomadarshi.
13. Sanimittajalinganāsa and Animittajalinganāsa.
14. Mention the difference between Kapha vidagdhadrusti and Pitta vidagdhadrusti.
15. Write in detail about Night blindness.

Research works

1. Comparative study on efficacy of Shigru pallva rasa anjana and Patolāgdi ghrita abhyantara in the management of Naktandya. Dr. Sharan. 2009, GAMC Bangalore, RGUHS-. Karnataka.
2. A comparative study on efficacy of Tarpana with Maha triphaladi ghrita and Haridradi varti anjana in the management of Progressive Myopia. Dr. Gayatri. 2009, GAMC Bangalore, RGUHS-Karnataka.
3. Management of Diabetic retinopathy with Doorvadya ghrita Tarpana and internal administration of Mahavasakadi kwatha. Dr. Veeranagouda Adoor. 2008 GAMC Bangalore. RGUHS. Karnataka.

Scope for Research

1. Role of Ghrita pana in preventing Drishtigata rogas or promoting vision.
2. Analyse Drushtigata rogas based on involvement of Dosha and Patala.

Chapter-9

MISCELLANEOUS DISEASE

- A. Xerophthalmia and other Malnutritional eye disorders
- B. Knowledge of Ocular trauma and their Management
- C. Introduction to Eye bank, Eye donation, Corneal Transplantation
- D. Preventive Ophthalmology and Community Ophthalmology

Chapter

9A

- Malnutrition
- Xerophthalmia and its Classification
- Other Malnutritional diseases of Eye
- Malnutritional Ocular diseases in Ayurveda

Malnutrition

Malnutrition or malnourishment is a condition that develops when the body does not get the right amount of vitamins, minerals and other nutrients it needs to maintain healthy tissue and organ functions. Among Malnutritional disorders of eye Xerophthalmia is the main.

XEROPHTHALMIA

The term Xerophthalmia refers to a spectrum of ocular diseases caused by vitamin A deficiency ranging from night blindness to severe corneal destruction.

Etiology

Xerophthalmia results either from inadequate supply of vitamin A or its defective absorption. It is usually seen in children below 5 years of age in low socio-economic strata of society.

Classification

For diagnostic and therapeutic purpose World Health Organization (WHO) has classified Xerophthalmia as :

Classification	Ocular Signs
XN	Night blindness
X1A	Conjunctival xerosis
X1B	Bitot's spots
X2	Corneal xerosis
X3	Corneal ulceration
	Less than 1/3 rd (X3A)
	More than 1/3 rd (X3B)
XS	Corneal scar
XF	Xerophthalmic fundus

Clinical features

(Changes are seen in the conjunctiva, cornea and fundus).

- **XN**– Night blindness is the earliest feature of xerophthalmia.
- **X1A**– Conjunctival xerosis is characterized by lustreless conjunctiva associated with wrinkling.
- **X1B**– Bitot's spot is a white, foamy lustreless triangular plaque situated on the bulbar conjunctiva. It is usually bilateral and situated temporally.
- **X2**– Corneal xerosis is characterized by lack of lustre in the cornea and decreased corneal sensitivity. Sometimes keratinized plaques may be seen on the cornea.
- **X3A, X3B**– Corneal ulceration/keratomalacia is a late stage of xerophthalmia.
- **XS**– Corneal scar is formed after healing of the ulcer. If the scar covers the pupillary area, vision is hampered.
- **XF**– Xerophthalmic fundus- Lesions appear as yellow discrete dots in the peripheral fundus.

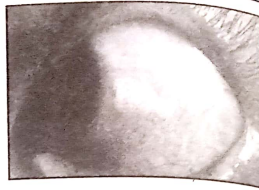


Fig. 9.1

Treatment

- In infants xerosis can be prevented by administering prophylactic vitamin A in mothers during pregnancy.
- Artificial tears (methyl cellulose) or lubricating eye drops should be used as local ocular therapy.
- Corneal ulcer should be treated accordingly.
- Generally the daily requirement of vitamin A for a child is 3000-4000 IU.
- Protein rich diet should be supplemented to facilitate absorption of vitamin A.
- In mild to moderate degrees of xerophthalmia, vitamin A rich dietary supplement such as green vegetables, carrot, egg, butter, fish, cod-liver oil gives satisfactory results.

WHO recommended vitamin A therapy for xerophthalmia.

Patients	Age	Dose	Schedule
Children	< 12 months	1,00,000 IU	1 st & 2 nd day. Repeat 2-4 weeks later.
Children	12 months or older	2,00,000 IU	1 st & 2 nd day. Repeat 2-4 weeks later.

Other Malnutritional Diseases of Eye

- **Vitamin B₁ (Thiamine) deficiency** : Causes external ophthalmoplegia, nystagmus, ptosis, retinal haemorrhages, conjunctival and corneal dystrophy and acute retrobulbar neuritis.
- **Vitamin B₂ (Riboflavin) deficiency** : Causes photophobia, conjunctival irritation, burning, angular blepharoconjunctivitis and peripheral corneal vascularization.
- **Vitamin B₃ (Niacin) deficiency** : Causes pellagra and optic neuropathy.
- **Vitamin B₆ (Pyridoxine) deficiency** : Causes optic neuritis and angular blepharoconjunctivitis.
- **Vitamin B₁₂ (Cobalamine) deficiency** : Causes optic neuropathy and nutritional amblyopia.
- **Vitamin C deficiency** : Causes haemorrhage in the lids, conjunctiva, anterior chamber, retina and orbit. It also delays wound healing.
- **Vitamin D deficiency** : Causes zonular cataract, papilloedema and increased lacrimation.

MALNUTRITIONAL OCULAR DISEASES IN AYURVEDA

Diseases of eye caused exclusively due to malnutrition are not described in our classics. But while mentioning the general cause of eye diseases, Acharya Sushruta includes various dietary factors such as kulattha, māsha and intake of alcoholic preparations like shukta and aranāla as causative factors responsible for ocular disorders.

Importance of nourishment to sense organs

प्रीणनं इन्द्रियाणां इति मात्रावतोलक्षणं आहारस्य भवति । (C.Vi.2/6)
इन्द्रियाणि समाश्रित्य प्रकुप्यन्ति यदा मलाः । उपघात उपतापाभ्यां योजयन्ति इन्द्रियाणि ते ॥ (C.Su.28/20)

Acharya Charaka tells that for nourishment of sense organs, proper quantity of food is necessary and intake of improper food will lead to formation of 'mala' (because of improper digestion). This mala intum accumulates in the indriyas to produce diseases.

According to Acharya Vagbhata

सर्वदा च निषेवेत स्वस्थोऽपि नयनप्रियः । पुराणं यव गोधूमं शालिं षष्टिकं कोद्वान् ।
मुद्गादीन् कफपित्तघ्नान् भूरिसर्पिः परिप्लुतान् । शाकं चैवंविधं मांसं जांगलं दाडिमं सिताम् ॥
सेच्यत्वं त्रिफलां द्राक्षां वारि पाने च नाथयम् । (A.H.U. 16/61-63)

The following ahāra should be consumed regularly to keep the eyes always healthy:

Puraña yava, godhuma (wheat), shāli, shastikashāli, kodrava, mudga, etc. Kapha pittahara ahara along with ghee, shāka (vegetables), jangalamamsa, dādima, sita, saindhava, triphala, draksha and jala (nabhasa).

Chapter

9B

- Ocular trauma- Classification and their Management
- Intra-Ocular and Extra-Ocular foreign bodies
- Blunt Trauma
- Chemical Burns
- Thermal Injuries
- Electrical Injuries
- Radiational Injuries
- Nayanābhigāta
 - Causes
 - General Line of Treatment in Ayurveda
 - Foreign body removal in Ayurveda
- Sādhyāsādhyata of Ocular Injuries

OCULAR TRAUMA

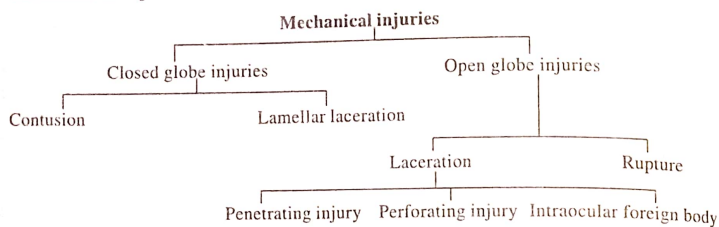
The eye is well protected by the bony orbit, the eye lids, eye lashes and their blink reflex. But inspite of these, injuries to the eyes are not uncommon. Ocular injury is the leading cause for mono-ocular blindness. Serious eye injuries involving the orbit or intra-ocular structures are usually classified into those caused by blunt objects, large sharp objects, small flying particles or burns. The type and extent of damage sustained by a traumatized eye depends on both the mechanism and force of the injury.

Classification of ocular trauma

Mechanical	Non Mechanical
<ul style="list-style-type: none"> • Blunt trauma • Penetrating injuries • Perforating injuries • Extra ocular foreign bodies 	<ul style="list-style-type: none"> • Chemical burns <ul style="list-style-type: none"> a) Acid burns b) Alkali burns • Thermal injuries

Mechanical	Non Mechanical
<ul style="list-style-type: none"> Intra ocular foreign bodies Sympathetic ophthalmitis 	<ul style="list-style-type: none"> Electrical injuries Radiational injuries <ul style="list-style-type: none"> a) UV radiations b) Infra red radiations c) Ionizing radiations

Mechanical injuries can be further classified as follows



Closed Globe Injury

In closed Globe injury, 'eye wall' (sclera and cornea) doesn't have a full thickness wound, but there is intraocular damage. It includes contusion and lamellar laceration.

- Contusion:** It is a result of blunt trauma. Injury may occur at the site of impact or at a distant site.
- Lamellar laceration:** It is caused by sharp object resulting in partial thickness wound in the bulbar conjunctiva or the eye wall.

Open Globe Injury

Open Globe injury refers to the full thickness injury of the eye wall i.e. cornea, sclera and the intraocular structures. It includes rupture and laceration of the eye wall.

- Rupture:** It refers to a full thickness wound of eye wall caused by the impact of blunt trauma. The eyeball ruptures at its weakest point by an inside out force.
- Laceration:** Full thickness wound of the eye wall, caused by a sharp object. It can either be a penetrating or perforating injury.

Penetrating injury

It is usually a single full thickness laceration of the eyeball. It has a site of entrance and doesn't have any exit wound. It is often caused by sharp objects such as metal, wood or stone.

Perforating injury

It has both an entrance and exit wounds caused by sharp objects.

Intra ocular foreign body injury

It is a penetrating injury in which intra ocular foreign body is retained causing lacerations at the entrance. Foreign bodies which are commonly responsible for such injuries include chips of iron, steel, stone, plastics and wood. It may damage the ocular structures by its mechanical effects, introduction of infection and reaction of foreign bodies.

Diagnosis

- Slit lamp examination including gonioscopy.
- Plain X-ray as most foreign bodies are radio opaque.
- CT and MRI scan.

Treatment: Special surgical or non surgical techniques should be employed to remove the foreign body depending on its site in the anterior chamber, iris tissue, lens, vitreous or retina.

Extra ocular foreign body injury

Injury due to extra ocular foreign bodies are quite common. Foreign bodies such as small particles of dust, wood, stone, husk of paddy, wings of insects may hit upon the surface of the eye ball and may be retained either in the conjunctiva or on the cornea. Minute foreign bodies are generally washed away by tear flow. Retained foreign body produces immediate discomfort, irritation, profuse watering and reflex blinking. Pain, photophobia and defect in vision are noticed when foreign body is embedded in the cornea. Eversion of upper lid is required to discover foreign body present in the superior fornix and slit lamp examination reveals corneal foreign body.

Treatment: Foreign bodies such as particles of dust or coal can be removed with the help of cotton swab after surface anaesthesia. The embedded foreign body on the cornea can be removed with the help of hypodermic needle.

Blunt trauma

Blunt trauma or non perforating injuries of the eye are caused by blunt objects such as a direct blow to the eye by fist, tennis or cricket ball. The eye can also be traumatized in road accidents, fall and sports. When the eye is struck, it is compressed antero-posteriorly and correspondingly stretched in the equatorial plane. The injury may cause displacement, rupture and tear of the intraocular structures with or without rupture of the globe. It may cause serious diminution of vision or may often have a delayed effect.

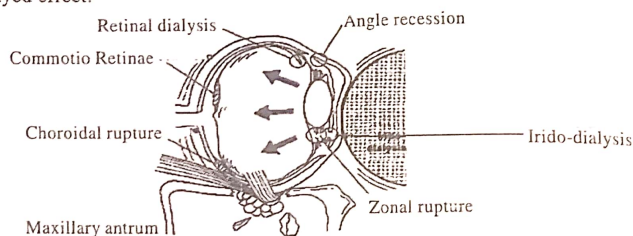


Fig. 9.2

CHEMICAL BURNS

Acid and alkali burns in the eye are commonly caused by detergents, disinfectants, fertilizers, pesticides etc. but serious eye injuries occur in industries where strong acids and alkalis are often used. The outcome of any chemical burn depends on the concentration and pH of the offending agent and duration of exposure. It is one amongst the most urgent of ophthalmic emergencies.

(a) Alkali burns

Alkali burns are more severe than acid burns because they damage cells and penetrate the tissues rapidly. Common alkalis responsible for burns are lime, caustic potash or caustic soda and liquid ammonia. Acute ischemic necrosis of conjunctiva, cornea and iris occurs leading to symblepharon, recurrent corneal ulceration, complicated cataract and secondary glaucoma in later stages.

(b) Acid burns

Acid injuries tend to be less severe, as they remain confined to the ocular surface and doesn't penetrate deeper. Common acids responsible for burns are sulphuric acid, hydrochloric acid and nitric acid. Mild burns result in loss of the corneal and

conjunctival epithelium. Strong acids cause instant coagulation of all the proteins which then act as a barrier and prevent deeper penetration of the acids into the tissue. However, severe acid burn can incite a marked inflammation that can damage the corneal matrix.

Medical management

- Ocular irrigation with normal saline or Balanced Salt Solution (BSS).
- Double evert the lid and remove any remaining chemical from ocular surface with a swabstick and forceps.
- Intensive topical administration of corticosteroids.
- A broad spectrum topical antibiotics and frequent lubrication with preservative free eye drops.
- High doses of ascorbic acid to promote wound healing.
- Therapeutic soft contact lenses helps in epithelial healing and prevention of corneal melting.

THERMAL INJURIES

Thermal burns may be caused due to boiling water, cigarette lighters, molten metals, hot ashes etc. Eyelids are often involved in thermal burns because of the eye closing reflex. The heat induces coagulation of the conjunctival and corneal surface. Watering, blepharospasm, visual impairment and pain are the primary symptoms. Subsequently cornea may become opaque.

Treatment

- Application of cycloplegic agent relieves pain.
- Local and systemic antibiotics prevent infection.

ELECTRICAL INJURIES

A strong electrical shock can damage the eye causing corneal opacities, uveitis, cataract and retinal haemorrhages.

RADIATIONAL INJURIES

1. **Ultra violet radiations** like exposure to welding, direct exposure to sunlight causes superficial corneal ulceration resulting in ocular discomfort and pain.

Treatment consists of topical cycloplegic antibiotic ointment and patching. Use of protective glasses prevents further damage.

- b. **Infrared rays** of sunlight are absorbed by ocular pigment epithelium causing photoretinitis (solar retinopathy).
- c. **Ionizing radiation** given to patients in neoplasms causes direct damage to the tissue or blood vessels resulting in ischemic necrosis. This type of radiation also leads to loss of eye lashes, blepharitis, dry eye syndrome, cataract and radiation retinopathies. The prophylaxis include protection of the eye before exposing to radiation. Frequent instillation of tear substitutes, use of bandage, contact lens are helpful. Radiation cataract is managed by surgery.

Sympathetic Ophthalmitis

It is a bilateral granulomatous inflammatory response from injury to one eye (exciting eye) followed by the development of symptoms in the uninjured eye (sympathizing eye). Its incidence has significantly reduced due to improved technique of wound repair and prompt use of corticosteroids.

Chapter

9C

- Eye Bank
- Facts about Eye donation
- Corneal Transplantation

EYE BANK

VP Filatov is considered as the father of modern Eye Banking. He showed that cadaver tissue stored at 4°C could be used as donor material. This ultimately led to the establishment of eye banks for the collection and storage of tissue. The first Eye Bank was set up in New York in 1959 and Eye Bank Association of America was founded in 1961. This organization laid down the standards for obtaining, preservation, storage and usage of donor tissue.

An Eye Bank is a non-profit organization with an aim to acquire and provide donated human eye tissue for corneal transplantation. It also provides the tissue for research and education. The eye bank also holds the responsibilities of insuring the safety and efficacy of donor corneas. Eye banks provide tissue for :

1. Cornea transplant.
2. Treating conditions such as keratoconus.
3. Corneal scarring.

Collection of the tissue

When an organ/tissue donor dies, consent for donation is obtained either from donor registry or from donor's next kin. The entire eye called the 'globe' may be surgically removed (enucleated) or only the cornea may be excised in situ and placed in storage media. There is a wide variety of storage media used in eye banking. Commercial preparations as well as organ culture medium can preserve corneas. The eye tissue is then transported to eye bank for processing.

Medical standards in Eye banking

The medical standards and regulations are intended to assure the high possible standards of safety and efficacy for donor cornea. In order to improve the safety of eye banking regular reviews and improvements in the standards and certification of eye banks and eye bank's personnel is essential. The medical standards broadly include medical directors and their qualifications, eye bank technicians their qualifications and training, laboratory facilities, acceptability of donor tissue, record keeping of donor tissue, enucleation procedures, inspection of donor tissue and lastly certification and recertification of eye banks and eye bank technicians.

Eye bank personnel include

1. **Eye bank in charge-** should be a qualified ophthalmologist to evaluate, process and distribute the donor tissue.
2. **Eye bank technician-** the duties of trained eye bank technicians are:
 - To keep the eye collection kits ready.
 - To assist in enucleation of donor eyes.
 - To record data pertaining to donor material and waiting list of patients.
 - To assist in corneal preservation and storage.
3. **Clerk cum store keeper-** the duties are :
 - To maintain meticulous records.
 - To coordinate with other eye banks.
 - To distribute cornea to eye surgeons/eye banks.
4. **Medical social worker or public relation officer is required:**
 - To supply publicity material to common public.
 - To promote voluntary eye donation.
5. **Driver cum projectionist is required:**
 - To maintain vehicle of the eye bank
 - To screen films of eye donation promotion in the community.

Facts about Eye Donation

- The eyes have to be removed within 6 hours of death. So the nearest Eye Bank or eye collection centre must be informed immediately irrespective of the initial pledging of eye donation.
- Eye removal takes only 10-15 minutes and leaves no scar or disfigurement of the face.
- Only the cornea is transplanted for all practical purpose and not the entire eyeball. However, other part of eye is used for research and education purpose.
- Eye donation gives sight to two persons as one blind person is transplanted with one eye.
- The donated corneas are transplanted to patients eye who are in waiting list in accordance with the priority based on guidelines to avoid malpractices.
- The eyes cannot be removed from a living human being in spite of his/her consent.

- The eyes are never bought or sold.
- Eye donation is never refused.

CORNEAL TRANSPLANTATION

Corneal transplantation, also known as Corneal grafting, is a surgical procedure where a damaged or diseased cornea is replaced by donated corneal tissue (the graft).

Keratoplasty

Means surgery to cornea. When the entire cornea is replaced it is known as Penetrating Keratoplasty and when only part of cornea is replaced it is known as lamellar Keratoplasty. The graft is taken from a recently dead individual.

Indications:

Corneal grafting is usually done to improve visual acuity by replacing the opaque or distorted host tissue by clear healthy donor tissue. Commonly it is indicated in the following conditions.

- Thinning of cornea.
- Corneal infection and perforation.
- Corneal ulcers.
- Swelling of cornea.
- Cloudy cornea.

Procedure

The donor cornea can be obtained from an eye bank. The operation can be performed either under local or general anesthesia. The size of the graft is determined. The grafts smaller than 6mm are inadequate while grafts larger than 8.5mm are prone for complications. The surgery is performed under following steps:

- The corneal button is cut, using a trephine, from a donor corneoscleral ring.
- The host diseased cornea is trephined and the opaque button removed with scissors.
- The donor corneal button is sutured to the host cornea.

Prognosis

The results of corneal transplant is very gratifying in restoring vision if cornea is not vascularized and insensitive.

Chapter

9D

- Definition and causes of Blindness
- National programme for control of Blindness in India
- Vision-2020

PREVENTIVE AND COMMUNITY OPHTHALMOLOGY

Community ophthalmology is defined as a discipline of medicine which utilizes the methodologies of public health, community medicine and clinical ophthalmology to protect or promote ocular health and prevent blindness.

Community ophthalmology is foreseen as a health management approach in preventing eye diseases, lowering eye morbidity rates and promoting eye health through active community participation at ground level. This branch of medicine also seeks to address the problem of preventable or avoidable blindness.

Community ophthalmology also requires to investigate the magnitude of the problem, the cause of blindness and the eye diseases in the community, the availability of eye services and the attitude of the community towards the services. It strives to instill community awareness on eye health through various strategies and provides comprehensive eye care services like vitamin-A supplementation, vision screening in schools, community based rehabilitation, primary eye care as well as training of primary eye care workers.

Definition of Blindness according to WHO

A person having visual acuity of less than 6/60 or 2/200 with correcting glasses in the better eye in day light is defined as blind. A concentric contraction of visual field to an average radius of 10 degrees is considered equally disabling.

Blindness is a global public health problem and adversely affects the productivity of population. The high prevalence of blindness is more evident in developing countries because of the poor access to eye care facilities. The world health organization's programme for prevention of blindness was initiated in 1978.

Causes of Blindness

The WHO has listed six major causes of blindness, they are Cataract, Glaucoma, Diabetic retinopathy, Trachoma, Vitamin-A deficiency and Onchocerciasis.

The causes of blindness in developed countries are quite different from that in developing or underdeveloped nations. In the developed countries, glaucoma, myopia, developmental ocular anomalies, macular degeneration, diabetic retinopathy and cataract are the major causes of blindness while cataract, infectious diseases of the eye (trachoma and allied conditions), malnutrition, ocular injuries and glaucoma are common causes in the developing or underdeveloped countries.

National Programme for Control of Blindness in India

Government of India launched the National Programme for Control of Blindness (NPCB) in the year 1976 with the intention of reducing the prevalence of blindness. A three tier health care system has been adopted for the delivery of eye care services in the country as 70 percent of Indian population lies in the rural areas.

1. **Primary eye care:** The facilities of primary health care have to be provided at every primary health centre and subcentre. The paramedical ophthalmic assistant carries out refractive evaluation, identifies and motivates cataract patients for surgery. They also conduct eye screening camps, provides primary treatment and refers them to ophthalmologist for further evaluation and management.
2. **Secondary eye care:** Basic ophthalmic equipments and trained medical staff and ophthalmologists are present in District hospitals. The staff actively participate in eye screening and surgery.
3. **Tertiary eye care:** Services of tertiary eye care are available in the Ophthalmology department in all medical colleges, regional and private institutions. These institutions, not only give specialized eye care but also train ophthalmic surgeons and paramedics to work in district and subdivisional hospitals.

The Present Objective of NPCB Include

- Reduction in the backlog of blindness through identification and treatment of blind.
- Development of comprehensive eye care facilities in every district.
- Development of human resources for providing eye care facilities.
- Improvement in quality of service delivery.

- Securing participation of voluntary organizations and private practitioners in eye care.
- Enhancement in community awareness on eye care.
- Setting up of mechanism for referral, coordination and feedback between organizations dedicated to prevention, treatment and rehabilitation.

Vision 2020

The WHO and IAPB (International Agency for Prevention of Blindness) in the year 1999 have jointly launched Vision 2020 – Right to Sight.

The main objective of Vision 2020 is to eradicate the avoidable blindness by 2020 in order to give all people needlessly going blind, the Right to Sight.

Vision 2020 in India

The vision 2020 programme in India have primarily targeted seven ocular diseases.

- | | |
|--------------------------------------|--------------------------|
| 1. Cataract. | 5. Diabetic retinopathy. |
| 2. Childhood blindness. | 6. Glaucoma and |
| 3. Refractive errors and low vision. | 7. Trachoma. |
| 4. Corneal blindness. | |

Proposed structure for vision 2020 : The right to sight

I. Primary

Vision centers must be 20,000 in number. The following programmes are included in this study.

- Refraction and prescription of glasses.
- Primary eye care.
- School eye screening programme.
- Screening and referral services.

II. Secondary

Service centres must be 2000 in number. It includes:

- | | |
|------------------------------|-------------------------------|
| • Cataract surgery. | • Other common eye surgeries. |
| • Facilities for refraction. | • Referral services. |

III. Tertiary

A. Training centres- 200 in number.

Tertiary eye care including-

- Retinal surgery, corneal transplantation, glaucoma surgery etc.
 - Training and organisation of CME programmes.
- B. Centres of excellence- 20 in number.
- Professional leadership.
 - Strategy development.
 - Continued medical education.
 - Laying of standards and quality assurance.
 - Research.

Chapter-10

YANTRAS AND SHASTRAS

Chapter

10

- Definition of Yantra
- Materials used for making Yantra
- Functions of Yantra
- Classification and uses of Yantra
- Shastras- Classification and uses

YANTRAS AND SHASTRAS

Introduction

Instruments are the integral part of surgical discipline. The sound knowledge of instruments is essential for performing surgery. The dimensions and shape of the instruments help to understand the mechanics of the instruments and its precise use.

YANTRA

Definition

आहर्तुमभ्युपायो यस्तद्व्यन्त्रं यच्च दशनि । (अ.ह.सू. २५/१)

Yantras are blunt instruments used for examination, diagnosis & removal of foreign body.

Materials used for making Yantra

Ideally, yantra should be made up of metals like gold, silver, bronze and iron. In the event of non availability of metals, substance having similar properties can be employed like horn, teeth, threads, stones etc.

Functions of Yantra

यन्त्रकर्मणि तु-

निर्घातिनपूरणवन्धनव्यूहनवर्तनचालनविवर्तनविवरणपीडनमार्गविशोधनविकर्षणाहरणाञ्जनोन्नमनविनमनभञ्जनोन्मथना-
चूषणौषणदारणार्जुकरणप्रक्षालन प्रघमनप्रमार्जनानि चतुर्विंशतिः ।। (सु.सू. ७/२७)

Nirghatana- Hammering Poorana- Filling

Bandhana- Bandaging

Vyuhana- Reconstruction	Vartana- Replacement	Chalana- Moving/loosening
Aharana- Extraction	Anchana- Traction	Unnamana- Elevation
Vinamana- Depression	Bhanjana- Crushing	Achūshāna- Suction
Eshana- Probing	Darana- To split	Rujukarana- Straightening
Prakshalana- Cleaning	Pradhamana- Insufflation	Pramarjana- Sweep out
Vivartana- Extraction by Unwinding	Vivarana- Dilatation of a passage	
Pidana- Pressure to evacuate a cavity.		
Marga Visodhana- Dousche/Irrigation (to clean up).		
Vikarsana- Forceful Extraction.		

Classification of Yantra

The yantras are classified into 6 categories:

1. Swasthika
2. Sandhamsha
3. Taala
4. Naadi
5. Shalāka
6. Upa

(1) Swastika Yantra

Instruments whose limbs crosses each other and goes in opposite directions is known as Swastika Yantra.

Uses

To remove foreign body which are deep seated or from the bone.



Makara mukhi swastika yantra

(2) Sandamsha Yantra

It consists of two limbs with their tips meet like the tips of the thumb and forefinger and the other ends are fixed.



Pakshi mukhi (Cheatle forceps)

Uses

These yantras are used to locate, grip and extract small shalyas embedded in soft tissues like skin, fascia and muscle in where precision is more important than strong grip and force.

(3) Taala Yantra

Yantra which is having functional part resembling as that of Scales of fish.



Uses

The taala yantras are used to scoop out shalyas present in the orifices which communicate with outside atmosphere like karna and nasa, and also in sinuses.



Eka-Taala



Dvi-Taala

(4) Naadi Yantra

Instruments with lumen are called Naadi Yantra.

नाडीवन्मध्यशुषिराणि नाडीयन्त्राणि' इति चक्रः । (सु.सू. ७/१३ पाठ)

Uses

Localization and removal of foreign body from orifices, suction of fluids like vitiated rakta, facilitating variety of therapies like Agnikarma, Ksharakarma etc.



Kantiya Shalyāvalokini



Panchamukha Chidra

(5) Shalākā Yantra

Now a days many type of retractors come, with different shapes, sizes and modified ends to retract different part of the body. It is also used as applicator. Eg. application of anjana.

**(6) Upa Yantra**

Instruments which does the function of yantra, but are not as efficient as Yantra, are known as Upayantra.

Upayantra are listed below:

Rajju, Venika, Patta, Charmānta, Valkala, Latā, Vastra, Ashteelashma, Mudgāra, Pāni- pāda tala, Anguli, Jihwa, Danta, Nakha, Mukha, Bāla, Ashwakataka, Shākha, Shteevana, Pravahana, Harsha, Ayaskānta, Kshāra, Agni, Bheshaja.

Uses

Can be used in any procedure in any part of the body, based on convenience.

SHASTRAS

	Diagram	Uses
1. Mandalāgra		Chedana, lekhana
2. Karapatra		Chedana, lekhana
3. Vriddhipatra		Chedana, bhedana
4. Nakhashastra		Chedana, bhedana
5. Mudrika		Chedana, bhedana
6. Utpālapatra		Chedana, bhedana
7. Ardhadhāra		Chedana, bhedana
8. Suchi		Visravana, Seevana, Vyadhana

9. Kushapatra		Visrāvana
10. Ātimukha		Visrāvana
11. Sharārimukha		Visrāvana
12. Antarmukha		Visrāvana
13. Trikurchaka		Visrāvana
14. Kutharika		Vyadhana
15. Vrīhimukha		Vyadhana
16. Āra		Vyadhana
17. Vétasapatra		Vyadhana
18. Badisha		Āharana
19. Dantashankhu		Āharana
20. Eshani		Eshana, Anulomana